



10022

Nonunions: Evaluation and Treatment

Mark R. Brinker, M.D. and Daniel P. O'Connor, Ph.D.

s0010 INTRODUCTION

p0010 While fracture nonunions may represent a small percentage of the traumatologist's case load, they can account for a high percentage of a surgeon's stress, anxiety, and frustration. Arrival of a fracture nonunion may be anticipated following a severe traumatic injury, such as an open fracture with segmental bone loss, but may also appear following a low-energy fracture that seemed destined to heal.

p0020 Fracture nonunion is a chronic medical condition associated with pain and functional and psychosocial disability.¹⁸⁰ Because of the wide variation in patient responses to various stresses¹⁷⁷ and the impact that may have on the patient's family (relationships, income, etc.), these cases are often difficult to manage.

p0030 Some 90 to 95 percent of all fractures heal without problems.^{87,245} Nonunions are that small percentage of cases in which the biological process of fracture repair cannot overcome the local biology and mechanics of the bony injury.

s0020 DEFINITIONS

p0040 A fracture is said to have "gone on to nonunion" when the normal biologic healing processes cease to the extent that solid healing will not occur without further treatment intervention. The definition is subjective, with criteria that result in high interobserver variability.

p0050 The literature reveals a myriad of definitions of nonunion. For the purposes of clinical investigations, the U.S. Food and Drug Administration (FDA) defines a nonunion as a fracture that is at least 9 months old and has not shown any signs of healing for 3 consecutive months.^{125,307} Müller's²⁰⁹ definition is failure of a (tibia) fracture to unite after 8 months of nonoperative treatment. These two definitions are widely utilized, but their arbitrary use of a temporal limit is flawed.¹¹³ For example, several months of observation should not be required to declare a tibial shaft fracture with 10 cm of segmental bone loss a nonunion. Conversely, how does one define a fracture that continues to consolidate but requires 12 months to heal?²⁶⁴

p0060 We define nonunion as a fracture that, in the opinion of the treating physician, has no possibility of healing without further intervention. We define delayed union as

a fracture that, in the opinion of the treating physician, shows slower progression to healing than anticipated and is at risk of nonunion without further intervention.

To understand the biological processes and clinical implications of fracture nonunion, an understanding of the normal fracture healing process is required. The following section reviews the local biology of fracture healing, requirements for fracture union, and types of normal fracture repair. p0070

FRACTURE REPAIR

Fracture repair is an astonishing process that involves spontaneous, structured regeneration of bony tissue and restores mechanical stability. The process begins at the moment of bony injury, initiating a proliferation of tissues that ultimately leads to healing. p0080

The early biological response at the fracture site is an inflammatory response with bleeding and the formation of a fracture hematoma. The repair response occurs rapidly in the presence of osteoprogenitor cells from the periosteum and endosteum and hematopoietic cells that are capable of secreting growth factors. Following fracture healing, bony remodeling progresses according to Wolff's law.^{20,21,238,272,328} p0090

The repair process, involving both intramembranous and enchondral bone formation, requires mechanical stability, an adequate blood supply, good bony contact, and the appropriate endocrine and metabolic responses. The biological response is related to the type and extent of injury and the type of treatment (Table 22-1). p0100

Healing via Callus

In the absence of rigid fixation (e.g., cast immobilization), stabilization of bony fragments occurs by periosteal and endosteal callus formation. If the fracture site has an adequate blood supply, callus formation proceeds and results in an increase in the cross-sectional area at the fracture surface. This increased cross-sectional area enhances fracture stability. Fracture stability is also provided by the formation of fibrocartilage, which replaces granulation tissue at the fracture site. Enchondral bone formation, in which bone replaces cartilage, occurs only after calcification of the fibrocartilage. p0110

Table 22-1

Type of Fracture Healing Based on Type of Stabilization

Type of Stabilization	Predominant Type of Healing
Cast (closed treatment)	Periosteal bridging callus and interfragmentary enchondral ossification
Compression plate	Primary cortical healing (cutting cone-type remodeling)
Intramedullary nail	Early: periosteal bridging callus Late: medullary callus
External fixator	Depends on extent of rigidity Less rigid: periosteal bridging callus More rigid: primary cortical healing
Inadequate immobilization	
With adequate blood supply	Hypertrophic nonunion (failed enchondral ossification)
Without adequate blood supply	Atrophic nonunion
Inadequate reduction with displacement at the fracture site	Oligotrophic nonunion

s0050 **Direct Bone (Osteonal) Healing**

p0120 Direct osteonal healing occurs without formation of external callus and is characterized by gradual disappearance of the fracture line. This process requires an adequate blood supply and absolute rigidity at the fracture site, most commonly accomplished via compression plating. In areas of direct bone-to-bone contact, fracture repair resembles cutting-cone type remodeling. In areas where small gaps exist between fracture fragments, “gap healing” occurs via appositional bone formation.

s0060 **Indirect Bone Healing**

p0130 Indirect bone healing occurs in fractures that have been stabilized with less than absolute rigidity, including intramedullary nail fixation, tension band wire techniques, cerclage wiring, external fixation, and plate-and-screw fixation (applied suboptimally). Indirect healing involves coupled bone resorption and bone formation at the fracture site. Healing occurs via a combination of external callus formation and enchondral ossification.

s0070 **ETIOLOGY OF NONUNIONS**

s0080 **Predisposing Factors—Instability, Inadequate Vascularity, Poor Contact**

p0140 The most basic requirements for fracture healing include (1) mechanical stability, (2) an adequate blood supply (i.e., bone vascularity), and (3) bone-to-bone contact. The absence of one or more of these factors predisposes the fracture to the development of a nonunion. The factors may be negatively affected by the severity of the injury, suboptimal surgical fixation resulting from either a poor plan or a good plan carried out poorly, or a combination of injury severity and suboptimal surgical fixation.

INSTABILITY

s0090

p0150 Mechanical instability, excessive motion at the fracture site, can follow internal or external fixation. Factors producing mechanical instability include inadequate fixation (implants too small or too few), distraction of the fracture surfaces (hardware is as capable of holding bone apart as holding bone together), bone loss, and poor bone quality (i.e., poor purchase) (Fig. 22-1). If an adequate blood supply exists, excessive motion at the fracture site results in abundant callus formation, widening of the fracture line, failure of fibrocartilage to mineralize, and ultimately failure to unite.

INADEQUATE VASCULARITY

s0100

p0160 Loss of blood supply to the fracture surfaces may arise because of the severity of the injury or because of surgical dissection. Several studies have shown a relationship between the extent of soft tissue injury and the rate of fracture nonunion.^{50,62,124} Open fractures and high-energy closed injuries may strip soft tissues, damage the periosteal blood supply, and disrupt the nutrient vessels, impairing the endosteal blood supply.

p0170 Injury of certain vessels, such as the posterior tibial artery, may also increase risk of nonunion.³⁴ Vascularity may also be compromised by excess stripping of the periosteum as well as damage to bone and the soft tissues during open reduction and hardware insertion. Whatever the cause, inadequate vascularity results in necrotic bone at the ends of the fracture fragments. These necrotic surfaces inhibit fracture healing and often result in fracture nonunion.

POOR BONE CONTACT

s0110

p0180 Poor bone-to-bone contact at the fracture site may result from soft tissue interposition, malposition or malalignment of the fracture fragments, bone loss, and distraction of the fracture fragments (see Fig. 22-1). Whatever the cause, poor bone-to-bone contact compromises mechanical stability and creates a defect. The probability of fracture union decreases as defects increase in size. The threshold value for rapid bridging of cortical defects via direct osteonal healing, the so-called osteoblastic jumping distance, is approximately 1 mm in rabbits²⁹¹ but varies from species to species. Larger cortical defects may also heal, but at a much slower rate and bridge via woven bone. The “critical defect” represents the distance between fracture surfaces that will not be bridged by bone without intervention. The critical defect size depends on a variety of injury-related factors and varies considerably among species.

Other Contributing Factors

s0120

p0190 In addition to mechanical instability, inadequate vascularity, and poor bone contact, other factors may contribute to development of nonunion (Table 22-2). These factors, however, are not direct causes of nonunion per se.

INFECTON

s0130

p0200 Infection in the zone of fracture increases the risk of nonunion.¹²⁴ Infection of the bone or the surrounding soft tissues can create the same local environment that predisposes noninfected fractures to fail to unite. Infection may result in instability at the fracture site as implants loosen in infected bone. Avascular, necrotic bone at the fracture

site (sequestrum), common with infection, discourages bony union. Infection also produces poor bony contact as osteolysis at the fracture site results from ingrowth of infected granulation tissue.

AUT s0140 **NICOTINE**

p0210 Cigarette smoking adversely affects fracture healing. Nicotine inhibits vascular ingrowth and early revascularization of bone^{65,256} and diminishes osteoblast function.^{76,96,248} In rabbit models, cigarette smoking and nicotine impair bone healing in fractures,²⁴⁷ in spinal fusion,^{298,337} and during tibial lengthening.^{315,316}

p0220 Delayed fracture healing and higher nonunion rates have been reported in patients who smoke. In 146 closed and type I open tibial shaft fractures, Schmitz et al.²⁹³ reported a significant delay of fracture healing in smokers. Similarly, Kyrö et al.¹⁷¹ and Adams et al.⁴ reported higher rates of delayed union and nonunion in smokers with tibia fractures. Hak et al.¹²² reported a markedly higher rate of persistent femoral nonunion in smokers. Cobb et al.⁵⁸ reported an extremely high risk of nonunion of ankle arthrodesis in smokers. Cigarette smoking is also associated

with osteoporosis and generalized bone loss,²⁴⁴ so mechanical instability due to poor bone quality for purchase may play a role.

CERTAIN MEDICATIONS

s0150

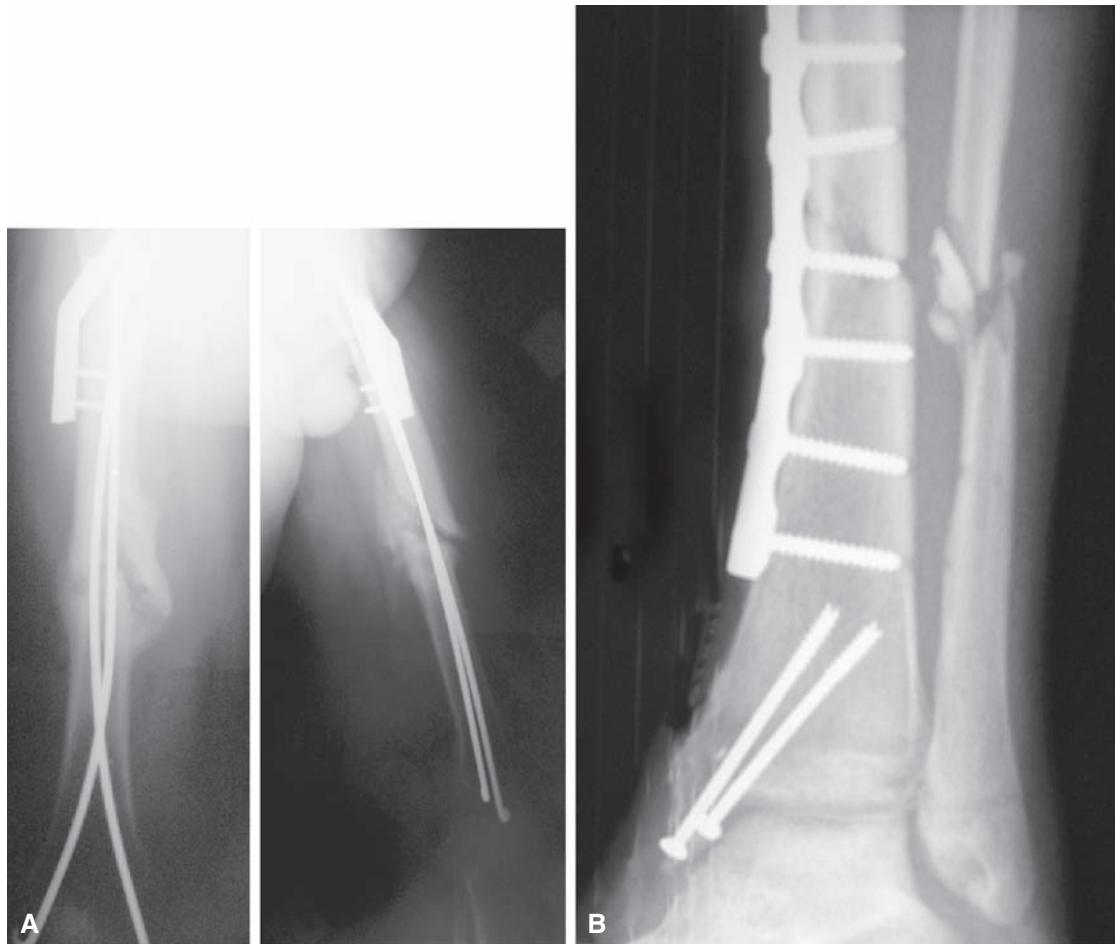Some animal studies have shown that nonsteroidal anti-inflammatory drugs (NSAIDs) negatively affect the healing of experimentally induced fractures and osteotomies.^{8,9,38,92,134,157,181,265,305} Other animal studies have reported no significant effect.^{138,204}

p0230

Delayed long-bone fracture healing has been documented in humans taking oral NSAIDs.^{39,110,161} Giannoudis et al.¹¹⁰ reported a marked association between NSAID use and delayed fracture healing and nonunion in fractures of the femoral diaphysis. Butcher and Marsh³⁹ reported similar findings for tibia fractures, as did Khan¹⁶¹ for clavicle fractures. While a body of literature suggests that NSAIDs are a factor in delayed fracture healing, no consensus exists. Furthermore, the mechanism of action (direct action at the fracture site vs. indirect hormonal actions) remains obscure. Finally, whether all NSAIDs display similar effects and the dose-response characteristics

p0240

f0010 **FIGURE 22-1** Mechanical instability at the fracture site can lead to nonunion. Mechanical instability can be caused by the following. **A, Inadequate fixation.** A 33-year-old man had a femoral shaft nonunion 8 months following inadequate fixation with flexible intramedullary nails. **B, Distraction.** A 19-year-old man with a tibia fracture treated with plate and screw fixation; this patient is at risk for nonunion because of distraction at the fracture site.

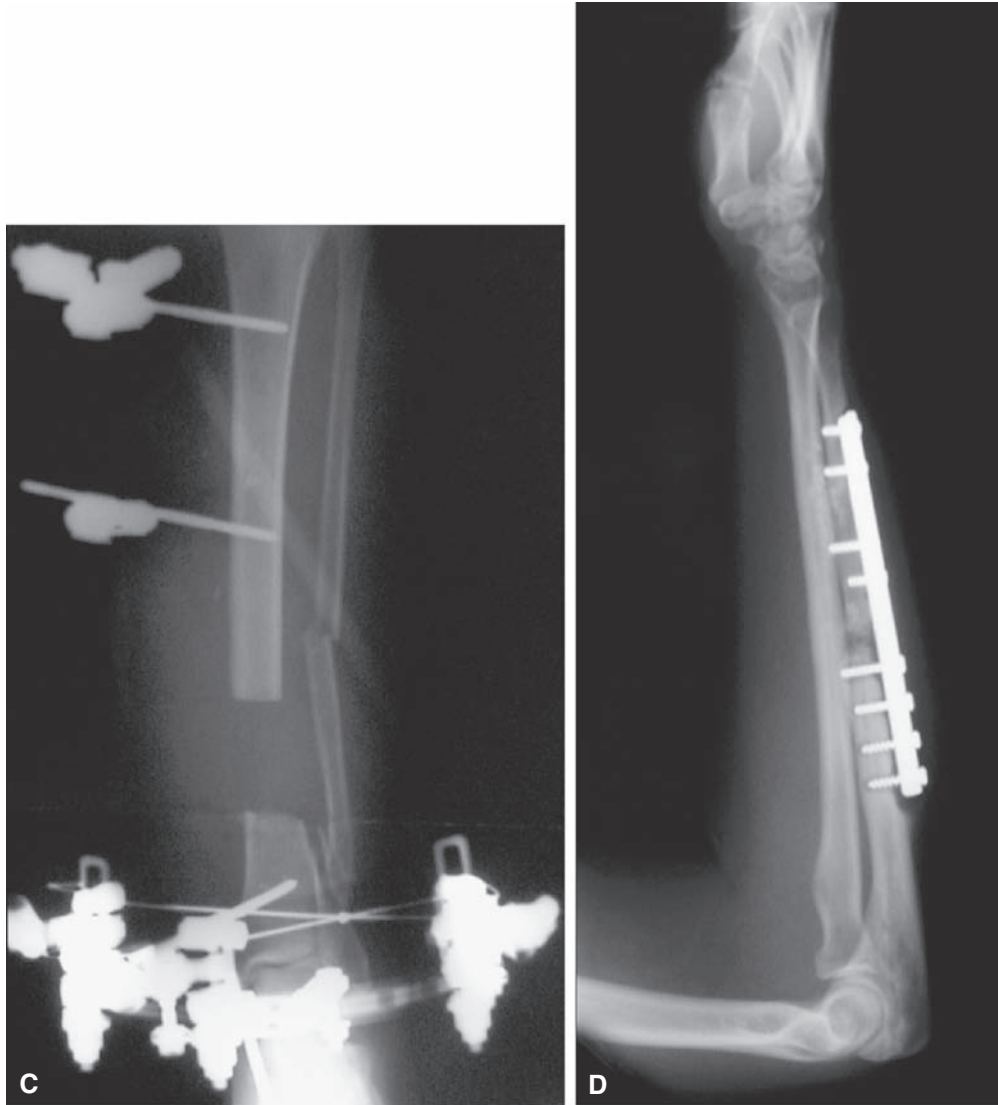

(Continued)

f9000

FIGURE 22-1

(Continued) **C, Bone loss.** A 57-year-old man had segmental bone loss following débridement of a high-energy open tibia fracture. **D, Poor bone quality.** A 31-year-old woman 2 years following open reduction internal fixation for an ulna shaft fracture; loss of fixation proved to be due to poor bone from chronic osteomyelitis.



of specific NSAIDs relative to delayed union or nonunion remain unknown.

p0250 Other medications have been postulated to affect fracture healing adversely, including phenytoin,¹²⁵ ciprofloxacin,¹³⁶ corticosteroids, anticoagulants, and others.

s0160 **OTHER CONTRIBUTING FACTORS**

p0260 Other factors that may retard fracture healing or contribute to fracture nonunion include advanced age,^{125,171,271} systemic medical conditions (such as diabetes),^{104,236} poor functional level with inability to bear weight, venous stasis, burns, irradiation, obesity,¹⁰² alcohol abuse,^{102,104,236} metabolic bone disease, malnutrition and cachexia, and vitamin deficiencies.⁷⁸

p0270 Animal studies (in rats) have shown that albumin deficiency produces a fracture callus with reduced strength

and stiffness,²⁴² although early fracture healing proceeds normally.⁸⁸ Dietary supplementation of protein during fracture repair reverses these effects and augments fracture healing.^{73,88} Protein intake in excess of normal daily requirements is not beneficial.^{117,242} Inadequate caloric intake, such as occurs among the elderly, also contributes to failure of fracture union.³⁰³

EVALUATION OF NONUNIONS

No two patients with fracture nonunion are identical. The evaluation process is perhaps the most critical step in the patient's treatment pathway and is when the surgeon begins to form opinions about how to heal the nonunion. The goals of the evaluation are to discover the etiology of the nonunion and form a plan for healing the nonunion.

s0170

p0280

Table 22-2	
Causes of Nonunions	
t0020	Predisposing Factors
	Mechanical instability
	Inadequate fixation
	Distraction
	Bone loss
	Poor bone quality
	Inadequate vascularity
	Severe injury
	Excessive soft tissue stripping
	Vascular injury
	Poor bone contact
	Soft tissue interposition
	Malposition or malalignment
	Bone loss
	Distraction
	Contributing Factors
	Infection
	Nicotine/cigarette smoking
	Certain medications
	Advanced age
Systemic medical conditions	
Poor functional level	
Venous stasis	
Burns	
Irradiation	
Obesity	
Alcohol abuse	
Metabolic bone disease	
Malnutrition	
Vitamin deficiencies	

Without an understanding of the etiology, the treatment strategy cannot be based on knowledge of fracture biology. A worksheet is an excellent method of assimilating the various data (Fig. 22-2).

s0180 **Patient History**

p0290 Evaluation begins with a thorough history, including the date and mechanism of injury of the initial fracture. Preinjury medical problems, disabilities, or associated injuries should be noted. The patient should be questioned regarding pain and functional limitations related to the nonunion. The specific details of each prior surgical procedure to treat the fracture and fracture nonunion must be obtained through the patient and family, the prior treating surgeons, and a review of all medical records since the time of the initial fracture.

p0300 Knowledge of prior operative procedures is empowering and critical for designing the right treatment plan. Conversely, ignorance of any prior surgical procedure can lead to needlessly repeating surgical procedures that have failed to promote bony union in the past. Worse yet, ignorance of prior surgical procedures can lead to avoidable complications. For example, awareness of the prior use of external fixation is important when the use of intramedullary nail fixation is contemplated because of the increased risk of infection.^{27,148,189,192,198,257,338}

The hospital records and operative reports from the time of the initial fracture may also be used to determine the condition of the tissues in the zone of the injury (open wounds, contamination, crush injuries, periosteal stripping, devitalized bone fragments, etc.) and the history of prior soft tissue coverage procedures. p0310

The history should also include details regarding prior wound infections. Culture reports should be sought in the medical records. Intravenous and oral antibiotic use should be documented, particularly if the patient remains on antibiotics at the time of presentation. Problems with wound healing and episodes of soft tissue breakdown should be documented. Other perioperative complications (venous thrombosis, nerve or vessel injuries, etc.) should also be documented. The use of adjuvant nonsurgical therapies, such as electromagnetic field and ultrasound therapy, should be documented. p0320

Finally, the patient should be questioned regarding other possible contributing factors for nonunion (see Table 22-2). A history of NSAID use should be obtained and its use discontinued. The pack-year history of cigarette smoking should be documented, and active smokers should be offered a program to halt the addiction. From a practical standpoint, however, it is unrealistic to delay treatment of a symptomatic nonunion until the patient stops smoking. p0330

Physical Examination

s0190 Following the history, a physical examination is performed. The general health and nutritional status of the patient should be assessed, since malnutrition and cachexia diminish fracture repair.^{90,117,242,303} Arm muscle circumference is the best indicator of nutritional status. Obese patients with nonunions have unique management problems related to achieving mechanical stability in the presence of high loads and large soft tissue envelopes.¹⁵² p0340

The skin and soft tissues in the fracture zone should be inspected. The presence of active drainage, sinus formation, and deformity should be noted. p0350

The nonunion site should be manually stressed to evaluate motion and pain. Generally, nonunions that display little or no clinically apparent motion have some callus formation and good vascularity at the fracture surfaces. Nonunions that display motion typically have poor callus formation but may have vascular or avascular fracture surfaces. Assessment of motion at a nonunion site is difficult in limbs with paired bones where one of the bones remains intact. p0360

A neurovascular examination should be performed to document vascular insufficiency and motor or sensory dysfunction. Active and passive motion of the joints adjacent to the nonunion, both proximal and distal, should be performed. Not uncommonly, motion at the nonunion site diminishes motion at an adjacent joint. For example, patients with a long-standing distal tibial nonunion often have a fixed equinus contracture and limited ankle motion (Fig. 22-3). Similarly, patients with supracondylar humeral nonunions commonly have fibrous ankylosis of the elbow joint (Fig. 22-4). Such problems may alter both the treatment plan and the expectations for the ultimate functional outcome. p0370

FIGURE 22-2 Worksheet for patients with nonunions.

GENERAL INFORMATION

Patient Name: _____ Age: _____ Gender: _____
 Referring Physician: _____ Height: _____ Weight: _____
 Injury (description): _____
 Date of Injury: _____
 Mechanism of Injury: _____ Pain (0 to 10 VAS): _____
 Occupation: _____ Was Injury Work Related?: Y N

PAST HISTORY

Initial Fracture Treatment (Date): _____
 Total # of Surgeries for Nonunion: _____
 Surgery #1 (Date): _____
 Surgery #2 (Date): _____
 Surgery #3 (Date): _____
 Surgery #4 (Date): _____
 Surgery #5 (Date): _____
 Surgery #6 (Date): _____
 (Use backside of this sheet for other prior surgeries)

Use of Electromagnetic or Ultrasound Stimulation? _____
 Cigarette Smoking # of packs per day _____ # of years smoking _____
 History of Infection? (include culture results) _____
 History of Soft Tissue Problems? _____
 Medical Conditions: _____
 Medications: _____
 NSAID Use? _____
 Narcotic Use: _____
 Allergies: _____

PHYSICAL EXAMINATION

General: _____
 Extremity: _____
 Nonunion: _____ Stiff _____ Lax _____
 Adjacent Joints (ROM, compensatory deformities): _____
 Soft Tissues (defects, drainage): _____
 Neurovascular Exam: _____

RADIOLOGIC EXAMINATION

Comments _____

OTHER PERTINENT INFORMATION _____

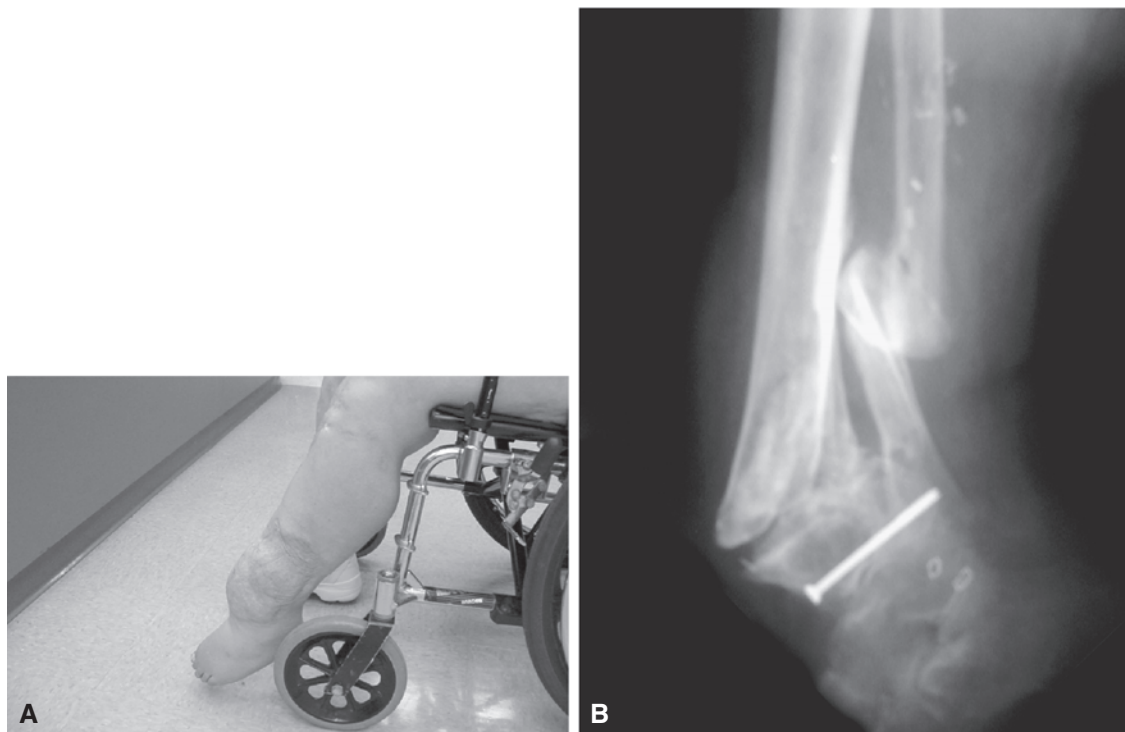
NONUNION TYPE

_____ Hypertrophic
 _____ Oligotrophic
 _____ Atrophic
 _____ Infected
 _____ Synovial Pseudarthrosis

p0380 An interesting situation worth noting is the stiff nonunion with an angular deformity. These patients may already have developed a compensatory fixed deformity at an adjacent joint. The fixed deformity at the joint must be recognized preoperatively, and the treatment plan must include its correction. Realigning a stiff nonunion with a deformity without addressing an adjacent compensatory joint deformity results in a straight bone with a deformed joint, thus producing a disabled limb. For example, patients who have a stiff distal tibial nonunion with a varus deformity often develop a compensatory valgus deformity at the subtalar joint to achieve a plantigrade foot for gait. Upon visual inspection, the distal limb segment appears aligned, but radiographs show the distal tibial varus deformity. To determine whether the subtalar joint

deformity is fixed or mobile (reducible), the patient is asked to position the subtalar joint in varus (i.e., invert the foot). If the patient cannot invert the subtalar joint, and the examiner cannot passively invert the subtalar joint, the joint deformity is fixed. Deformity correction will therefore be required at both the nonunion site and the subtalar joint. On the other hand, if the patient can achieve subtalar inversion, the deformity at the joint will resolve with deformity correction at the nonunion. In summary, if the patient cannot place the joint into the position that parallels the deformity at the nonunion site, the joint deformity is fixed and requires correction. If the patient can achieve the position, the joint deformity will resolve with realignment of the long bone deformity (Fig. 22-5).

f0030 **FIGURE 22-3** A 20-year-old woman had a distal tibial nonunion 22 months following a high-energy open fracture. **A**, Clinical photograph. **B**, Lateral radiograph showing apex anterior angulation at the fracture site resulting in the clinical equivalent of a severe equinus contracture.



p0390 If bone grafting is contemplated, the anterior and posterior iliac crests should be examined for evidence (e.g., incisions) of prior surgical harvesting. In a patient who has had prior spinal surgery with a midline posterior incision, determining which posterior crest has already been harvested may be difficult. In such a case, the posterior iliac crests may be evaluated via plain radiographs or computed tomography (CT) scan.

s0200 Radiologic Examination

s0210 PLAIN RADIOGRAPHS

p0400 A review of the original fracture films reveals the character and severity of the initial bony injury. They can also show the progress or lack of progress toward healing when compared with the most recent plain radiographs.

p0410 Subsequent radiographs of the salient aspects of previous treatments will always tell the story of the nonunion. The story, however, may only reveal itself to the astute observer. The prior plain films should be carefully examined for the status of orthopaedic hardware (e.g., loose, broken, inadequate in size or number of implants), including removal or insertion, on subsequent films. The evolution of deformity at the nonunion site—whether a gradual process or single event, for instance—should be evaluated via the prior radiographs. The presence of healed or unhealed articular, butterfly, and wedge fragments should also be noted. The time course of missing or removed bony fragments, added bone graft, and implanted bone stimulators should be reconstructed so that the subsequent fracture repair response can be evaluated.

The nonunion is next evaluated with current radiographs, including an anteroposterior (AP) and lateral radiograph of the involved bone, including the proximal and distal joints; AP, lateral, and two oblique views of the nonunion site on small cassette films, which improve magnification and resolution (Fig. 22-6); bilateral AP and lateral 51-in. alignment radiographs for lower extremity nonunions (for assessing length discrepancies and deformities) (Fig. 22-7); and flexion/extension lateral radiographs to determine the arc of motion and to assess the relative contributions of the joint and the nonunion site to that arc of motion.

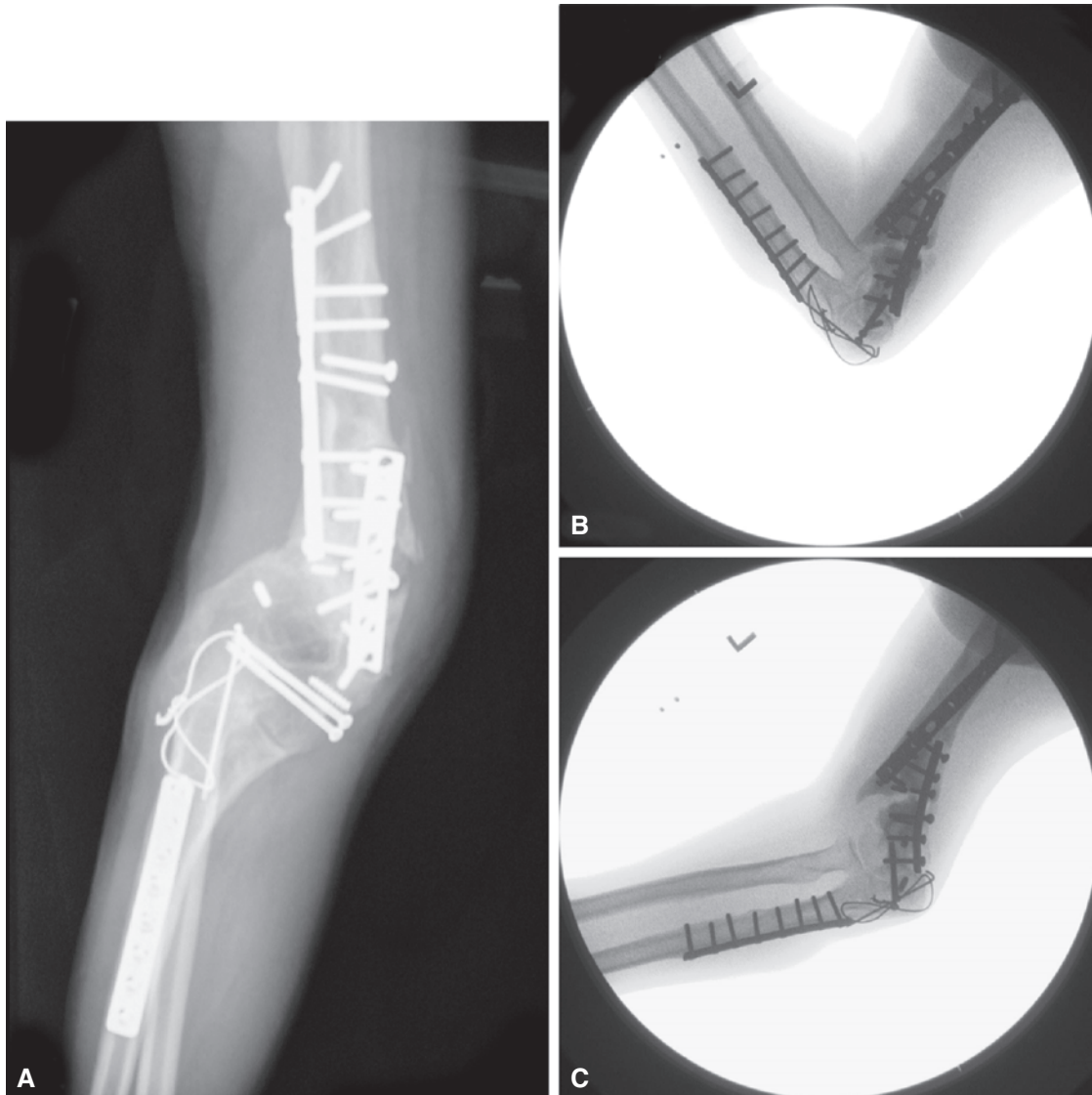
The current plain films are used to evaluate the following radiographic characteristics of a nonunion: anatomic location, healing effort, bone quality, surface characteristics, status of previously implanted hardware, and deformities.

ANATOMIC LOCATION Diaphyseal nonunions involve primarily cortical bone, whereas metaphyseal and epiphyseal nonunions largely involve cancellous bone. The presence or absence of intra-articular extension of the nonunion should also be evaluated.

HEALING EFFORT AND BONE QUALITY The radiographic healing effort and bone quality help define the biological and mechanical etiologies of the nonunion. The assessment of healing includes evaluating radiolucent lines, gaps, and callus formation. The assessment of bone quality includes observing sclerosis, atrophy, osteopenia, and bony defects.

Radiolucent lines seen along fracture surfaces suggest regions that are devoid of bony healing. The simple

f0040 **FIGURE 22-4** **A**, AP radiograph of a 32-year-old man with a supracondylar humeral nonunion. On physical examination it can be difficult to differentiate motion at the nonunion site and the elbow joint. This patient had very limited range of motion at the elbow but gross motion at the nonunion site. Cineradiography can be useful for evaluating the contribution of the adjacent joint and the nonunion site to the arc of motion. **B** and **C**, Cineradiographs showing flexion and extension of the elbow, respectively, reveal that most of the motion is occurring through the nonunion site, not the elbow joint. This patient should be counseled preoperatively regarding elbow stiffness following stabilization of the nonunion.



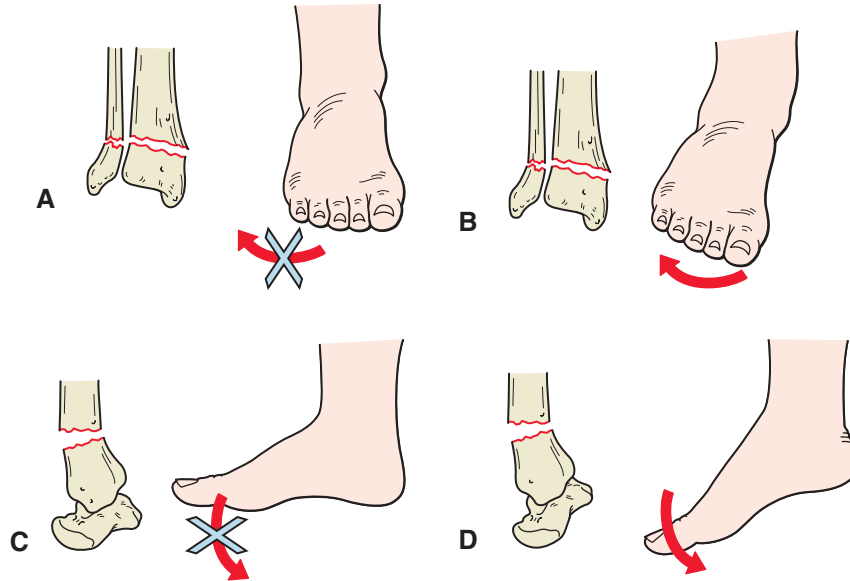
presence of radiolucent lines seen on plain radiographs is not synonymous with fracture nonunion. Conversely, the lack of a clear radiolucent line does not confer fracture union (Fig. 22-8).

p0470 Callus formation occurs in fractures and nonunions with an adequate blood supply but does not necessarily imply the bone is solidly uniting. AP, lateral, and oblique radiographs should be assessed for callus bridging the zone of injury. The radiographs should be carefully checked for radiolucent lines so that a nonunion with abundant callus is not mistaken for a solidly united fracture (see Fig. 22-8).

Weber and Cech³²⁹ classify nonunions based on radio- p0480 graphic healing effort and bone quality as *viable nonunions*, which are capable of biological activity, and *nonviable nonunions*, which are incapable of biological activity.

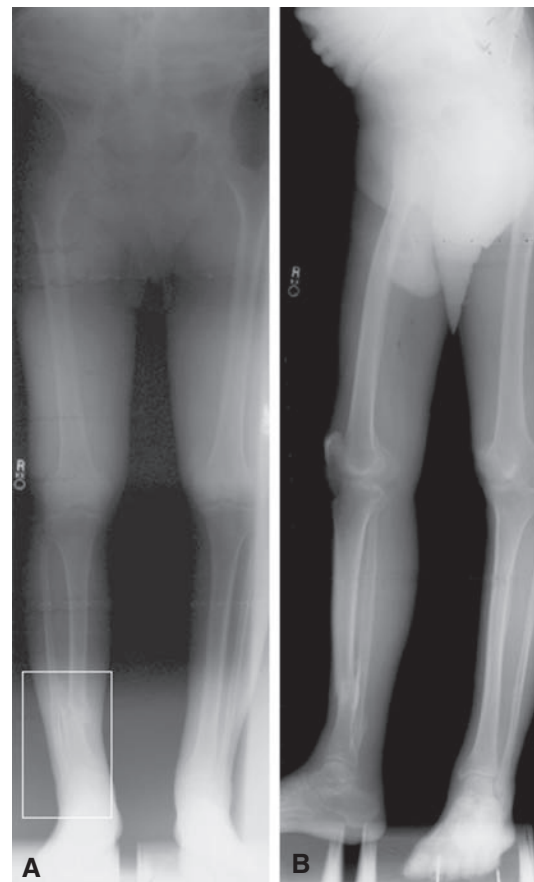
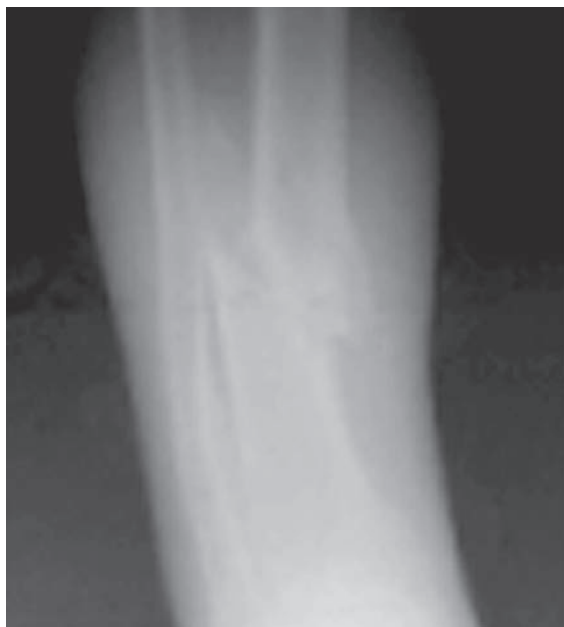Viable nonunions include *hypertrophic nonunions* and p0490 *oligotrophic nonunions*. Hypertrophic nonunions possess adequate vascularity and display callus formation. They arise as a result of inadequate mechanical stability with persistent motion at the fracture surfaces. The fracture site is progressively resorbed with accumulation of unmineralized fibrocartilage and displays a progressively widening

f0050 **FIGURE 22-5** Angular deformity at a nonunion site that is near a joint can result in a compensatory deformity through a neighboring joint. For example, coronal plane deformities of the distal tibia can result in a compensatory coronal plane deformity of the subtalar joint. A deformity of the subtalar joint is fixed if the patient's foot cannot be positioned into the deformity of the distal tibia **(A)** or flexible if it can be positioned into the deformity of the distal tibia **(B)**. Sagittal plane deformities of the distal tibia can result in a sagittal plane deformity of the ankle joint. A deformity of the ankle joint is fixed if the patient's foot cannot be positioned into the deformity of the distal tibia **(C)** or flexible if it can be positioned into the deformity of the distal tibia **(D)**.



f0070 **FIGURE 22-7** A 60-year-old man with a tibial nonunion and an oblique plane angular deformity as seen on the 51-in. AP alignment view **(A)** and 51-in. lateral alignment view **(B)**.

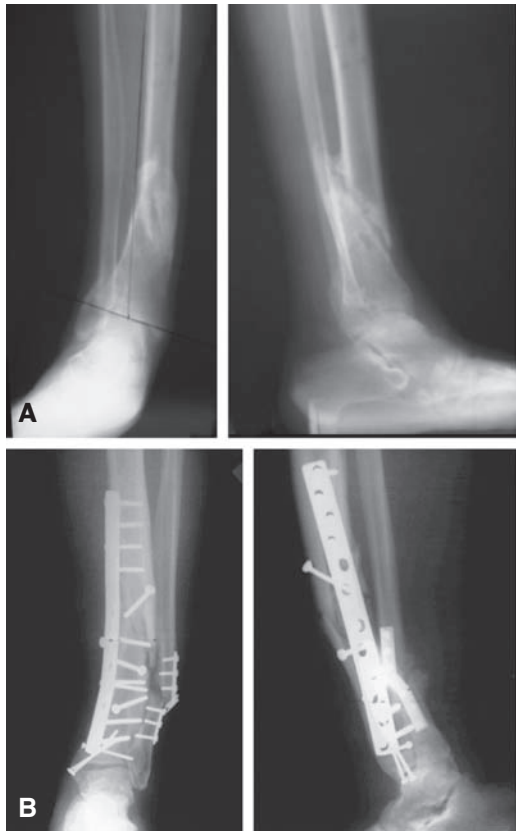f0060 **FIGURE 22-6** A nonunion is visualized better on small cassette views than on large cassette views (see Fig. 22-7 for comparison).



f0080

FIGURE 22-8

A definitive decision cannot always be made about bony union based on plain radiographs. **A**, An 88-year-old woman 14 months following a distal tibial fracture treated with external fixation. AP and lateral radiographs are shown. Is this fracture healed, or is there a nonunion? (See Fig. 22-17.) **B**, A 49-year-old man 13 months after open reduction internal fixation of a distal tibia fracture. AP and lateral radiographs are shown. Is this fracture healed or is there a nonunion? (See Fig. 22-17.)



radiolucent line with sclerotic edges. The reason that persistent motion inhibits calcification of fibrocartilage remains obscure.²³⁷ Capillaries and blood vessels invade both sides of the nonunion but do not penetrate the fibrocartilaginous tissue (Fig. 22-9).²⁵² Since motion persists at the nonunion site, endosteal callus may accumulate and seal off the medullary canal, increasing production of hypertrophic periosteal callus. Hypertrophic nonunions may be classified as *elephant foot type*, with abundant callus formation, or *horse hoof type*, which are still hypertrophic but with less abundant callus formation.

p0500

Oligotrophic nonunions have an adequate blood supply but little or no callus formation. Oligotrophic nonunions arise from inadequate reduction with displacement at the fracture site.


p0510

Nonviable nonunions do not display callus formation and are incapable of biological activity. Their inadequate vascularity precludes the formation of periosteal and endosteal callus. The radiolucent gap observable on plain

FIGURE 22-9

Microangiogram of a hypertrophic delayed union of a canine radius. Note the tremendous increase in local vascularity. The capillaries, however, are unable to penetrate the interposed fibrocartilage (arrows). (From Rhinelander, F.W. The normal microcirculation of diaphyseal cortex and its response to fracture. *J Bone Joint Surg Am* 50: 784-800, 1968.)

f0090



radiographs is bridged by fibrous tissue that has no osteogenic capacity. An *atrophic nonunion* is the most advanced type of nonviable nonunion. Classically, the ends of the bony surfaces have been thought to be avascular, although a recent study has questioned this conventional wisdom.^{37,249} Radiographically, the fracture surfaces appear partially absorbed and osteopenic. Severe cases may show large sclerotic avascular bone segments or segmental bone loss.

SURFACE CHARACTERISTICS

A nonunion's surface characteristics (Fig. 22-10) are prognostic in regard to its resistance to healing with various treatment strategies. Surface characteristics that should be evaluated on plain radiographs include the surface area of adjacent fragments, extent of current bony contact, orientation of the fracture lines (shape of the bone fragments), and stability to axial compression (a function of fracture surface orientation and comminution). The nonunions that are generally the easiest to treat have good bony contact and large, transversely oriented surfaces that are stable to axial compression.

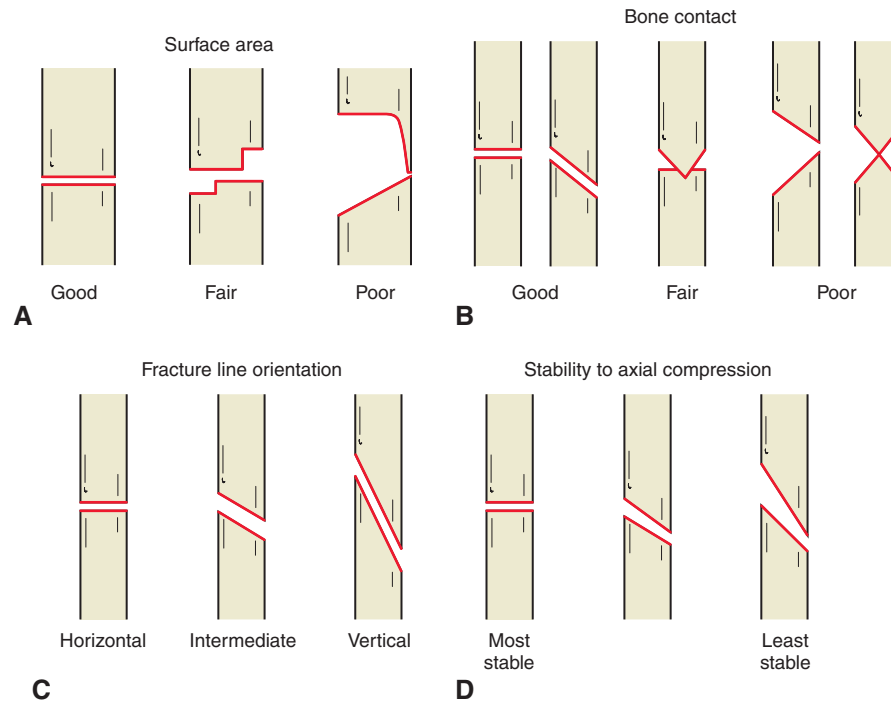
STATUS OF PREVIOUSLY IMPLANTED HARDWARE

Plain radiographs reveal the status of previously implanted hardware and thus the stability of the mechanical construct used to fixate the bone. Loose or broken implants denote instability at the nonunion site (i.e., the race between bony union and hardware failure has been lost),^{209,226,267-270,273,275} which requires further stabilization before union can occur. Radiographs are also useful in terms of planning which hardware will need to be removed to carry out the next treatment plan.

DEFORMITIES

After assessment is performed for clinical deformity via physical examination, plain radiographs are used to further and more fully characterize all other deformities associated with the fracture nonunion. Deformities are characterized by location (diaphyseal, metaphyseal,

f0100 **FIGURE 22-10** Surface characteristics at the site of nonunion. **A**, Surface area. **B**, Bone contact. **C**, Fracture line orientation. **D**, Stability to axial compression.



epiphyseal), magnitude, and direction and are described in terms of length, angulation, rotation, and translation.²¹⁹

p0550 Deformities involving length include shortening and overdistraction. They are measured in centimeters on plain radiographs by comparison to the contralateral normal extremity, using an x-ray marker to correct for magnification. Shortening may result from bone loss (from the injury or débridement) or overriding fracture fragments (malreduction). Overdistraction may result from a traction injury or improper positioning at the time of surgical fixation.

p0560 Deformities involving angulation are characterized by magnitude and direction of the apex of angulation. Pure sagittal or coronal plane deformities are simple to characterize. When coronal plane angulation is present in the lower extremity, it commonly results in an abnormality to the mechanical axis of the extremity (mechanical axis deviation) (Fig. 22-11). Varus deformities result in medial mechanical axis deviation, and valgus deformities in lateral mechanical axis deviation.

p0570 Oblique plane angular deformities occur in a single plane that is neither the sagittal nor the coronal plane. Oblique plane angular deformities can be characterized using either the trigonometric method or the graphic method (see Fig. 22-11).^{33,133,221-223}

p0580 Angulation at a diaphyseal nonunion is usually obvious on plain radiographs. The angulation results in divergence of the anatomic axes (mid-diaphyseal lines) of the proximal and distal fragments (see Fig. 22-11). The magnitude and direction of angulation can be measured by drawing the anatomic axes of the proximal and distal segments (see Fig. 22-11).

p0590 Angular deformities associated with nonunions of the metaphysis and epiphysis (juxta-articular deformities) may not be so obvious and are not so simple to evaluate as

diaphyseal deformities. The mid-diaphyseal line method will not characterize a juxta-articular deformity. Recognition and characterization of a juxta-articular deformity require using the angle formed by the intersection of a joint orientation line and the anatomic or mechanical axis of the deformed bone (Fig. 22-12). When the angle formed differs markedly from the contralateral normal extremity, a juxta-articular deformity is present. If the contralateral extremity is also abnormal (e.g., bilateral injuries), the normal values described for the lower extremity are used (Table 22-3).^{35,223}

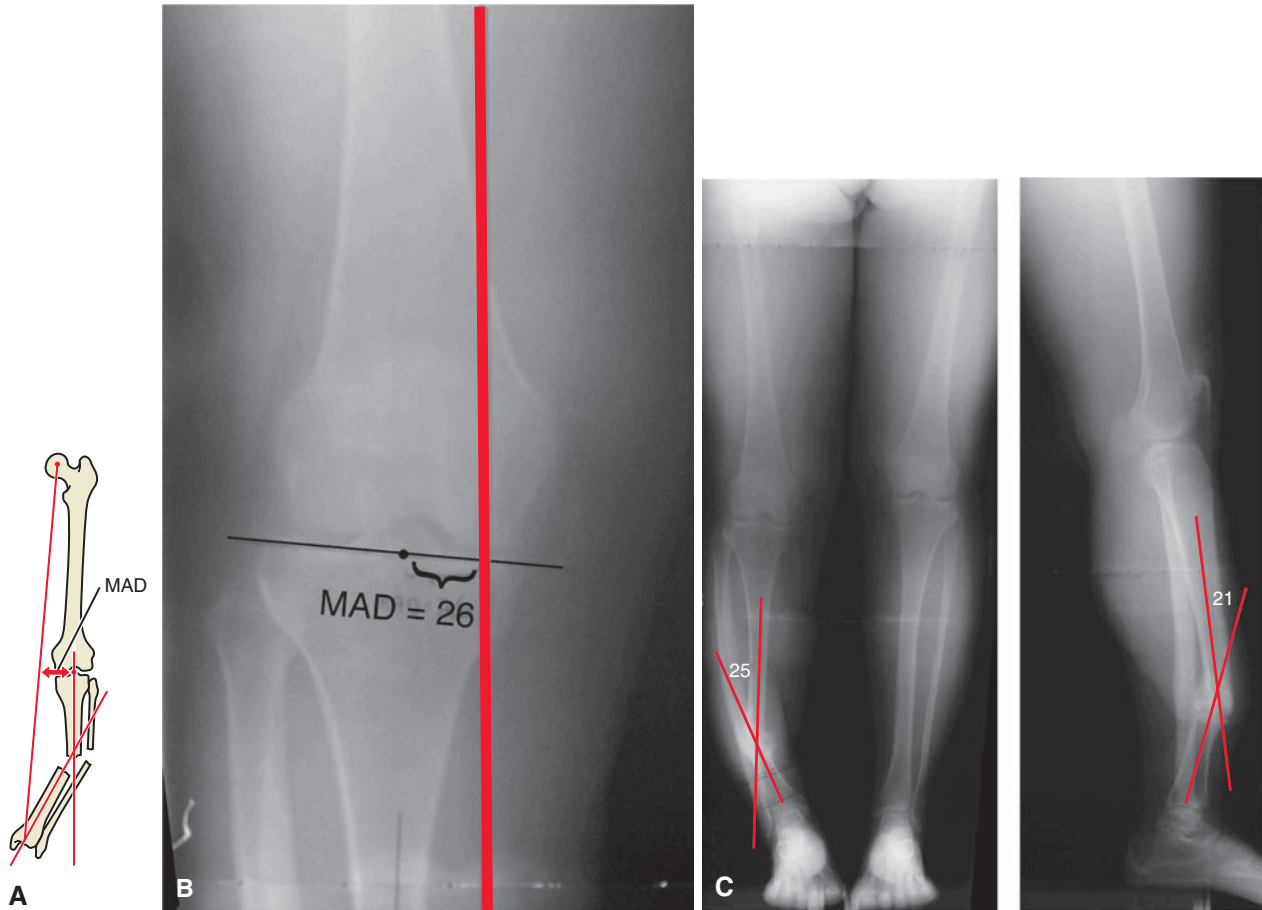
The center of rotation of angulation (CORA) is the point at which the axis of the proximal segment intersects the axis of the distal segment (Fig. 22-13).²¹⁹ For diaphyseal deformities, the anatomic axes are convenient to use. For juxta-articular deformities, the axis line of the short segment is constructed using one of three methods: extending the segment axis from the adjacent, intact bone if its anatomy is normal; comparing the joint orientation angle of the abnormal side to the opposite side if the latter is normal; or drawing a line that creates the population normal angle formed by the intersection with the joint orientation line.

The bisector is a line that passes through the CORA and bisects the angle formed by the proximal and distal axes (see Fig. 22-13).²¹⁹ Angular correction along the bisector results in complete deformity correction without the introduction of a translational deformity.^{33,221-223}

Rotational deformities associated with a nonunion may be missed on physical and radiologic examination because attention is focused on more obvious problems (un-united bone, pain, infection, etc). Accurate clinical assessment of the magnitude of a rotational deformity is difficult, and plain x-rays offer little assistance. The best method of radiographic assessment of malrotation is described below in the CT scanning section.

f0110

FIGURE 22-11 **A**, Nonunion of the diaphysis of the tibia with a varus deformity resulting in medial mechanical axis deviation. Note the divergence of the anatomic axis of the proximal and distal fragments of the tibia. **B**, Close-up view of a section of an AP 51-in. alignment radiograph of a 37-year-old woman with an 18-year history of a tibial nonunion. Note the medial mechanical axis deviation (MAD) of 26 mm. **C**, AP and lateral radiographs show a 25° varus deformity and a 21° apex anterior angulation deformity, respectively. **D**, Characterization of the oblique plane angular deformity using the trigonometric method. **E**, Characterization of the oblique plane angular deformity using the graphic method.



Trigonometric Method

Magnitude of oblique plane deformity =

$$\frac{\tan^{-1} \sqrt{\tan^2 \text{coronal deformity} + \tan^2 \text{sagittal deformity}}}{\tan^{-1} \sqrt{\tan^2 25^\circ + \tan^2 21^\circ}}$$

Solution = 31°

Orientation of oblique plane deformity =

$$\tan^{-1} \frac{\tan \text{sagittal deformity}}{\tan \text{coronal deformity}}$$

$$\tan^{-1} \frac{\tan 21^\circ}{\tan 25^\circ}$$

Solution = 39°

D

Graphic Method

Magnitude of oblique plane deformity =

$$\frac{\sqrt{\text{Coronal deformity}^2 + \text{Sagittal deformity}^2}}{\sqrt{25^2 + 21^2}}$$

Solution = 33°

Orientation of oblique plane deformity =

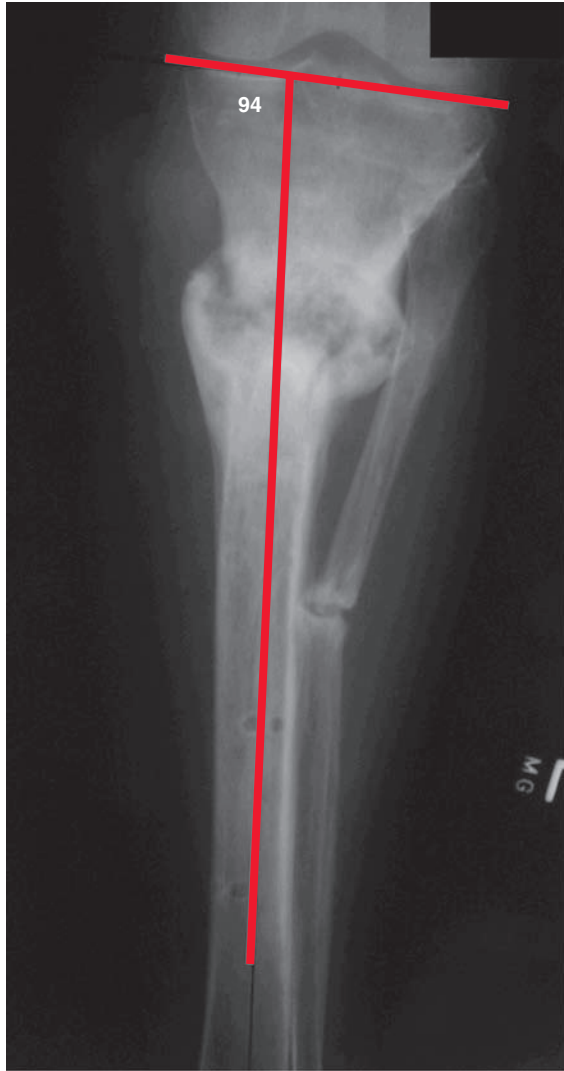$$\tan^{-1} \frac{\text{Sagittal deformity}}{\text{Coronal deformity}}$$

$$\tan^{-1} \frac{21^\circ}{25^\circ}$$

Solution = 40°

E

f0120 **FIGURE 22-12** Nonunion of the proximal tibia with a valgus deformity resulting in lateral mechanical axis deviation. The proximal medial tibial angle of 94° is abnormally high compared to both the contralateral normal extremity and the population normal values (see Table 22-3).



p0630 Like angular deformities, translational deformities associated with a nonunion are characterized by magnitude and direction. The magnitude of translation is measured as the perpendicular distance from the axis line of the proximal fragment to the axis line of the distal fragment. With combined angulation and translation (where the fragments are not parallel), translation is measured at the level of the proximal end of the distal fragment (Fig. 22-14).

p0640 When both angular and translational deformities are present at a nonunion site, the CORA will be at different levels on AP and lateral radiographs (Fig. 22-15). When the deformity involves pure angulation (without translation), the CORA will be at the same level on both radiographs.

p0650 In addition to assessing bony deformities, the radiographic evaluation should identify any compensatory

deformities of the joints adjacent to the nonunion. In some cases, these compensatory deformities are clinically apparent, but not always. As previously stated, failure to recognize and correct the compensatory joint deformity leads to a healed and straight bone with suboptimal functional improvement.

Radiographic analysis should therefore be performed at adjacent joints when a deformity is present at the site of a nonunion. This is particularly important for a tibial nonunion with a coronal plane angular deformity because a compensatory deformity at the subtalar joint is not only common but commonly missed. Varus tibial deformities result in compensatory subtalar valgus deformities, and valgus tibial deformities result in compensatory subtalar varus deformities. Compensatory subtalar joint deformities are evaluated using the extended Harris view of both lower extremities, which allows measurement of the orientation of the calcaneus relative to the tibial shaft in the coronal plane (Fig. 22-16).

COMPUTED AND PLAIN TOMOGRAPHY

Plain radiographs are not always sufficient regarding the status of fracture healing. Sclerotic bone and orthopaedic hardware may obscure the fracture site, particularly in stiff nonunions or those well-stabilized by hardware.²⁶ CT scans and tomography are useful in such cases (Fig. 22-17). CT scans can be used to estimate the percentage of the cross-sectional area that shows bridging bone (Fig. 22-18). Nonunions typically show bone bridging of less than 5 percent of the cross-sectional area at the fracture surfaces (see Fig. 22-18). Healed or healing fracture nonunions typically show bone bridging of greater than 25 percent of the cross-sectional area. Serial CT scans may be followed to evaluate the progression of fracture consolidation (see Fig. 22-18). CT scans are also useful for assessing intra-articular nonunions for articular step-off and joint incongruence.

Plain tomography helps evaluate the extent of bony union when hardware artifact compromises CT images.

Rotational deformities may be accurately quantified using CT by comparing the relative orientations of the proximal and distal segments of the involved bone to the contralateral normal bone. This technique has been mostly used for femoral malrotation^{129,135,184} but may be used for any long bone.

NUCLEAR IMAGING

Several nuclear imaging studies are useful for assessing bone vascularity at the nonunion site, the presence of a synovial pseudarthrosis, and infection.

Technetium-99m-pyrophosphate (“bone scan”) complexes reflect increased blood flow and bone metabolism and are absorbed onto hydroxyapatite crystals in areas of trauma, infection, and neoplasia. The bone scan will show increased uptake in viable nonunions because there is a good vascular supply and osteoblastic activity (Fig. 22-19).

A *synovial pseudarthrosis* (nearthrosis) is distinguished from a nonunion by the presence of a synovium-like fixed pseudocapsule surrounding a fluid-filled cavity. The medullary canals are sealed off, and motion occurs at this “false joint.”^{274,329} Synovial pseudarthrosis may arise in sites

t0030

Table 22-3

Normal Values^{222,223} Used to Assess Lower Extremity Metaphyseal and Epiphyseal Deformities (Juxta-articular Deformities) Associated with Nonunions

Anatomic Site of Deformity	Plane	Angle	Description*	Normal Values
Proximal femur	Coronal	Neck shaft angle	Defines the relationship between the orientation of the femoral neck and the anatomic axis of the femur	130° (range, 124°–136°)
		Anatomic medial proximal femoral angle	Defines the relationship between the anatomic axis of the femur and a line drawn from the tip of the greater trochanter to the center of the femoral head	84° (range, 80°–89°)
		Mechanical lateral proximal femoral angle	Defines the relationship between the mechanical axis of the femur and a line drawn from the tip of the greater trochanter to the center of the femoral head	90° (range, 85°–95°)
Distal femur	Coronal	Anatomic lateral distal femoral angle	Defines the relationship between the distal femoral joint orientation line and the anatomic axis of the femur	81° (range, 79°–83°)
		Mechanical lateral distal femoral angle	Defines the relationship between the distal femoral joint orientation line and the mechanical axis of the femur	88° (range, 85°–90°)
	Sagittal	Anatomic posterior distal femoral angle	Defines the relationship between the sagittal distal femoral joint orientation line and the mid-diaphyseal line of the distal femur	83° (range, 79°–87°)
		Mechanical posterior distal femoral angle	Defines the relationship between the sagittal distal femoral joint orientation line and the mechanical axis of the distal femur	83° (range, 79°–87°)
Proximal tibia	Coronal	Mechanical medial proximal tibial angle	Defines the relationship between the proximal tibial joint orientation line and the mechanical axis of the tibia	87° (range, 85°–90°)
	Sagittal	Anatomic posterior proximal tibial angle	Defines the relationship between the sagittal proximal tibial joint orientation line and the mid-diaphyseal line of the tibia	81° (range, 77°–84°)
Distal tibia	Coronal	Mechanical lateral distal tibial angle	Defines the relationship between the distal tibial joint orientation line and the mechanical axis of the tibia	89° (range, 88°–92°)
	Sagittal	Anatomic anterior distal tibial angle	Defines the relationship between the sagittal distal tibial joint orientation line and the mid-diaphyseal line of the tibia	80° (range, 78°–82°)

*Anatomic axes: femur, mid-diaphyseal line; tibia, mid-diaphyseal line. Mechanical axes: femur, defined by a line from the center of the femoral head to the center of the knee joint; tibia, defined by a line from the center of the knee joint to the center of the ankle joint; lower extremity, defined by a line from the center of the femoral head to the center of the ankle joint.

with hypertrophic vascular callus formation or in sites with poor callus formation and poor vascularity. The diagnosis of synovial pseudarthrosis is made when technetium-99m-pyrophosphate bone scans show a “cold cleft” at the nearthrosis between hot ends of un-united bone (see Fig. 22-19).^{32,93,94,274}

p0730 Radiolabeled white blood cell scans (such as with indium-111 or technetium-99m-HMPAO [hexamethylpropylene amine oxime]) are used for evaluating acute bone infection. Labeled polymorphonuclear leukocytes (PMNs) accumulate in areas of acute infections.

p0740 Gallium scans are useful in the evaluation of chronic bone infections. Gallium-67 citrate localizes to sites of chronic inflammation. The combination of gallium-67 citrate and technetium-99m sulfa colloid bone marrow scans can clarify the diagnosis of a chronically infected nonunion.

s0290 **OTHER RADIOLOGIC STUDIES**

p0750 Fluoroscopy and cineradiography (see Fig. 22-4) may be needed to determine the relative contribution of a joint and an adjacent nonunion to the overall arc of motion. Fluoroscopy is also helpful for guided needle aspiration of a nonunion site.

p0760 Ultrasonography is useful for assessing the status of the bony regenerate (distraction osteogenesis) during bone transport or lengthening. Fluid-filled cysts in the regenerate can be visualized and aspirated using ultrasound technology, thereby shortening the time of regenerate maturation (Fig. 22-20). Ultrasonography can also confirm the

presence of a fluid-filled pseudocapsule when synovial pseudarthrosis is suspected.

Magnetic resonance imaging (MRI) is occasionally used to evaluate the soft tissues at the nonunion site or the cartilaginous and ligamentous structures of the adjacent joints. p0770

Sinograms may be used to image the course of sinus tracts in infected nonunions. p0780

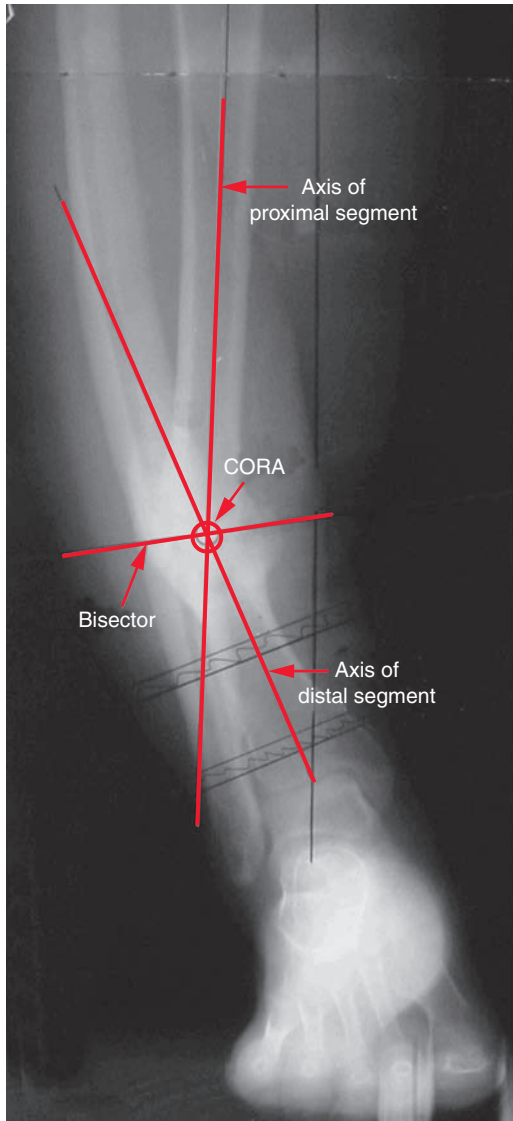
Angiography provides anatomic detail of vessels as they course through a scarred and deformed limb. This study is unnecessary in most patients with a fracture nonunion but is indicated if the viability of the limb is in question.¹¹⁴ p0790

Preoperative venous Doppler studies should be used to rule out deep venous thrombosis in patients with a lower extremity nonunion who have been confined to a wheelchair or bedridden for an extended period. Intraoperative or postoperative recognition of a venous thrombus or an embolus in a patient who has not been screened preoperatively does not make for a happy patient, family, or orthopaedic surgeon. p0800

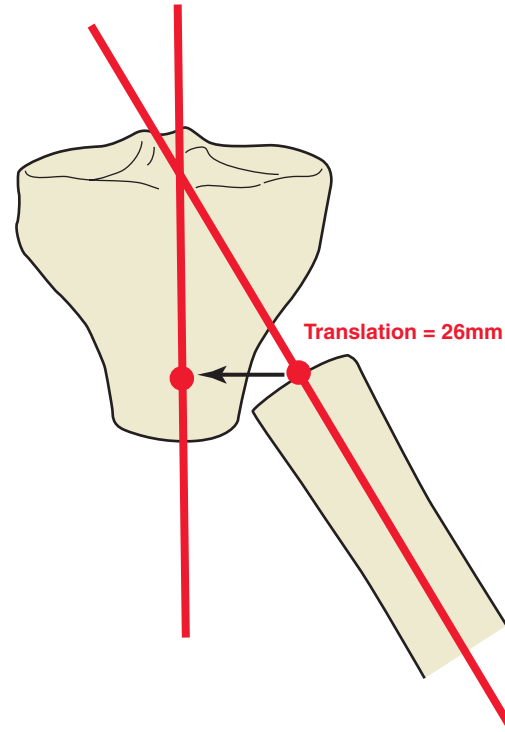
Laboratory Studies

Routine laboratory work, including electrolytes and a CBC, are useful for screening general health. The sedimentation rate and C-reactive protein are useful in regard to the course of infection. If necessary, the nutritional status of the patient can be assessed via anergy panels, albumin levels, and transferrin levels. If wound-healing potential is in question, an albumin level (3.0 g/dL or more is preferred), and a total lymphocyte count (>1500 cells/mm³ is preferred) can be obtained. For patients with p0810

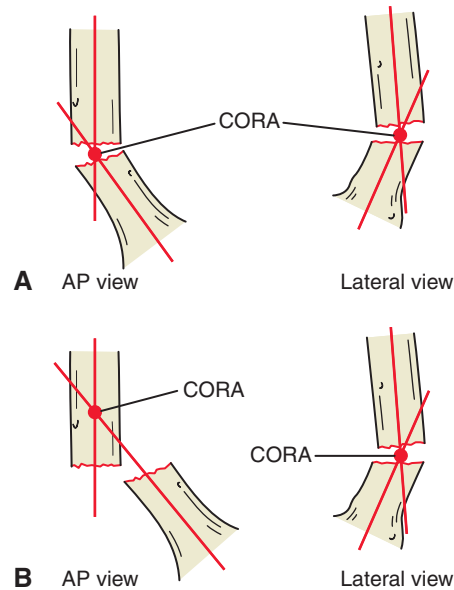
f0130 **FIGURE 22-13** The same case shown in Figure 22-11 with a diaphyseal nonunion with deformity. The center of rotation of angulation (CORA) and bisector are shown.



f0140 **FIGURE 22-14** Method for measuring translational deformities. The magnitude of translation is measured at the level of the proximal end of the distal fragment.



f0150 **FIGURE 22-15** **A**, When the deformity at the nonunion site involves angulation without translation, the center of rotation of angulation (CORA) will be seen at the same level on both AP and lateral radiographs. **B**, When the deformity at the nonunion site involves both angulation and translation, the CORA will be seen at a different level on AP and lateral radiographs.



a history of multiple blood transfusions, a hepatitis panel and an HIV test may also be useful.

p0820 When infection is suspected, the nonunion site may be aspirated or biopsied under fluoroscopic guidance. The aspirated or biopsied material is sent for a cell count and gram staining, and cultures are done for aerobic, anaerobic, fungal, and acid-fast bacillus organisms. To encourage the highest yield possible, all antibiotics should be discontinued at least 2 weeks prior to aspiration.

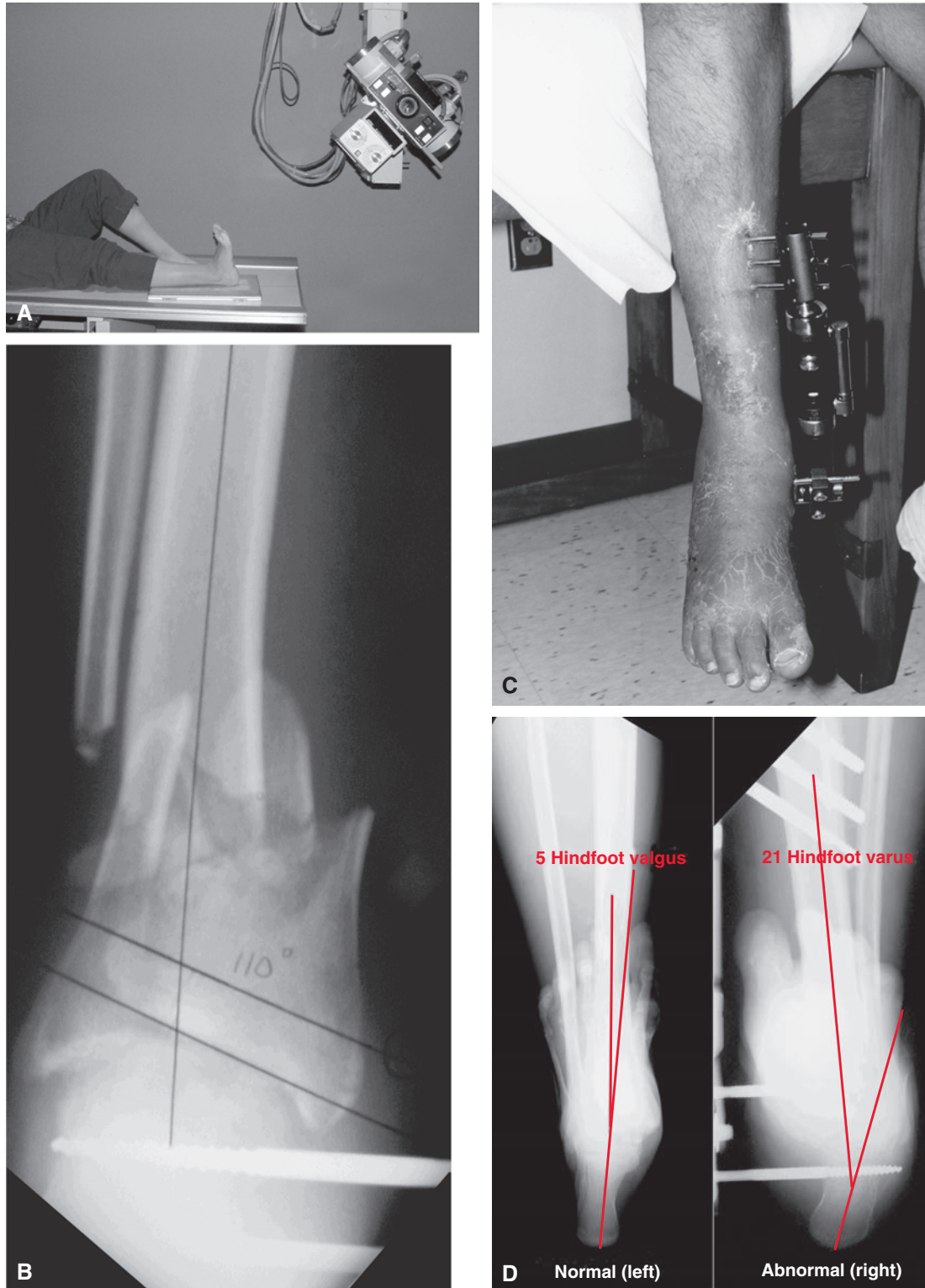
s0310 **Consultations**

p0830 Many issues commonly accompany nonunion, including soft tissue problems, infection, chronic pain, depression, motor or sensory dysfunction, joint stiffness, and unrelated medical problems. A team of subspecialists usually is

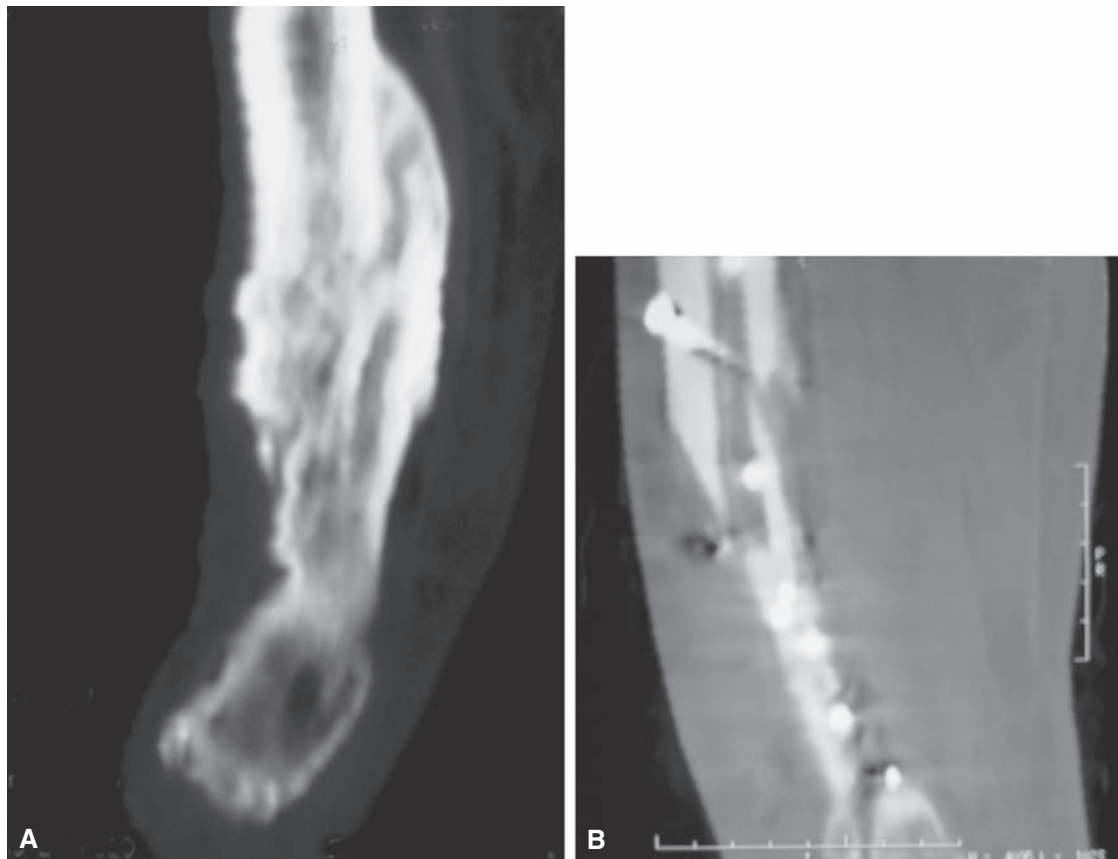
f0160

FIGURE 22-16

The extended Harris view is performed to image the orientation of the hindfoot to the tibial shaft in the coronal plane. **A**, The patient is positioned lying supine on the x-ray table with the knee in full extension and the foot and ankle in maximal dorsiflexion. The x-ray tube is aimed at the calcaneus at a 45° angle with a tube distance of 60 in. **B**, AP radiograph of the tibia shows a distal tibial nonunion with a valgus deformity. This patient had been treated with an external fixator. In an effort to correct the distal tibial deformity, the hindfoot had been fixed in varus through the subtalar joint. **C**, On clinical inspection, this situation is not always obvious and can be missed. **D**, The extended Harris view of the normal left side as compared with the abnormal right side. Note the profound subtalar varus deformity of the right lower extremity. Both the distal tibial valgus deformity and the subtalar varus deformity must be corrected.



f0170 **FIGURE 22-17** **A**, CT scan of the 88-year-old woman shown in Figure 20-8A shows that this fracture is healed. **B**, CT scan of the 49-year-old man shown in Figure 20-8B shows that this fracture has gone on to nonunion.



needed to assist in the care of the patient with a nonunion. The consultants participate in the initial evaluation and throughout the course of treatment.

p0840 A plastic reconstructive surgeon may be consulted preoperatively to assess the status of the soft tissues, particularly when the need for coverage is anticipated following serial débridement of an infected nonunion. Consultation with a vascular surgeon may be necessary if the viability (vascularity) of the limb is in question.

p0850 An infectious disease specialist can prescribe an antibiotic regimen preoperatively, intraoperatively, and postoperatively, particularly for the patient with a long-standing, infected nonunion.

p0860 Many patients with nonunions have dependency on oral narcotic pain medication. Referral to a pain management specialist is helpful both during the course of treatment and ultimately in detoxifying and weaning the patient off all narcotic pain medications.^{111,286,309}

p0870 Depression is common in patients with chronic medical conditions.^{79,155,156,170} Patients with nonunions often have signs of clinical depression. Referral to a psychiatrist for treatment can be of great benefit.

p0880 A neurologist should evaluate patients with motor or sensory dysfunction. Electromyography and nerve conduction studies can document the location and extent of neural compromise and determine the need for nerve exploration and repair.

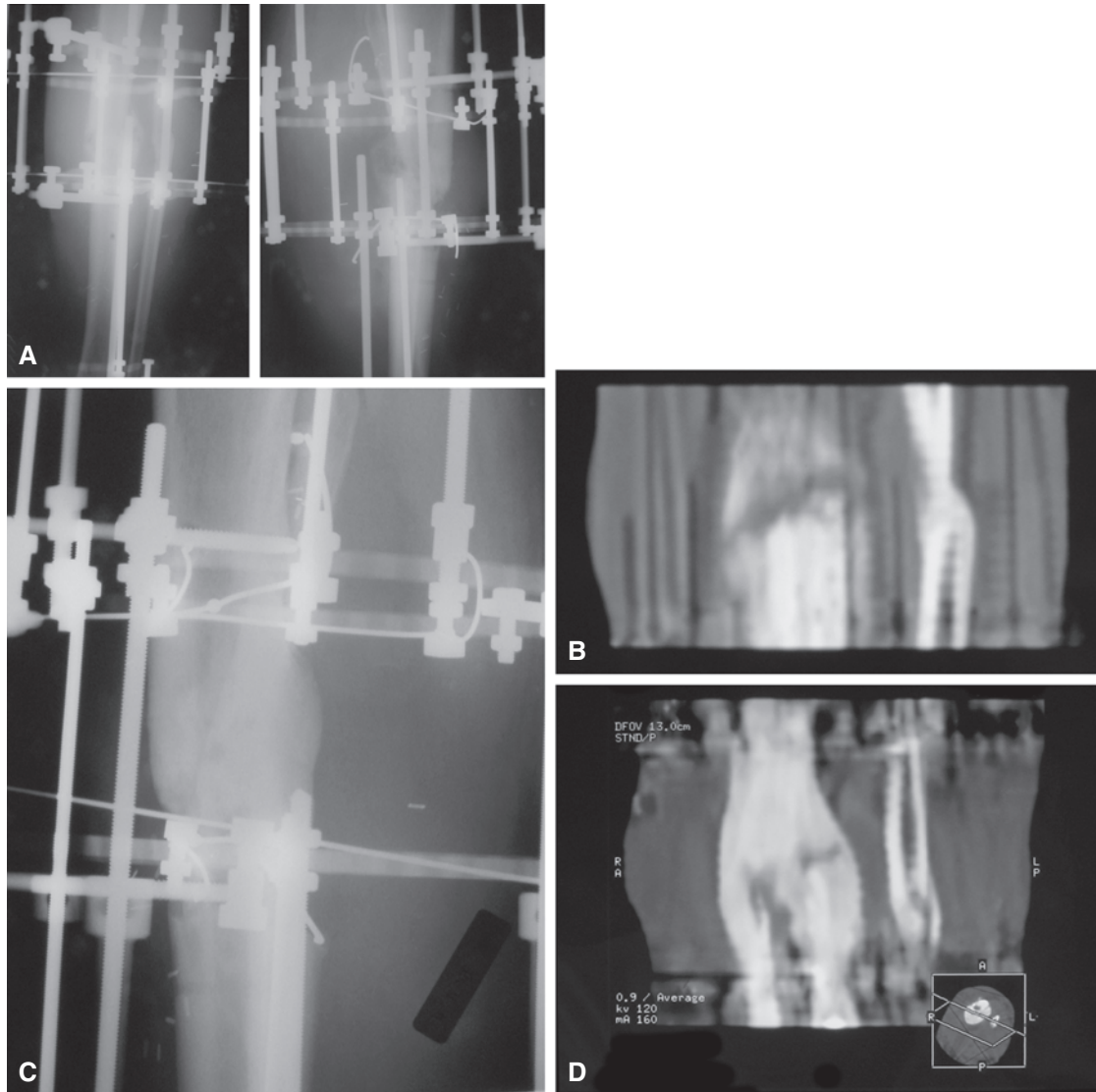
A physical therapist should be consulted for preoperative and postoperative training with respect to postoperative activity expectations and the use of assistive or adaptive devices. The goals of immediate postoperative (inpatient) rehabilitation include independent transfer and ambulation, when possible. Outpatient physical therapy primarily addresses strength and range of motion of the surrounding joints but may also include sterile or medicated whirlpool treatments to treat or prevent minor infections (e.g., pin site irritation in patients treated with external fixation).^{p0890}

Occupational therapy is useful for activities of daily living and job-related tasks, particularly those involving fine motor skills such as grooming, dressing, and use of hand tools. Occupational therapy may also provide adaptive devices for activities of daily living during nonunion treatment.^{p0900}

A nutritionist may be consulted for patients who are malnourished or obese. Poor dietary intake of protein (albumin) or vitamins may contribute to delayed fracture union and nonunion.^{73;88-90,117,242,303} A nutritionist may also counsel severely obese patients to reduce body weight. Obesity increases the technical demands of nonunion treatment, and a higher complication rate should be anticipated.¹⁵²^{p0910}

Anesthesiologists and internists should be consulted for the elderly or patients with serious medical conditions.^{p0920}

f0180 **FIGURE 22-18** *In addition to helping determine whether a fracture has united or has gone on to nonunion, CT scans are a useful method for estimating the cross-sectional area of healing. In this case of an infected mid-shaft tibial nonunion, CT scanning is a useful method of estimating the progression of the cross-sectional area of healing over time. **A**, Radiograph of the tibia 4 months following injury. It is difficult to definitively say whether this fracture is healing. **B**, CT scan shows a clear gap without bony contact or bridging bone (0% cross-sectional area of healing). **C**, Radiograph 6 months later following gradual compression across the nonunion site. **D**, CT scan shows solid bony union (cross-sectional area of healing >50% in this case).*



Preoperative planning of special anesthetic and medical needs diminishes the likelihood of intraoperative and postoperative medical complications.

s0320 **TREATMENT**

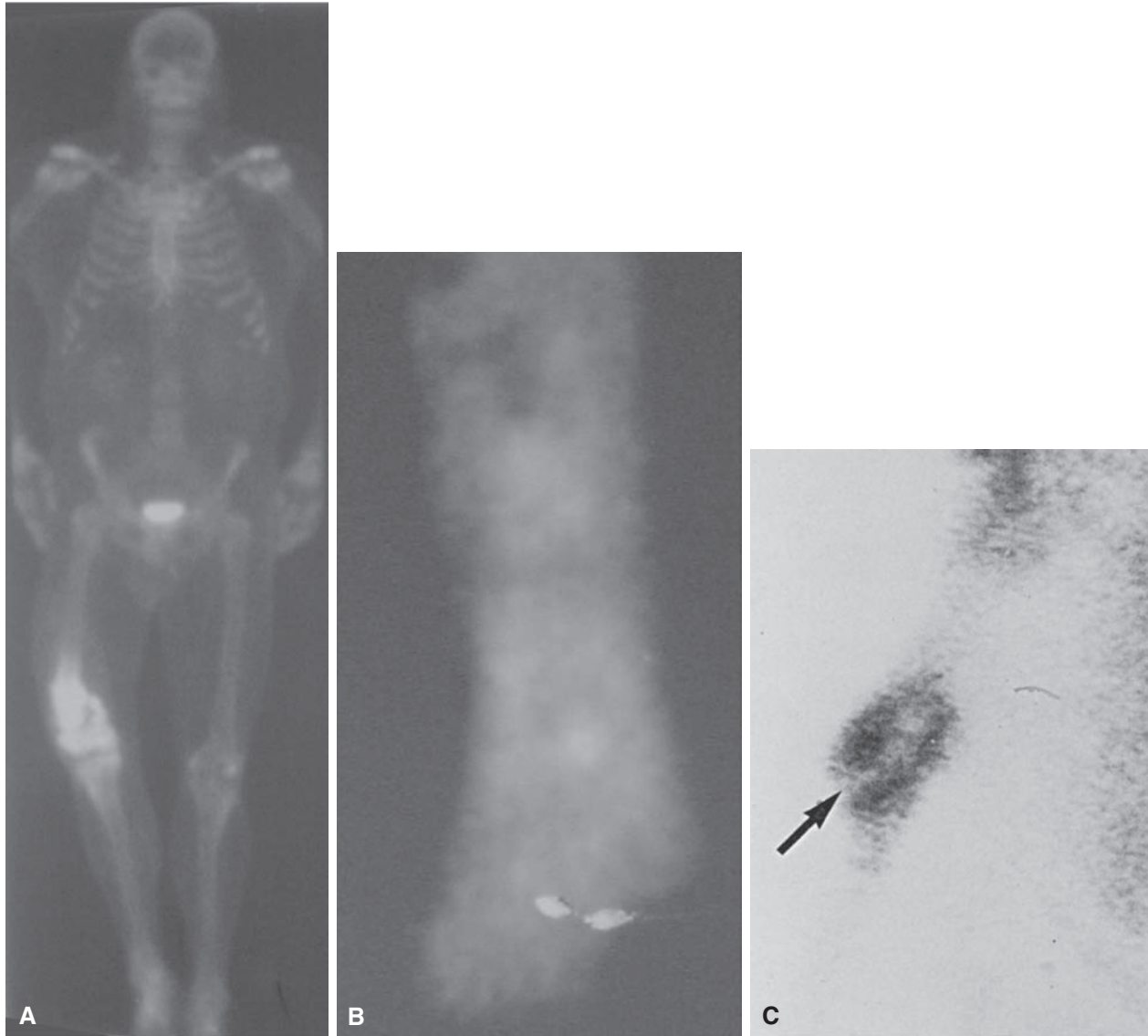
s0330 **Objectives**

p0930 Obviously, treatment is directed at healing the fracture. This, however, is not the only objective, since a nonfunctional, infected, deformed limb with pain and stiffness of the adjacent joints will be an unsatisfactory outcome for most patients even if the bone heals solidly. Emphasis is thus placed on returning the extremity and the patient to the fullest function possible during and after the treatment process.

Treating a nonunion can be likened to playing a game p0940 of chess; it is difficult to predict the course until the process is under way. Some nonunions heal rapidly with a single intervention. Others require multiple surgeries. Unfortunately, the most benign-appearing nonunion occasionally mounts a terrific battle against healing. The treatment must therefore be planned so that each step anticipates the possibility of failure and allows for further treatment options.

The patient's motivation, disability, social problems, p0950 legal involvements, mental status, and desires should be considered before treatment begins. Are the patient's expectations realistic? Informed consent prior to any treatment is essential. The patient needs to understand the

f0190 **FIGURE 22-19** Technetium bone scanning of 3 different cases showing a viable nonunion (A), a nonviable nonunion (B), and a synovial pseudarthrosis (C).



uncertainties of nonunion healing, time course of treatment, and number of surgeries required. No guarantees or warranties should be given to the patient. If the patient is unable to tolerate a potentially lengthy treatment course or the uncertainties associated with the treatment and outcome, the option of amputation should be discussed. While amputation has obvious drawbacks, it does resolve the medical problem rapidly and may therefore be preferred by certain patients.^{29,57,132,276,306} It is unwise to talk a patient into or out of any treatment, particularly amputation.

p0960 When feasible, eradication of infection and correction of unacceptable deformities are performed at the time of nonunion treatment. When this is not practical or possible, the treatment plan is broken up into stages. The priorities of treatment are to

- o0010 1. Heal the bone.
- o0020 2. Eradicate infection.

- 3. Correct deformities. o0030
- 4. Maximize joint motion and muscle strength. o0040

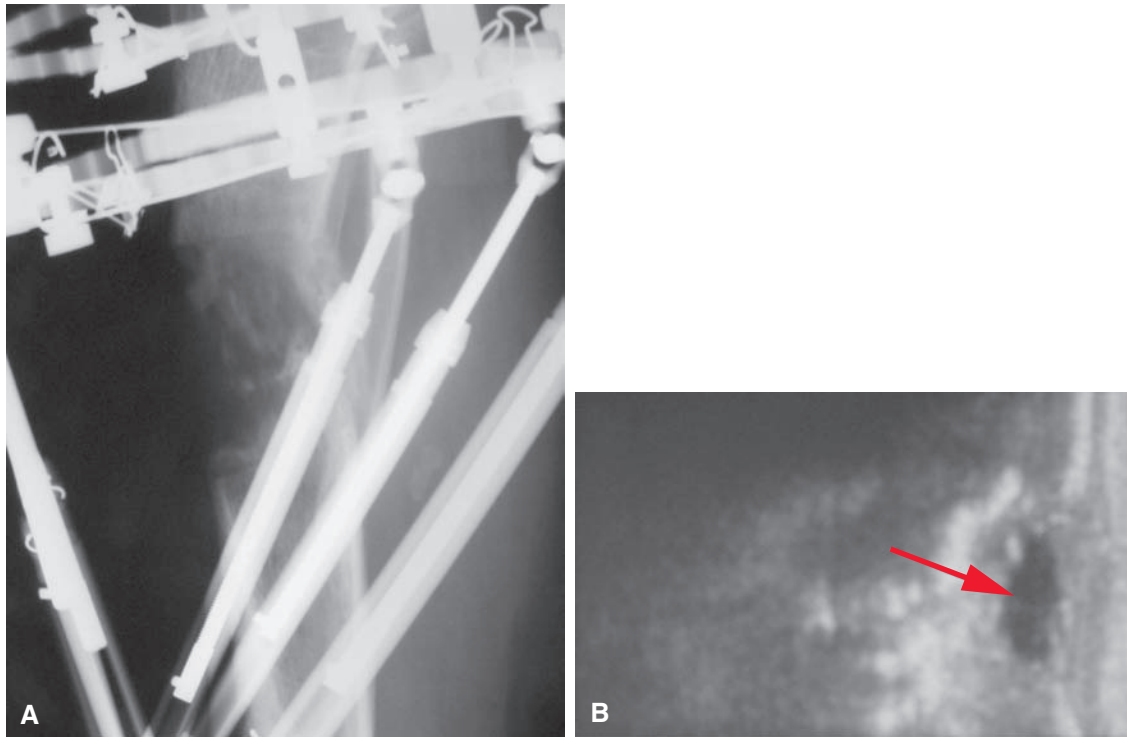
These priorities do not necessarily denote the temporal sequencing of surgical procedures. For example, in an infected nonunion with a deformity, the first priority is to heal the bone. The treatment, however, may begin with débridement in an effort to eliminate infection, but the overriding priority remains to heal the bone. p0970

Strategies s0340

The in-depth evaluation using the history and physical examination, radiologic examinations, laboratory studies, and consulting physicians provides for assessment of the overall situation. This assessment culminates in a treatment strategy specific to the patient's particular circumstances. p0980

The choice of treatment strategy is based on accurate classification of the nonunion (Table 22-4). Classification p0990

FIGURE 22-20 **A**, Radiograph of a slowly maturing proximal tibial regenerate. **B**, Ultrasonography shows a fluid-filled cyst (arrow).



10040

Table 22-4

Nonunion Types and Their Characteristics

Nonunion Type	Physical Examination	Plain Radiographs	Nuclear Imaging	Laboratory Studies
Hypertrophic	Typically does not display gross motion; pain elicited on manual stress testing	Abundant callus formation; radiolucent line (unmineralized fibrocartilage) at the nonunion site	Increased uptake at the nonunion site on technetium bone scan	Unremarkable
Oligotrophic	Variable (depends on the stability of the current hardware)	Little or no callus formation; diastasis at the fracture site	Increased uptake at the bone surfaces at the nonunion site on technetium bone scan	Unremarkable
Atrophic	Variable (depends on the stability of the current hardware)	Bony surfaces partially resorbed; no callus formation; osteopenia; sclerotic avascular bone segments; segmental bone loss	Avascular segments appear cold (decreased uptake) on technetium bone scan.	Unremarkable
Infected	Depends on the specific nature of the infection: Active purulent drainage Active nondraining—no drainage but the area is warm, erythematous, and painful Quiescent—no drainage or local signs or symptoms of infection	Osteolysis; osteopenia; sclerotic avascular bone segments; segmental bone loss	Increased uptake on technetium bone scan; increased uptake on indium scan for acute infections; increased uptake on gallium scan for chronic infections	Elevated erythrocyte sedimentation rate and C-reactive protein; white blood cell count may be elevated in more severe and acute cases; blood cultures should be obtained in febrile patients; aspiration of fluid from the nonunion site may be useful in the workup for infection
Synovial pseudarthrosis	Variable	Variable appearance (hypertrophic, oligotrophic, or atrophic)	Technetium bone scan shows a “cold cleft” at the nonunion site surrounded by increased uptake at the ends of the united bone.	Unremarkable

is based on the nonunion type and 13 treatment modifiers (Table 22-5).

s0350 **Nonunion Type**

p1000 The primary consideration for designing the treatment strategy is nonunion type (Fig. 22-21). Categorizing the nonunion identifies the mechanical and biological requirements of fracture healing that have not been met. The surgeon can then design a strategy to meet the healing requirements.

s0360 **HYPERTROPHIC NONUNIONS**

p1010 Hypertrophic nonunions are viable, possess an adequate blood supply,²⁵² and display abundant callus formation²⁰⁷ but lack mechanical stability. Providing mechanical stability to a hypertrophic nonunion results in chondrocyte-mediated mineralization of fibrocartilage at

the interfragmentary gap (Fig. 22-22). Mineralization of fibrocartilage may occur as early as 6 weeks following rigid stabilization and is accompanied by vascular ingrowth into the mineralized fibrocartilage^{207,290} (see Fig. 22-22). By 8 weeks following stabilization, there is resorption of calcified fibrocartilage, which is then arranged in columns and acts as a template for deposition of woven bone. Woven bone is subsequently remodeled into mature lamellar bone (see Fig. 22-22).²⁹⁰

Hypertrophic nonunions require no bone grafting.^{68,142,207,208,268,270,273,275,327-329} The nonunion site tissue should not be resected. Hypertrophic nonunions simply need a little “push” in the right direction (Fig. 22-23). If the method of rigid stabilization involves exposing the nonunion site (e.g., compression plate stabilization), decortication of the nonunion site may accelerate the consolidation of bone. If the method of rigid stabilization does not involve exposure of the nonunion

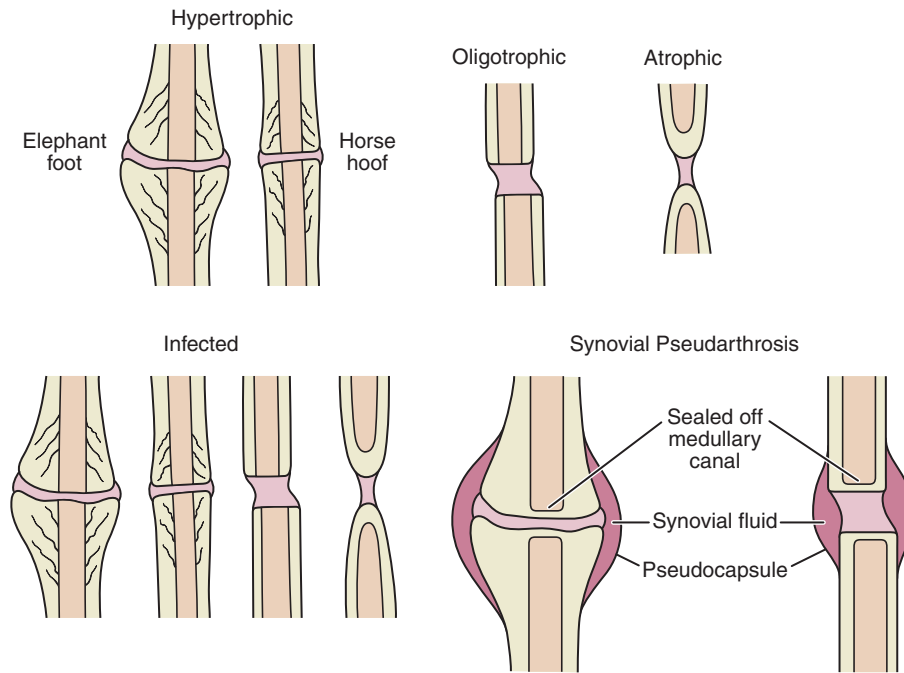
t0050

Table 22-5

Treatment Strategies for Nonunions Based on Classification

Classification	Treatment Strategy	
	Biological	Mechanical
Primary Consideration (Nonunion Type)		
Hypertrophic		Augment stability
Oligotrophic	Bone grafting for cases that have poor surface characteristics and no callus formation	Improve reduction (bone contact)
Atrophic	Biological stimulation via bone grafting or bone transport	Augment stability, compression
Infected Draining, active Nondraining, active Nondraining, quiescent	Débridement, antibiotic beads, dead space management, systemic antibiotic therapy, biological stimulation for bone healing (bone grafting or bone transport)	Provide mechanical stability, compression
Synovial pseudarthrosis	Resect synovium and pseudarthrosis tissue, open medullary canals with drilling and reaming, bone grafting	Compression
Treatment Modifiers		
Anatomic location Epiphyseal Metaphyseal Diaphyseal	Treatment modifiers are described in the text.	
Segmental bone defects		
Prior failed treatments		
Deformities Length Angulation Rotation Translation		
Surface characteristics		
Pain and function		
Osteopenia		
Mobility of the nonunion Stiff Lax		
Status of hardware		
Motor/sensory dysfunction		
Patient’s health and age		
Problems at adjacent joints		
Soft tissue problems		

f0210 **FIGURE 22-21** Classification of nonunions (nonunion types).



site (e.g., intramedullary nail fixation or external fixation), surgical dissection to prepare the nonunion site is unnecessary.

s0370 **OLIGOTROPHIC NONUNIONS**

p1030 Oligotrophic nonunions also are viable and possess an adequate blood supply but display little or no callus formation, typically as a result of inadequate reduction with little or no contact at the bony surfaces (Fig. 22-24). Therefore, treatment methods for oligotrophic nonunions include reduction of the bony fragments to improve bone contact, bone grafting to stimulate the local biology, or a combination of the two. Reduction of the bony fragments to improve bony contact can be performed with either internal or external fixation. Reduction is appropriate for oligotrophic nonunions with large surface areas without comminution across which compression can be applied. Bone grafting is appropriate for oligotrophic nonunions that have poor surface characteristics and no callus formation.

s0380 **ATROPHIC NONUNIONS**

p1040 Atrophic nonunions are nonviable. Their blood supply is poor and they are incapable of purposeful biological activity (Fig. 22-25). While the primary problem is biological, the atrophic nonunion requires a treatment strategy that employs both biological and mechanical techniques. Biological stimulation is most commonly provided by autogenous cancellous graft laid onto a widely decorticated area at the nonunion site. Small free necrotic fragments are excised and the resulting defect is bridged with bone graft; treatment of large bony defects is discussed later in this chapter. Mechanical stability can be achieved using either internal or external fixation, and the fixation method must provide adequate purchase in poor quality (osteopenic) bone.

When stabilized and stimulated, an atrophic nonunion p1050 is revascularized slowly over the course of several months, as visualized radiographically by observing the progression of osteopenia as it moves through sclerotic, nonviable fragments.^{267,329}

No consensus exists regarding whether large segments p1060 of sclerotic bone should be excised from uninfected atrophic nonunions. Those who favor plate-and-screw fixation tend to leave large sclerotic fragments that revascularize over several months following rigid plate stabilization, decortication, and bone grafting. Those who favor other treatment methods tend to excise large sclerotic fragments and reconstruct the resulting segmental bony defect using one of several available methods. Both of these treatment strategies result in successful union in a high percentage of cases. Our decision largely depends on the treatment modifiers, discussed in the next section.

INFECTED NONUNIONS

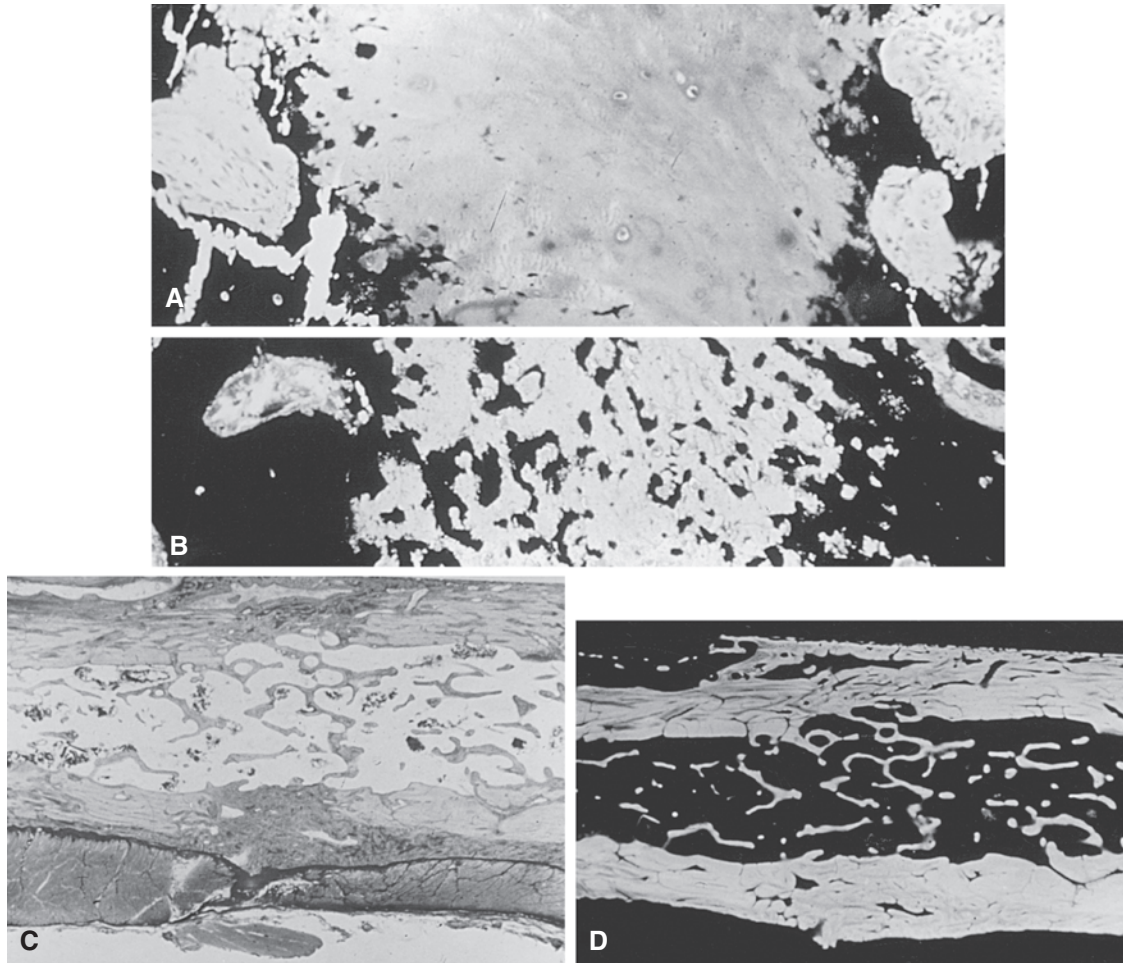
s0390 Infected nonunions pose a dual challenge. The condition p1070 is often further complicated by incapacitating pain (often with narcotic dependency), soft tissue problems, deformities, joint problems (contractures, deformities, limited range of motion), motor and sensory dysfunction, osteopenia, poor general health, depression, and a myriad of other problems. Infected nonunions are the most difficult type of nonunion to treat.

The goals are to obtain solid bony union, eradicate the p1080 infection, and maximize function of the extremity and the patient. Before a particular course of treatment is begun, the length of time required, the number of operative procedures anticipated, and the intensity of the treatment plan must be discussed with the patient and the family. The course of treatment for infected nonunions is especially difficult to predict. The possibility of persistent infection and nonunion despite

f0220

FIGURE 22-22

A, Photomicrograph of unmineralized fibrocartilage in a canine hypertrophic nonunion (von Kossa stain). **B**, Six weeks following plate stabilization, chondrocyte-mediated mineralization of fibrocartilage is observed in this hypertrophic nonunion. **C**, This will go on to form woven bone, and will ultimately remodel to compact cortical bone 16 to 24 weeks following stabilization (**D**). (From Schenk, R.K. History of fracture repair and nonunion. Bull Swiss ASIF, October, 1978).



appropriate treatment should be discussed, and the possibility of future amputation should be considered.

p1090 The treatment strategy depends on the nature of the infection (draining, nondraining-active, nondraining-quiescent)²⁷¹ and involves both a biological and a mechanical approach.

s0400p1100 **PURULENT, DRAINING INFECTION** When purulent drainage is ongoing, the nonunion takes longer and is more difficult to heal (Fig. 22-26). An actively draining infection requires serial débridement. The first débridement should include obtaining deep culture specimens, including soft tissues and bone. No perioperative antibiotics should be given at least 2 weeks prior to obtaining deep intraoperative culture specimens. All necrotic soft tissues (e.g., fascia, muscle, abscess cavities, and sinus tracts), necrotic bone, and foreign bodies (e.g., loose orthopaedic hardware, shrapnel) should be excised.^{147,233} The sinus tract should be sent

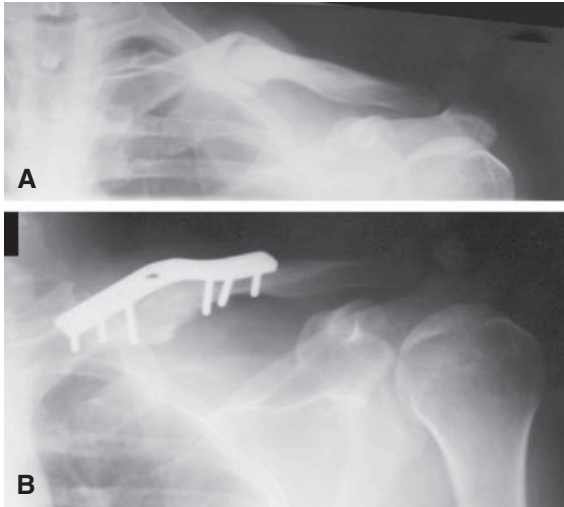
for pathologic study to rule out carcinoma.²³³ Pulsatile irrigation with antibiotic solution is effective in washing out the open cavity.

A dead space is commonly present following débridement. Initially, antibiotic-impregnated polymethylmethacrylate (PMMA) beads are inserted,²³³ and a bead exchange is performed at each serial débridement. The dead space can subsequently be managed in a number of ways. Currently, the most widely utilized method involves filling the dead space with a rotational vascularized muscle pedicle flap (e.g., gastrocnemius, soleus^{233,238}) or a microvascularized free flap (e.g., latissimus dorsi, rectus^{331,332}). Another method involves open wound care with moist dressings, as in the Papineau technique,²²⁶ until granulation occurs and skin grafting can be performed.

Bony defects present following débridement can be reconstructed using a variety of bone grafting techniques, as discussed in the section on Segmental Bone Defects.

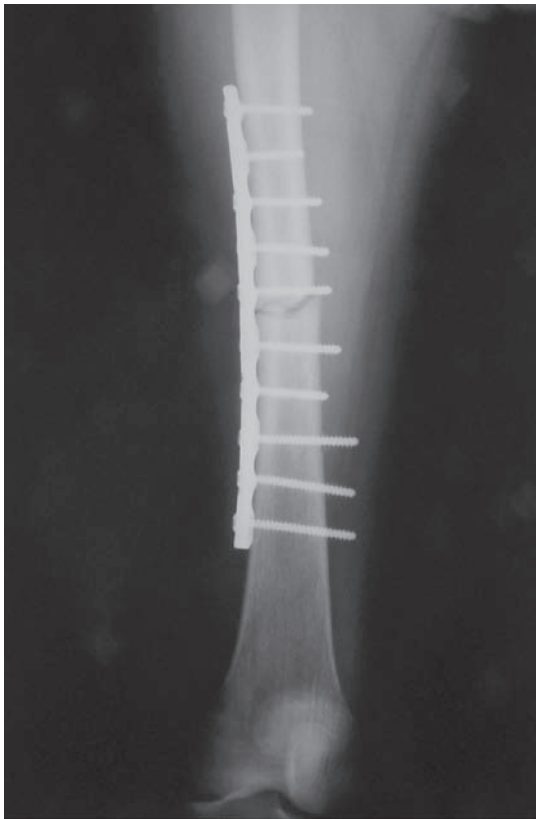
f0230

FIGURE 22-23 Plate-and-screw fixation of this hypertrophic clavicle nonunion led to rapid bony union. **A**, Radiograph shows a hypertrophic nonunion 8 months following injury. **B**, X-ray taken 15 weeks following open reduction internal fixation (without bone grafting) shows complete and solid bony union.



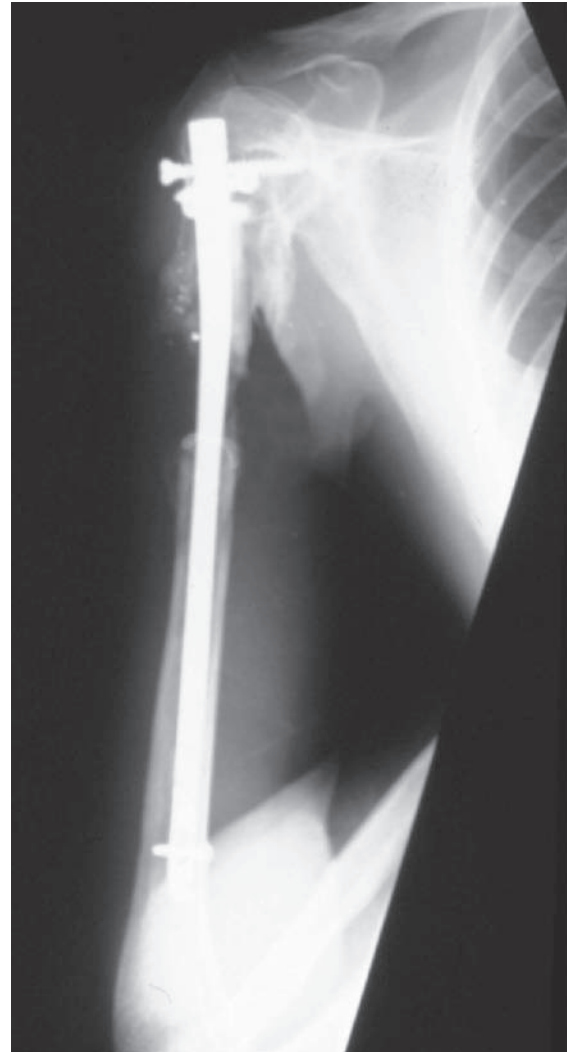
f0240

FIGURE 22-24 Oligotrophic nonunion of the femoral shaft 21 months following failed treatment of the initial fracture with plate and screw fixation. Note the absence of callus formation and poor contact at the bony surfaces.



f0250

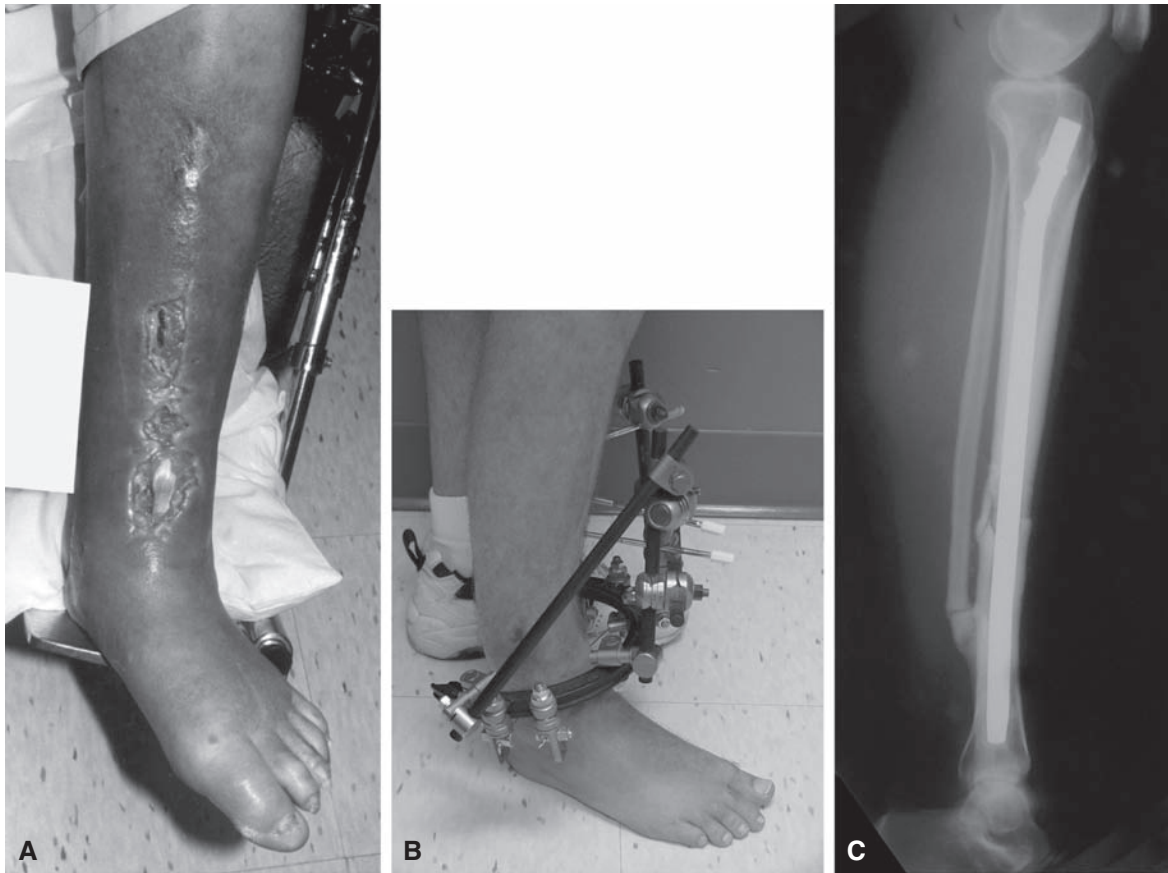
FIGURE 22-25 Atrophic nonunion of the proximal humerus. Note the lack of callus formation, the bony defect, and the avascular-appearing bony surfaces.



The consulting infectious disease specialist generally p1130 directs systemic antibiotic therapy. Following procurement of deep surgical cultures, the patient is placed on broad-spectrum intravenous antibiotics. When the culture results are available, antibiotic coverage is directed at the infecting organisms.

ACTIVE, NONDRAINING INFECTION Nondraining p1140 s0410 infected nonunions present with swelling, tenderness, and local erythema (see Fig. 22-26). The history often includes episodes of fever. Treatment principles are similar to those described for actively draining infected nonunions: débridement, intraoperative cultures, soft tissue management, stabilization, stimulation of bone healing, and systemic antibiotic therapy. These cases typically require incision and drainage of an abscess and excision of only small amounts of bone and soft tissues. Nondraining infected nonunion cases may be managed with primary

f0260 **FIGURE 22-26** **A**, Clinical photograph of an actively draining infected tibial nonunion. **B**, Clinical photograph of a nondraining infected tibial nonunion. Note the presence of local swelling (there is also erythema) without purulent drainage. **C**, Radiograph of a nondraining, quiescent, infected tibial nonunion (this patient had a history of multiple episodes of purulent drainage, and the gallium scan was positive).



closure following incision and drainage or with a closed suction-irrigation drainage system until the infection becomes quiescent.

s0420p1150 **QUIESCENT INFECTION** Nondraining quiescent infected nonunions occur in patients with a history of infection but without drainage or symptoms for 3 or more months²⁷¹ or without a history of infection but with a positive indium or gallium scan (see Fig. 22-26). These cases may be treated like atrophic nonunions. With plate-and-screw stabilization, the residual necrotic bone may be débrided at the time of surgical exposure. The bone is decorticated and stabilized, and bone grafting may also be performed. If external fixation is used, the infection and nonunion may be treated with compression without open débridement or bone grafting.²⁹⁴

s0430 **SYNOVIAL PSEUDARTHROSIS**

p1160 Synovial pseudarthroses are characterized by fluid bounded by sealed medullary canals and a fixed synovium-like pseudocapsule (Fig. 22-27). Treatment entails both biological stimulation and augmentation of mechanical stability. The synovium and pseudarthrosis

tissue are excised, and the medullary canals of the proximal and distal fragments are drilled and reamed. The ends of the major fragments are fashioned to allow for interfragmentary compression with either internal or external fixation. Bone grafting and decortication encourage more rapid healing.

According to Professor Ilizarov, gradual compression p1170 across a synovial pseudarthrosis results in local necrosis and inflammation, ultimately stimulating the healing process.^{143,294} We have had mixed results with this method and have found that resection at the nonunion followed by monofocal compression or bone transport more reliably achieves good results.

Treatment Modifiers

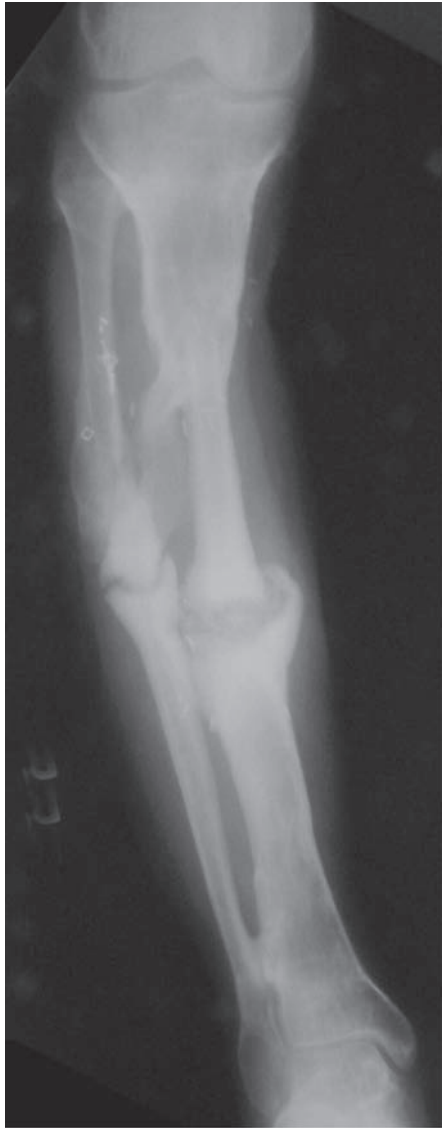The treatment modifiers (see Table 22-5) provide a more p1180 specific classification of the nonunion and thus help “fine-tune” the treatment plan.

ANATOMIC LOCATION

The bone involved and the specific region or regions (e.g., p1190 epiphysis, metaphysis, diaphysis) define the anatomic location of a nonunion. A bone-by-bone discussion is beyond

r0270

FIGURE 22-27 Plain radiographs of a tibial nonunion with a synovial pseudarthrosis.



the scope of this chapter; we address the influence of anatomic region on the treatment of nonunions in general terms.

s0460p1200

EPIPHYSEAL NONUNIONS Epiphyseal nonunions are relatively uncommon. The most common etiology is inadequate reduction that leaves a gap at the fracture site. These nonunions therefore commonly present with oligotrophic characteristics. The important considerations when evaluating epiphyseal nonunions are reduction of the intra-articular components (eliminate step-off at the articular surface), juxta-articular deformities (e.g., length, angulation, rotation, translation), motion at the joint (typically limited due to arthrofibrosis), and compensatory deformities at adjacent joints.

p1210

Epiphyseal nonunions are typically treated with interfragmentary compression using screw fixation, best

achieved by a cannulated lag screw technique (overdrilling a glide hole) with a washer beneath the screw head. Previously placed screws holding the nonunion site in a distracted position should be removed. Arthroscopy is a useful adjunctive treatment for epiphyseal nonunions (Fig. 22-28). The articular step-off can be evaluated and reduced under arthroscopic visualization, and the cannulated lag screws can be placed percutaneously using fluoroscopy. The intra-articular component of the nonunion may be freshened up using an arthroscopic burr if necessary (it is typically not). Arthroscopy also facilitates lysis of intra-articular adhesions to improve joint range of motion. Occasionally open reduction is required to reduce an intra-articular or juxta-articular deformity. In such cases, the surgical approach may include arthrotomy for lysis of adhesions.

METAPHYSEAL NONUNIONS Metaphyseal nonunions are relatively common. In general, the nonunion type determines the treatment strategy. Unstable metaphyseal nonunions may be treated with internal or external fixation. p1220 s0470

Plate-and-screw stabilization provides rigid fixation and is performed in conjunction with bone grafting, except for hypertrophic nonunions (Fig. 22-29). Screw fixation alone (without plating) should never be used for metaphyseal nonunions. p1230

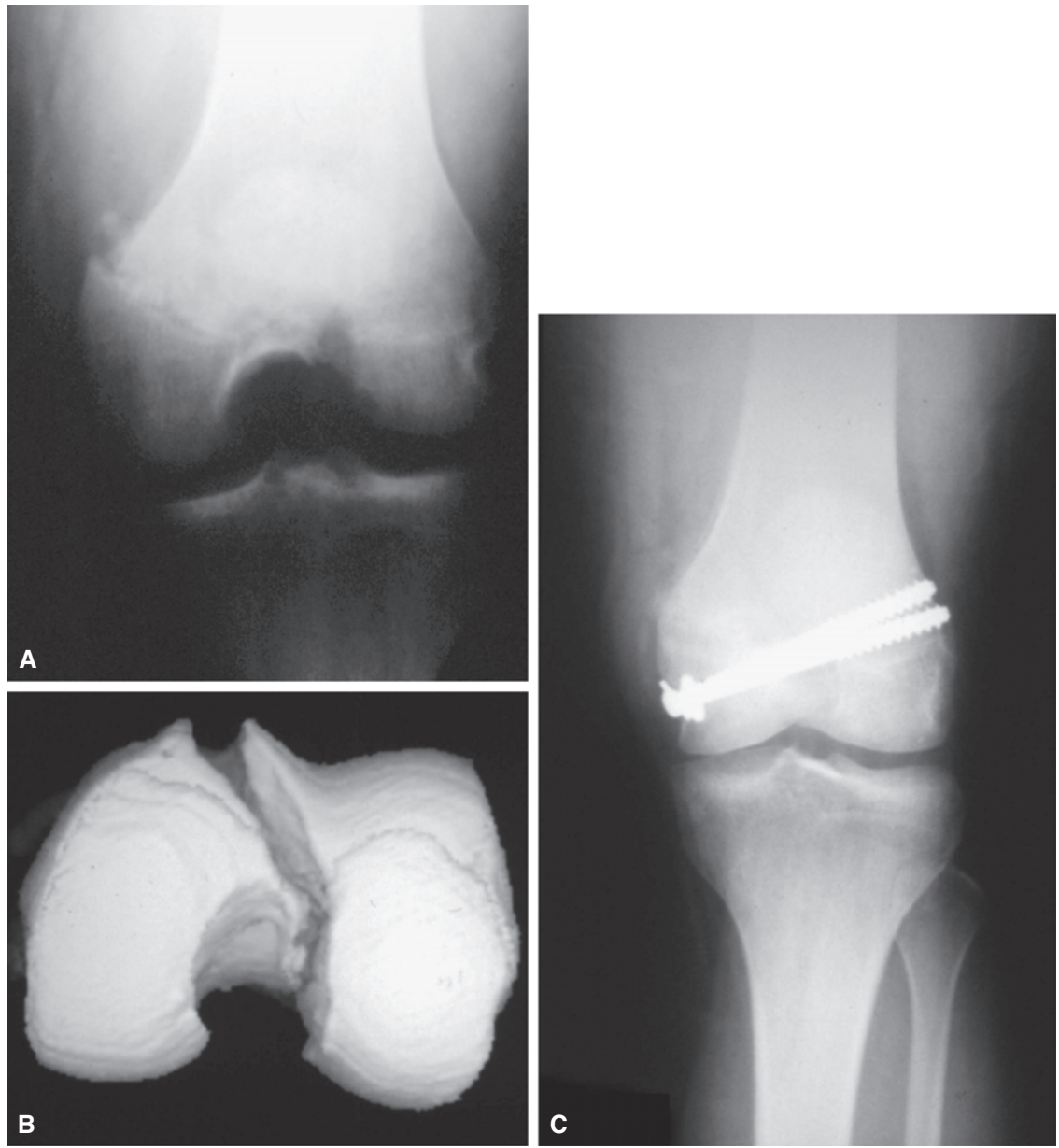
Intramedullary nail fixation is another option (see Fig. 22-29). Because the medullary canal is larger at the metaphysis than at the diaphysis, this method of fixation is predisposed to instability. Treatment of metaphyseal nonunions with nail fixation therefore requires good bone-to-bone contact at the nonunion site, a minimum of two interlocking screws in the short segment (custom-designed nails can provide for multiple interlocking screws), placement of blocking (Poller) screws^{168,169} to provide added stability (see Fig. 22-29), and intraoperative manual stress testing under fluoroscopy to ensure stable fixation. p1240

External fixation may also be used to treat metaphyseal nonunions. Ilizarov external fixation is the preferred method because it offers not only enhanced stability and early weight-bearing (for lower extremity nonunions) but also gradual compression at the nonunion site (see Fig. 20-29). Metaphyseal nonunions are particularly well suited for thin-wire external fixation because of the predominance of cancellous bone. However, internal fixation is generally preferable to external fixation for nonunions in the proximal humeral and proximal femoral metaphyses because the proximity of the trunk makes Ilizarov frame application technically difficult. p1250

Stable metaphyseal nonunions are frequently oligotrophic and typically unite rapidly when stimulated by means of conventional cancellous bone grafting or a percutaneous bone marrow injection. While both methods have a high rate of success, percutaneous marrow injection provides the benefits of minimally invasive surgery.¹³¹ p1260

The special considerations for metaphyseal nonunions are similar to those for epiphyseal nonunions and include juxta-articular deformities, motion at the adjacent joint, and compensatory deformities at the adjacent joints. These issues are addressed in greater detail below. p1270

f0280 **FIGURE 22-28** Epiphyseal nonunion (oligotrophic) of the distal femur in an 18-year-old 5 months following injury. **A**, Preoperative radiograph. **B**, Preoperative CT scan. **C**, Final result following arthroscopically assisted closed reduction and percutaneous cannulated screw fixation shows solid bony union.



s0480p1280 **DIAPHYSEAL NONUNIONS** Diaphyseal nonunions traverse cortical bone and may be more resistant to union than metaphyseal and epiphyseal nonunions, which traverse primarily cancellous bone. By virtue of their more central location, however, diaphyseal nonunions are amenable to the widest array of fixation methods (Fig. 22-30).

s0490 p1290 **NONUNIONS THAT TRAVERSE MORE THAN ONE ANATOMIC REGION** Nonunions that traverse more than one anatomic region require a strategy plan for each region. In some cases, the treatment can be performed using the same strategy for each region, whereas in others several strategies must be used. For example, a nonunion of the proximal humeral metaphysis with

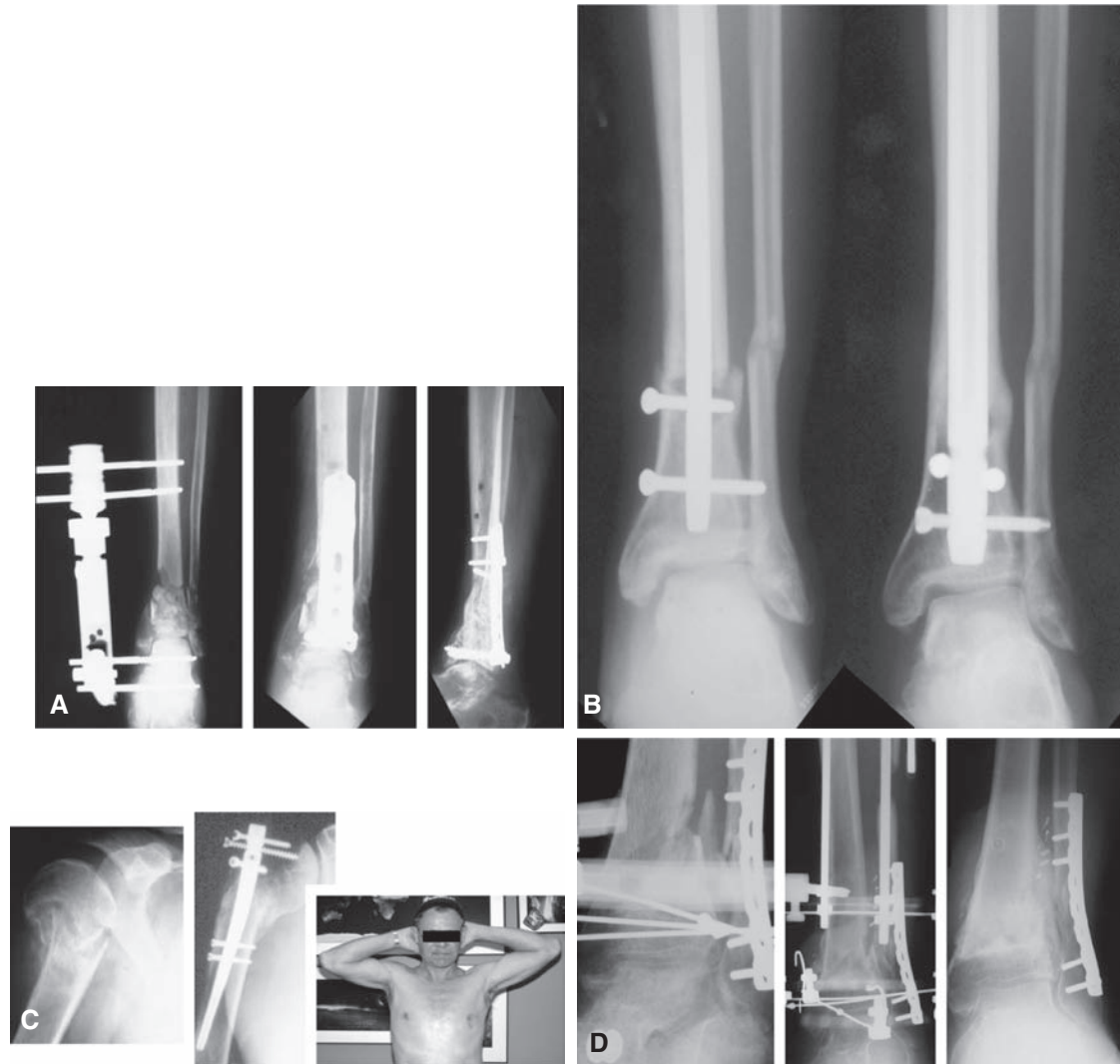
diaphyseal extension could be treated with a reamed intramedullary nail with proximal and distal interlocking screws. This single strategy provides mechanical stability and biological stimulation (reaming) to both nonunions. By contrast, a nonunion of the distal tibial epiphysis with extension into the metaphysis and diaphysis could be treated using several strategies: cannulated screw fixation of the epiphysis, percutaneous marrow injection of the metaphysis, and Ilizarov external fixation stabilizing all three anatomic regions.

SEGMENTAL BONE DEFECTS

s0500

Segmental bone defects associated with nonunions may be a result of high-energy open fractures with bone lost at the p1300

f0290 **FIGURE 22-29** *Metaphyseal nonunions can be treated with a variety of methods. **A**, Preoperative and final radiographs of an atrophic distal tibial nonunion treated with plate-and-screw fixation and autologous cancellous bone grafting. **B**, Preoperative and final radiographs of an oligotrophic distal tibial nonunion treated with exchange nailing. Note the use of Poller screws in the short distal fragment to enhance stability. **C**, Preoperative and final radiographs and final clinical photograph of a proximal metaphyseal humeral nonunion treated with intramedullary nail stabilization and autogenous bone grafting. **D**, Preoperative, during treatment, and final radiographs of a distal tibial nonunion treated using Ilizarov external fixation.*



accident, surgical débridement of devitalized bone fragments following a high-energy open fracture, surgical débridement of an infected nonunion, surgical excision of necrotic bone associated with an atrophic nonunion, or surgical trimming at a nonunion site to improve surface characteristics.

p1310 Segmental bone defects may have partial (incomplete) bone loss or circumferential (complete) bone loss (Fig. 22-31). Treatment methods for these defects fit into three broad categories: static, acute compression, and gradual compression.

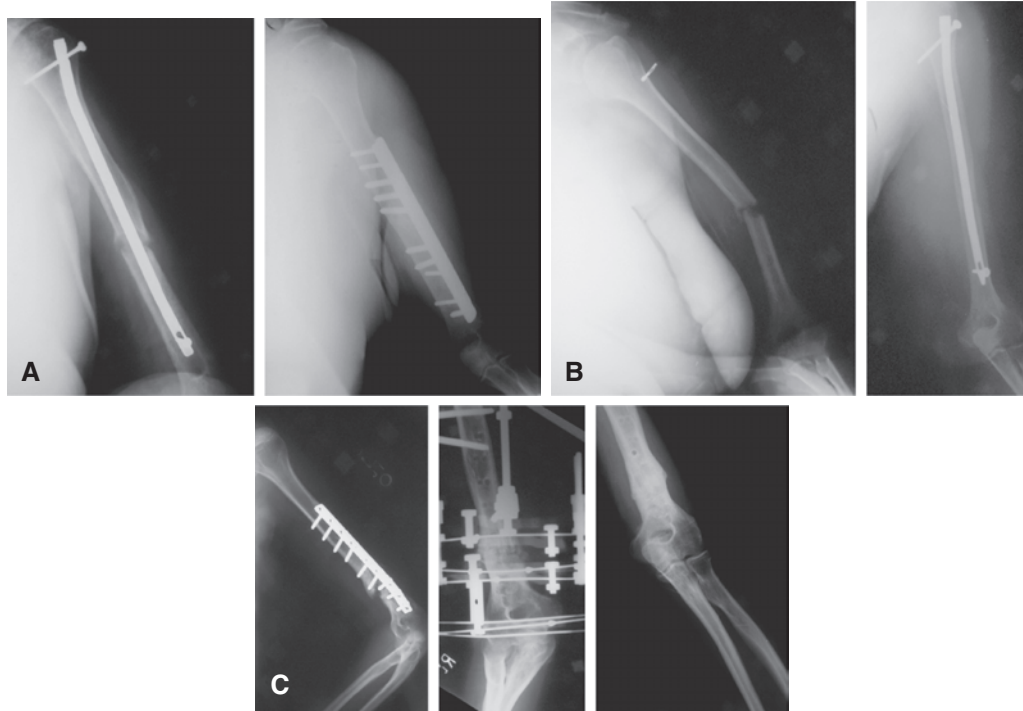
s0510p1320 **STATIC TREATMENT METHODS** Static treatment methods fill the defect between the bone ends. In static methods, the proximal and distal ends of the nonunion are fixed using internal or external fixation. Thus, it is important to ensure that the bone is not foreshortened or

overdistracted. Static methods for treating bone defects include autogenous cancellous bone graft, autogenous cortical bone graft, vascularized autograft, bulk cortical allograft, strut cortical allograft, mesh cage–bone graft constructs, and synostosis techniques.

Autogenous cancellous bone graft may be used to treat p1330 either partial or circumferential defects. The other methods are typically used to treat circumferential segmental defects. These methods are discussed in detail in the Treatment Methods section.

ACUTE COMPRESSION METHODS Acute compression methods obtain immediate bone-to-bone contact at the nonunion site by acutely shortening the extremity. Soft tissue compliance, surgical or open wounds, and neurovascular structures limit the extent of acute shortening that is possible. Some authors^{115,144,294} have suggested p1340 s0520

f0300 **FIGURE 22-30** Diaphyseal nonunions can be treated with a variety of methods. **A**, Preoperative and final radiographs of a left humeral shaft nonunion treated with plate and screw fixation and autologous cancellous bone grafting. **B**, Preoperative and final radiographs of a left humeral shaft nonunion treated with intramedullary nail fixation. **C**, Preoperative, during treatment, and final radiographs of an infected humeral shaft nonunion treated using Ilizarov external fixation.



that greater than 2 to 2.5 cm of acute shortening may lead to wound closure difficulties or kinking of blood vessels and lymphatic channels. In our experience, up to 4 to 5 cm of acute shortening is well tolerated in many patients (Fig. 22-32). Acute shortening is appropriate for defects up to 7 cm in length. Longitudinal incisions tend to bunch up when acute shortening is performed. An experienced plastic reconstructive surgeon is invaluable for the closure of these wounds. Transverse incisions are less difficult to

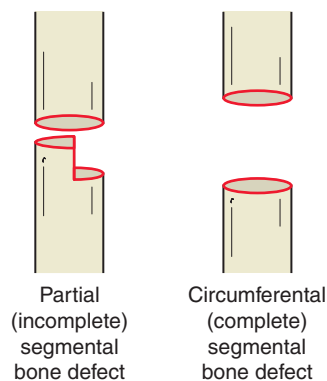
close because they bunch up less when acute shortening is performed.

In the leg and forearm, the unaffected bone (e.g., fibula) must be partially excised to allow for acute compression of the un-united bone (e.g., tibia). p1350

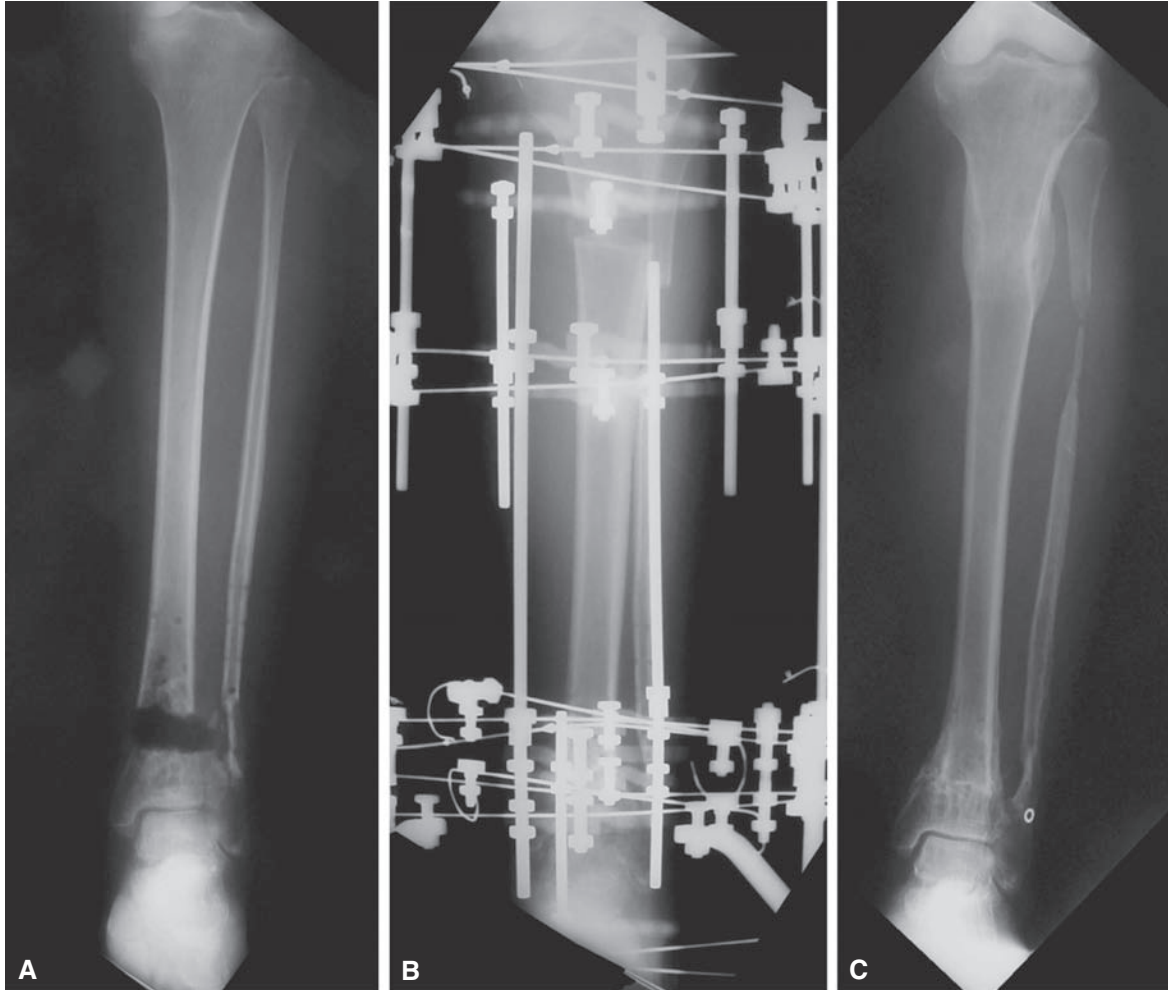
Acute compression methods provide immediate bone-to-bone contact and compression at the nonunion site, beginning the process of healing as early as possible. The bone ends should be fashioned to create opposing surfaces that are as parallel as possible. Flat cuts with an oscillating saw improve bone-to-bone contact but likely damage the bony tissues. Osteotomes, rasps, and rongeurs create less damage to the bony tissues but are less effective in creating flat cuts. No consensus exists regarding which method is best. We prefer to use a wide, flat oscillating saw and intermittent short bursts of cutting under constant irrigation. Acute compression with shortening also allows concomitant cancellous bone grafting of the decorticated bone at the nonunion site and promotes bony healing. p1360

A disadvantage of acute compression of segmental defects is the functional consequence of foreshortening the extremity. In the upper extremity, up to 3 to 4 cm of foreshortening is well tolerated. In the lower extremity, up to 2 cm of foreshortening may be treated with a shoe lift. Many patients poorly tolerate a shoe lift for 2 to 4 cm of shortening, and most do not tolerate greater than 4 cm of foreshortening. Therefore, many patients undergoing acute compression concurrently or subsequently undergo a lengthening procedure of the ipsilateral extremity or a foreshortening procedure of the contralateral extremity (see Fig. 22-32). p1370

f0310 **FIGURE 22-31** Segmental bone defects may be associated with either partial (incomplete) bone loss or circumferential (complete) bone loss.

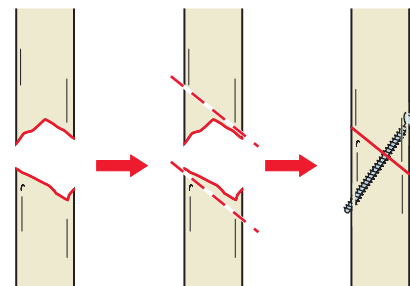


f0320 **FIGURE 22-32** **A**, Circumferential (complete) segmental bone defect in a 66-year-old woman with an infected distal tibial nonunion who was taking high-dose corticosteroids for severe rheumatoid arthritis. **B**, Radiograph during treatment following acute compression (2.5 cm) using an Ilizarov external fixator and bone grafting at the nonunion site. **C**, Final radiograph shows a healed distal tibial nonunion and restoration of length from concomitant lengthening at a proximal tibial corticotomy site.

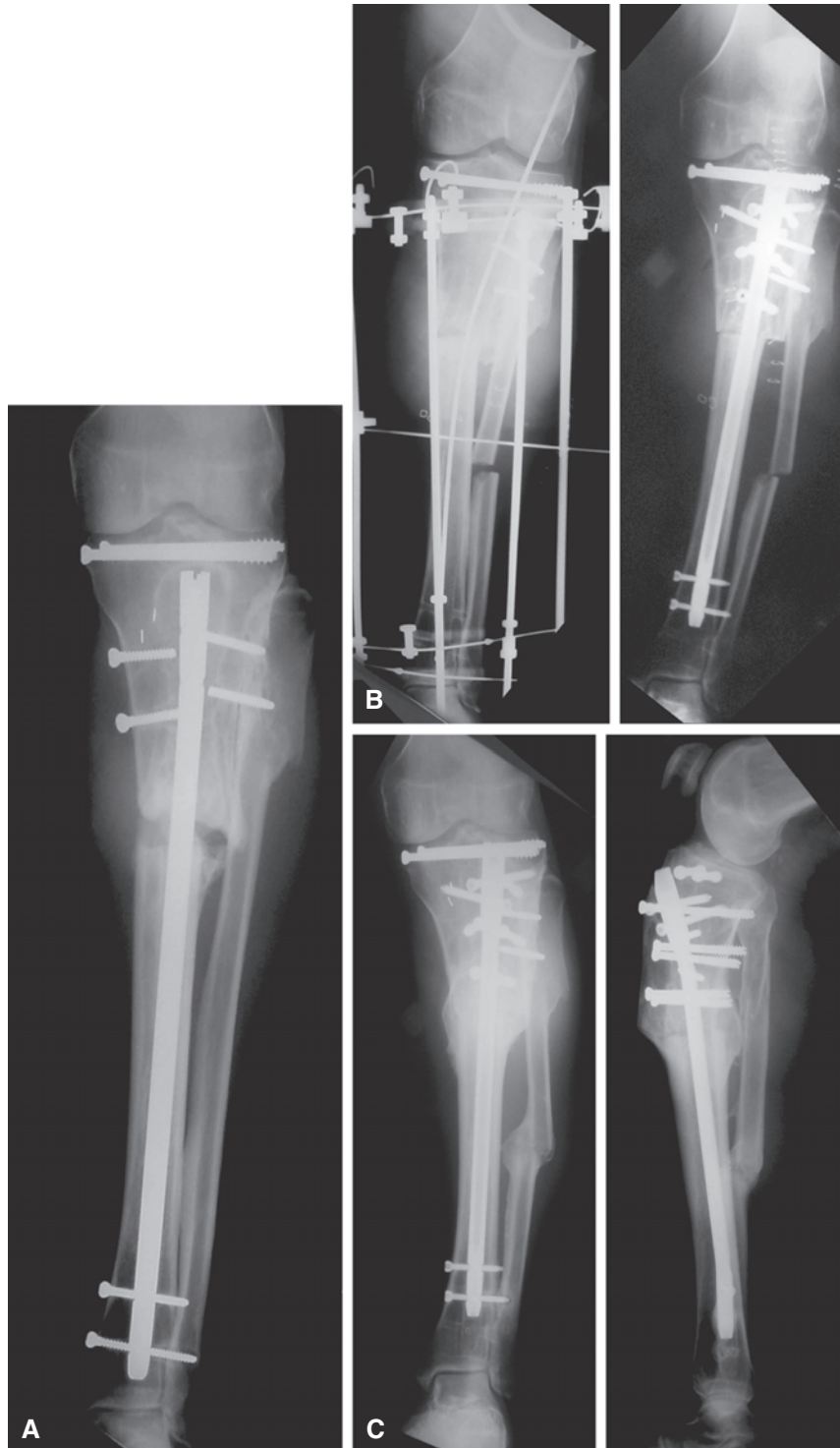

p1380 Acute compression across the nonunion site is typically used to treat circumferential segmental defects. When internal fixation devices are employed, acute compression is most effectively applied by the intraoperative use of a femoral distractor or a spanning external fixator. When plate-and-screw fixation is employed, an articulating tension device may be used to gain further interfragmentary compression. Dynamic compression plates (DCP; Synthes, Paoli, PA) may be used to provide further interfragmentary compression and rigid fixation. Oblique parallel flat cuts allow for enhanced interfragmentary compression via lag screw fixation (Fig. 22-33). With intramedullary nail fixation, acute compression across the segmental defect can also be applied intraoperatively by means of a femoral distractor or a spanning external fixator (Fig. 22-34). Compression can be applied using these temporary devices before or after

f0330 **FIGURE 22-33** Oblique, parallel flat cuts allow for enhanced interfragmentary compression via lag screw fixation when a segmental defect is treated with acute compression and plate stabilization.



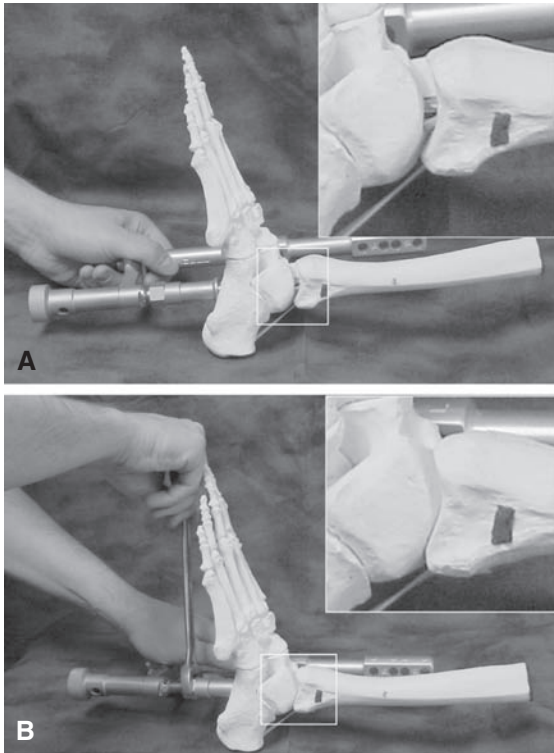
f0340 **FIGURE 22-34** Acute compression of a tibial nonunion with a segmental defect using a temporary (intraoperative use only) external fixator. Definitive fixation was achieved with an intramedullary nail. Note the use of Poller screws in the proximal fragment for enhanced stability. **A**, Radiograph on presentation. **B**, Intraoperative radiographs. **C**, Final result.



nail insertion but prior to static interlocking. In either case, the medullary canal should be over-reamed to at least 1.5 mm larger than the nail diameter. When the nail is placed after compression (shortening), over-reaming permits nail passage without distraction at the nonunion site. When the nail is placed before compression, over-reaming allows the proximal and distal fragments to slide over the nail and compress without jamming on the nail. Prior to removal of the intraoperative compression device, the nail must be statically locked both proximal and distal to the nonunion site. Some intramedullary devices, such as the Ankle Arthrodesis Nail (Biomet, Warsaw, IN), allow for acute compression across the fracture or nonunion site during the operative procedure (Fig. 22-35). In our experience, nails that allow for acute compression, when available, are preferable to conventional nails for this specific type of treatment.

p1390 Acute compression can also be applied by the use of an external fixator as the definitive mode of treatment. Transverse parallel flat cuts accommodate axial compression and minimize shear moments at the nonunion site.

f0350 **FIGURE 22-35** Some intramedullary nails allow for acute compression across a fracture site or a nonunion site. An example of such a nail is shown here. The Biomet Ankle Arthrodesis Nail (Warsaw, IN) is designed to allow for acute compression at the time of the operative procedure. **A**, Prior to compression. **B**, Acute compression being applied across the ankle joint using the compression device.



We favor the Ilizarov device when using external fixation for acute compression across a segmental defect. The Ilizarov frame can also be used for restoring length via corticotomy with lengthening at another site of the same bone (bifocal treatment).

GRADUAL COMPRESSION METHODS Gradual p1400 s0530 compression methods to treat a nonunion with a circumferential segmental defect include simple monofocal gradual compression (shortening) or bone transport. Both methods are most commonly accomplished via external fixation; again, we favor the Ilizarov device. Neither method is associated with the soft tissue and wound problems associated with acute compression. Monofocal compression and bone transport, however, are both associated with malalignment at the docking site, whereas acute compression is not.

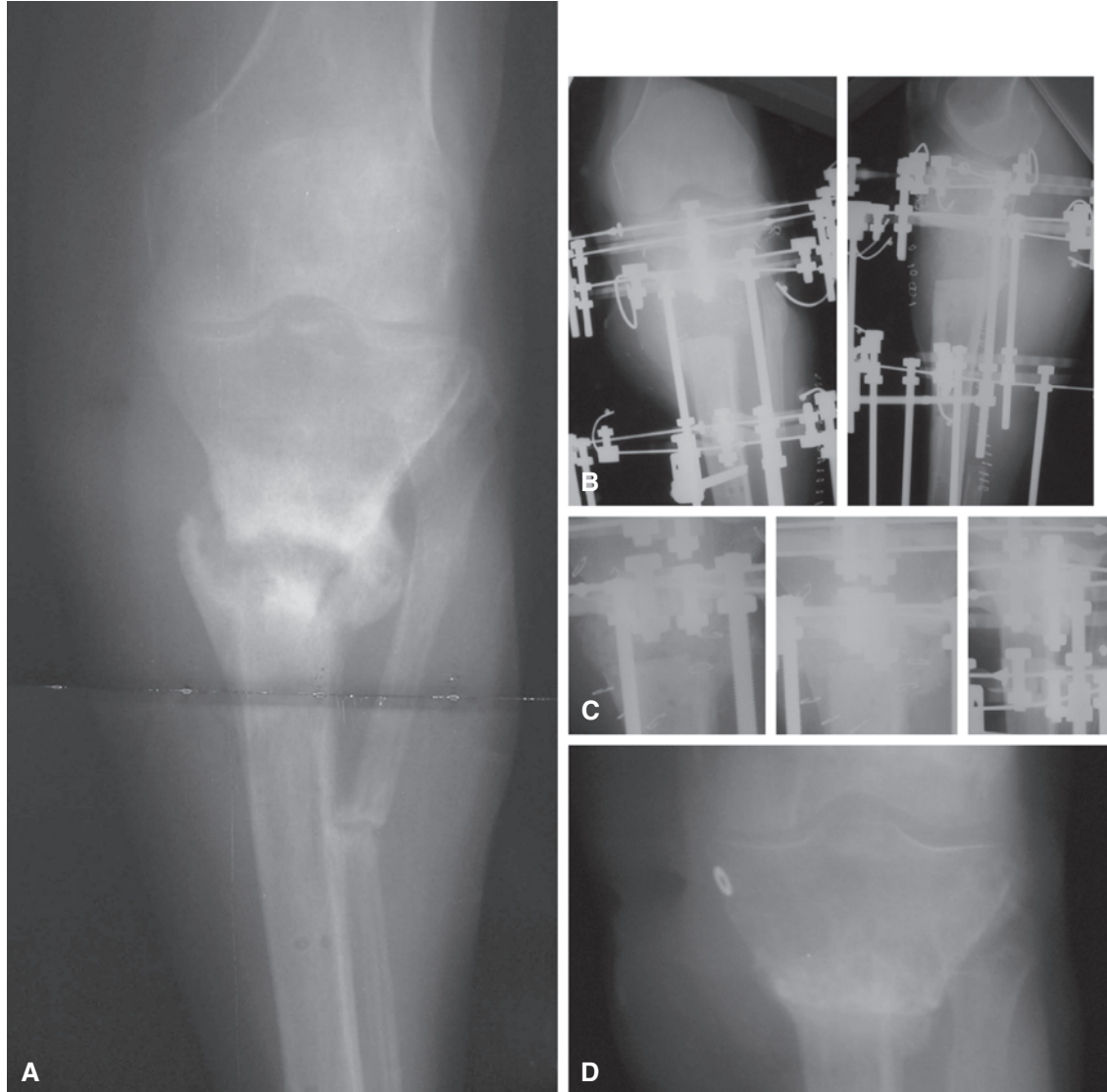For monofocal gradual compression, the external fixator p1410 frame is constructed to allow for compression in increments of 0.25 mm (Fig. 22-36). Slow compression at a rate of 0.25 mm to 1.0 mm per day is applied in one or four increments, respectively. When a large defect exists, compression is applied at a rate of 1.0 mm per day; at or near bony touchdown, the rate is slowed to 0.25 mm to 0.5 mm per day. Compression in limbs with paired bones requires partial excision of the intact, unaffected bone. Au5

For bone transport, the frame is constructed to allow a p1420 transport rate ranging from 0.25 mm every other day to 1.5 mm per day (Fig. 22-37). The transport is typically started at the rate of 0.5 mm to 0.75 mm per day in two or three increments, respectively. The rate can be increased or decreased based on the quality of the bony regenerate. Au6

When poor surface characteristics are present, open p1430 trimming of the nonunion site is recommended to improve the chances of rapid healing following docking. When trimming is performed during the initial procedure, the docking site can be bone-grafted if the anticipated time to docking is approximately 2 months or less (e.g., 6-cm defect compressed at a rate of 1.0 mm/day). If the time to docking will be significantly greater than 2 months (for larger defects), two options exist. First, gradual compression or transport can be continued at a rate ranging from 0.25 mm per week to 0.25 mm per day after bony touchdown is seen on plain radiographs. Continued compression at the docking site is seen clinically and radiographically as bending of the fixation wires, indicating that the rings are moving more than the proximal and distal bone fragments. Second, the docking site can be opened when the defect is approximately 1 to 2 cm to freshen the proximal and distal surfaces and bone-graft the defect. Gradual compression or transport then proceeds into the graft material.

In our experience, continued compression without open p1440 bone grafting and surface freshening leads to successful bony union in many patients. Others believe that bone-grafting the docking site significantly decreases the time to healing. The literature is not helpful in clarifying this issue. A useful alternative to open bone grafting is percutaneous marrow injection at the docking site. We use this

f0360 **FIGURE 22-36** Example of a nonunion treated with gradual monofocal compression. **A**, Presenting radiograph of a proximal tibial nonunion in a 79-year-old woman with a history of multiple failed procedures and chronic osteomyelitis. **B**, Intraoperative radiographs following bone excision shows a segmental defect. **C**, Radiographs showing gradual compression at the nonunion site over the course of several weeks. **D**, Radiograph showing final result with solid bony union.



technique in patients who have one or two “contributing factors” (see Table 22-2) and are thus at increased risk for persistent nonunion. We reserve open bone grafting of the docking site for one or more of the following scenarios: patients with no radiographic evidence of progression to healing despite 4 months of continued compression after bony touchdown, patients with three or more “contributing factors” for nonunion who are therefore at very high risk for persistent nonunion at the docking site, and patients who require trimming of the bone ends to improve contact at the docking site.

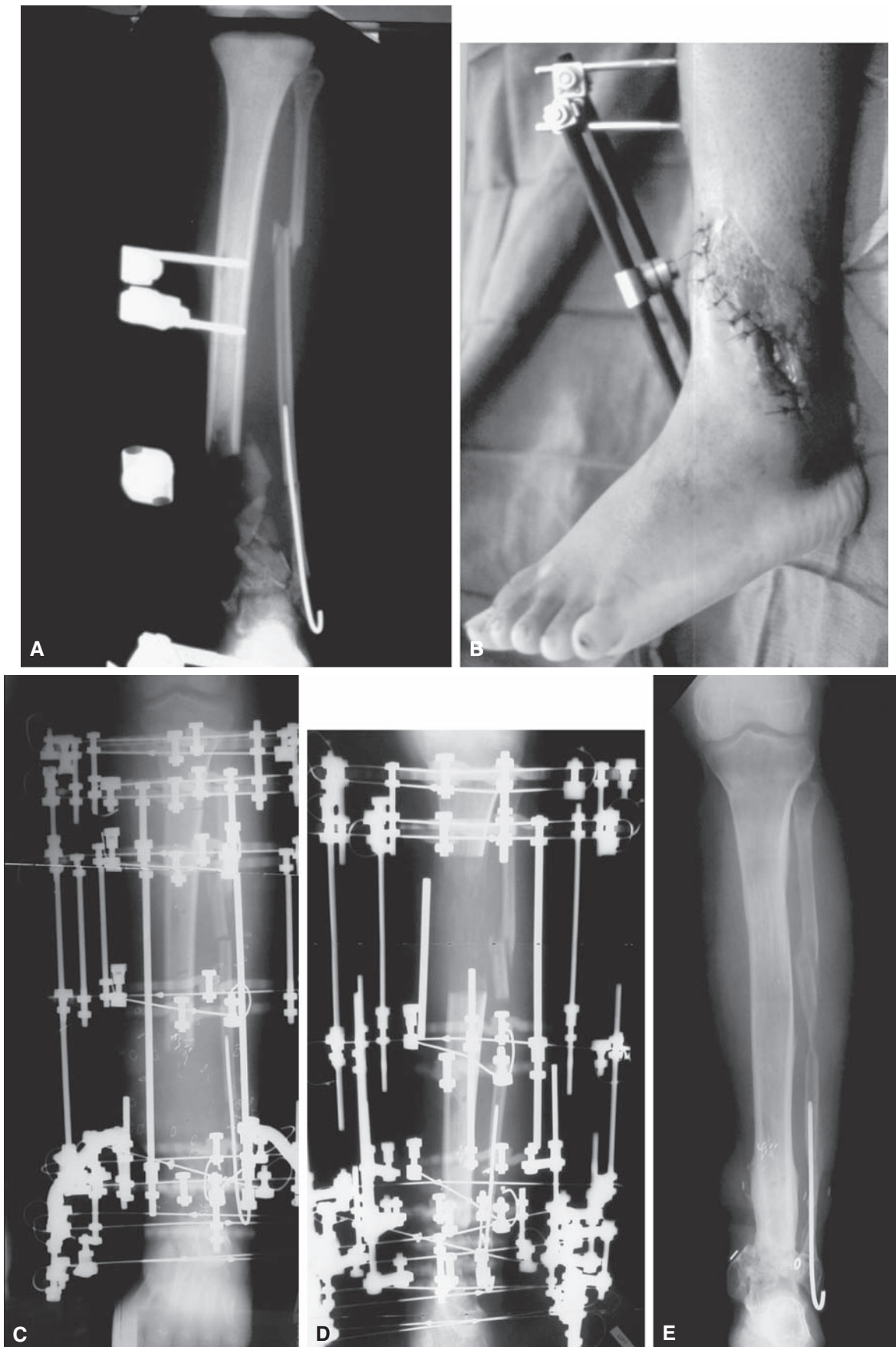
p1450 Nonunions with partial segmental defects are not amenable to many of the treatment strategies that have been

discussed. These defects are most commonly treated with a static method, such as autologous cancellous bone grafting and internal or external fixation. As the partial bone loss segment increases in length, the likelihood of bony union using conventional bone-grafting techniques decreases. In cases of nonunion with a large (>6 cm) segment of partial (incomplete) bone loss, the treatment options are “splinter (sliver) bone transport” (Fig. 22-38); surgical trimming of the bone ends to enhance surface characteristics, followed by an acute or gradual compression method; or strut cortical allogenic bone grafting.

The diverse nature of nonunions with segmental bone defects makes synthesis of the literature quite difficult. p1460

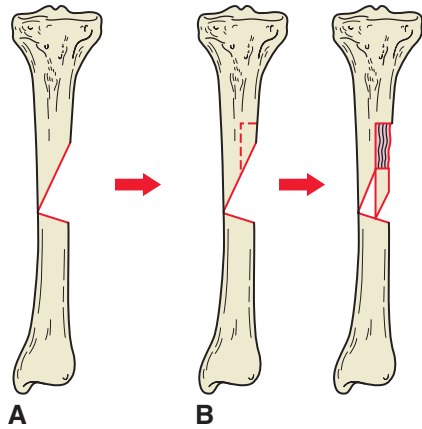
f0370

FIGURE 22-37 **A**, Radiograph on presentation 8 months after a high-energy open tibia fracture treated with an external fixator. **B**, Clinical photograph on presentation. **C** and **D**, Bone transport in progress at a rate of 1.0 mm per day (0.25 mm four times per day). **E**, Final radiographic result shows solid union at the docking site (slow, gradual compression without bone grafting resulted in solid bony union) with mature bony regenerate at the proximal corticotomy site.



f0380

FIGURE 22-38 **A**, Nonunion with a partial (incomplete) segmental defect. **B**, Splinter (sliver) bone transport can be used to span this defect.



A review of recommendations for treatment of complete segmental bone defects is shown in Table 22-6. Our preferred methods are shown in Table 22-7.

PRIOR FAILED TREATMENTS

s0540

The response of a nonunion (or lack thereof) to various treatment modalities will provide insight into its character. Why did the prior treatments fail? Were the treatments appropriate? Were there any technical problems with the treatments? Were there any positive biological responses to any prior treatment? Did mechanical instability contribute to the prior failures? Did any treatment improve the patient's pain and function?

p1470

A prior treatment that has provided no clinical or radiographic evidence of progression to healing should not be repeated unless the treating physician believes that technical improvements will lead to bony union. Repeating a prior failed procedure may also be considered if the prior procedure produced a measurable clinical or radiographic

p1480

t0060

Table 22-6

Review of Literature on Segmental Bone Defects

Author	Patient Population	Findings/Conclusions
May et al., 1989 ¹⁹⁰	Current Concepts review based on the authors' experience treating more than 250 patients with post-traumatic osteomyelitis of the tibia.	The authors' recommended treatment options for segmental bone defects are as follows: <i>Tibial defects 6 cm or less with an intact fibula</i> —open bone grafting vs. Ilizarov reconstruction <i>Tibial defects greater than 6 cm with an intact fibula</i> —tibiofibula synostosis techniques vs. free vascularized bone graft vs. nonvascularized autogenous cortical bone graft vs. cortical allograft vs. Ilizarov reconstruction <i>Tibial defects greater than 6 cm without a usable intact fibula</i> —contralateral vascularized fibula vs. Ilizarov reconstruction
Esterhai et al., 1990 ⁹⁵	42 patients with infected tibial nonunions and segmental defects. The average tibial defect was 2.5 cm (range, 0–10 cm); three treatment strategies were employed. All patients underwent débridement and stabilization and received parenteral antibiotics; following this protocol 23 underwent open cancellous bone grafting (Papineau technique), 10 underwent posterolateral bone grafting, and 9 underwent a soft tissue transfer prior to cancellous bone grafting.	Bony union rates for the three groups were as follows: Papineau technique = 49% Posterolateral bone grafting = 78% Soft tissue transfer = 70%
Ciorny and Zorn, 1994 ⁵⁵	44 patients with segmental infected tibial defects; 23 patients were treated with conventional methods (massive cancellous bone grafts, tissue transfers, and combinations of internal and external fixation); 21 patients were treated using the methods of Ilizarov.	The final results in the two treatment groups, were similar. The Ilizarov method was faster, safer in B-host (compromised) patients, less expensive, and easier to perform. Conventional therapy is recommended when any one distraction site is anticipated to exceed 6 cm in length in a patient with poor physiologic or support group status. When conditions permit either conventional or Ilizarov treatment methods, the authors recommend Ilizarov reconstruction for defects of 2 to 12 cm.
Green, 1994 ¹¹⁶	32 patients with segmental skeletal defects; 15 were treated with an open bone graft technique; 17 were treated with Ilizarov bone transport	The authors' recommendations are as follows: <i>Defects up to 5 cm</i> —cancellous bone grafting vs. bone transport <i>Defects greater than 5 cm</i> —bone transport vs. free composite tissue transfer
Marsh et al., 1994 ¹⁸⁵	25 infected tibial nonunions with segmental bone loss greater than or equal to 2.5 cm; 15 patients were treated with débridement, external fixation, bone grafting, and soft tissue coverage; 10 were treated with resection and bone transport using a monolateral external fixator	The two treatment groups were equivalent in terms of rate of healing, eradication of infection, treatment time, number of complications, total number of operative procedures, and angular deformities after treatment. Limb-length discrepancy was significantly less in the group treated with bone transport.

(Continued)

10060

Table 22-6

Review of Literature on Segmental Bone Defects—Cont'd

Author	Patient Population	Findings/Conclusions
Emami et al., 1995 ⁹¹	37 cases of infected nonunion of the tibial shaft treated with open cancellous bone grafting (Papineau technique) stabilized via external fixation; 15 nonunions had partial contact at the nonunion site, 22 had a complete segmental defect ranging from 1.5 to 3 cm in length.	All nonunions united at an average of 11 months following bone grafting. The authors recommend cancellous bone grafting for complete segmental defects up to 3 cm in length.
Patzakis et al., 1995 ²³²	32 patients with infected tibial nonunions with bone defects less than 3 cm; all were stabilized with external fixation and were grafted with autogenous iliac crest bone at a mean of 8 weeks following soft tissue coverage.	Union was reported in 91% of patients (29 of 32) at a mean of 5.5 months following the bone graft procedure; union was achieved in the remaining 3 patients following posterolateral bone grafting.
Moroni et al., 1997 ²⁰⁵	24 patients with nonunions with bone defects averaging 3.6 cm; 15 ulnar and 9 radial; all were treated with débridement, intercalary bone graft, and internal fixation with a cortical bone graft fixed opposite to a plate.	Union was reported in 96% of patients (23 of 24) at a mean of 3 months following surgery.
Polyzois et al., 1997 ²⁴³	42 patients with 25 tibial and 17 femoral nonunions with bone defects averaging 6 cm; 19 (45%) patients had an active infection, and 9 had a history of previous infection; all were treated with Ilizarov bone transport.	Union was reported in all patients (100%), although 4 (10%) patients required bone grafting of the docking site; all cases of infection resolved without further surgery; final leg length discrepancy was less than 1.5 cm in all cases.
Song et al., 1998 ³⁰⁴	27 patients with tibial bone defects averaging 8.3 cm; 13 (48%) patients had an active infection; all were treated with Ilizarov bone transport.	Union was reported in all patients (100%), although 25 (96%) patients required bone grafting of the docking site; all cases of infection resolved without further surgery.
Atkins et al., 1999 ¹⁵	5 patients with massive tibial bone defects; all were treated with Ilizarov transport of the fibula into the defect.	Union at the proximal and distal graft sites and hypertrophy of the graft was reported in all patients (100%).
McKee et al., 2002 ¹⁹⁵	25 patients with infected nonunions (15 tibia, 6 femur, 3 ulna, 1 humerus) and associated bone defects averaging 30.5 cm were treated with tobramycin-impregnated bone graft substitute (calcium sulfate alpha-hemihydrate pellets).	Union and elimination of infection was reported in 23 of 25 (92%) patients, although 9 (39%) patients required autogenous bone grafting; three (12%) patients had another fracture, infection recurred in two (8%) patients, and nonunion persisted in 2 (8%) patients.
Ring et al., 2004 ²⁵⁹	35 patients with nonunions of the forearm (11 ulna, 16 radius, 8 ulna and radius) with defects averaging 2.2 cm; 11 patients had a history of previous infection; all were treated with plate-and-screw fixation and autogenous cancellous bone grafting.	Union was reported in all patients (100%) within 6 months of surgery; 11 (31%) patients had unsatisfactory functional results due to elbow or wrist stiffness; one (3%) patient had a poor result owing to deformity following bony union.

improvement in the nonunion. For example, repeat exchange nailing of the femur can be effective in certain groups of patients¹²² but relatively ineffective in others.³³⁵ Those who heal following serial exchange nailings tend to show improvement following each successive procedure. Those whose nonunions persist tend to show little or no clinical and radiographic response after each nail exchange (Fig. 22-39).

p1490 The nonunion specialist must be part surgeon, part detective, and part historian. History has a way of repeating itself. Without a clear understanding and appreciation of why prior treatments have failed, the learning curve becomes a circle.

s0550 **DEFORMITIES**

p1500 The priority in patients who have a fracture nonunion with deformity is healing the bone. Healing the bone and correcting the deformity at the same time is not always possible. Will the effort to correct the deformity significantly

increase the risk of persistent nonunion? If so, then treatment is planned to first address the nonunion and later address the deformity (sequential approach). If not, then both problems are treated concurrently.

In our experience, the majority of nonunions with deformity benefit from the concurrent treatment approach. Deformity correction often improves bone contact at the nonunion site and thereby promotes bony union. Certain cases, however, are better treated with a sequential approach. The sequential approach is preferred if the deformity is unlikely to limit function after successful bony union, if adequate bony contact is best achieved by leaving the fragments in the deformed position, or if soft tissue restrictions make the concurrent approach too complex.

Deformity correction can be performed acutely or gradually. Acute correction is generally performed in lax nonunions, particularly those with a segmental bone defect. Acute correction allows the treating physician to focus on healing the bone, now without deformity.

t0070

Table 22-7

Authors' Recommendations for Treatment Options for Complete Segmental Bone Defects

Bone	Host	Segmental Defect	Recommended Treatment Options
Clavicle	Healthy or compromised	<1.5 cm	Cancellous autograft bone grafting; skeletal stabilization
Clavicle	Healthy or compromised	≥1.5 cm	Tricortical autogenous iliac crest bone grafting; skeletal stabilization
Humerus	Healthy	<3 cm	Cancellous autograft bone grafting vs. shortening; skeletal stabilization
Humerus	Healthy	≥3 cm	Bulk cortical allograft vs. vascularized cortical autograft vs. bone transport; skeletal stabilization
Humerus	Compromised	<3 cm	Cancellous autograft bone grafting vs. shortening; skeletal stabilization
Humerus	Compromised	3–6 cm	Bulk cortical allograft vs. vascularized cortical autograft vs. bone transport; skeletal stabilization
Humerus	Compromised	>6 cm	Bulk cortical allograft vs. vascularized cortical autograft; skeletal stabilization
Radius or ulna	Healthy	<3 cm	Cancellous autograft bone grafting vs. tricortical autogenous iliac crest bone grafting vs. shortening; skeletal stabilization
Radius or ulna	Healthy	≥3 cm	Bulk cortical allograft vs. vascularized cortical autograft vs. bone transport vs. synostosis; skeletal stabilization
Radius or ulna	Compromised	<3 cm	Cancellous autograft bone grafting vs. tricortical autogenous iliac crest bone grafting vs. shortening; skeletal stabilization
Radius or ulna	Compromised	3–6 cm	Bulk cortical allograft vs. vascularized cortical autograft vs. bone transport vs. synostosis; skeletal stabilization
Radius or ulna	Compromised	>6 cm	Bulk cortical allograft vs. vascularized cortical autograft vs. synostosis; skeletal stabilization
Femur	Healthy	<3 cm	Cancellous autograft bone grafting vs. bone transport vs. bifocal shortening and lengthening; skeletal stabilization
Femur	Healthy	3–6 cm	Bone transport vs. bifocal shortening and lengthening; skeletal stabilization
Femur	Healthy	6–15 cm	Bone transport vs. bulk cortical allograft; skeletal stabilization
Femur	Healthy	>15 cm	Bulk cortical allograft; skeletal stabilization
Femur	Compromised	<3 cm	Cancellous autograft bone grafting vs. bone transport vs. bifocal shortening and lengthening; skeletal stabilization
Femur	Compromised	3–6 cm	Bone transport vs. bifocal shortening and lengthening vs. bulk cortical allograft; skeletal stabilization
Femur	Compromised	>6 cm	Bulk cortical allograft with skeletal stabilization vs. bracing vs. amputation
Tibia	Healthy	<3 cm	Cancellous autograft bone grafting vs. bone transport vs. bifocal shortening and lengthening; skeletal stabilization
Tibia	Healthy	3–6 cm	Bone transport vs. bifocal shortening and lengthening; skeletal stabilization
Tibia	Healthy	6–15 cm	Bone transport vs. bulk cortical allograft; skeletal stabilization
Tibia	Healthy	>15 cm	Bone transport vs. bulk cortical allograft vs. synostosis; skeletal stabilization
Tibia	Compromised	<3 cm	Cancellous autograft bone grafting vs. bone transport vs. bifocal shortening and lengthening; skeletal stabilization
Tibia	Compromised	3–6 cm	Bone transport vs. bifocal shortening and lengthening; skeletal stabilization
Tibia	Compromised	6–15 cm	Bone transport vs. bulk cortical allograft vs. synostosis; skeletal stabilization
Tibia	Compromised	>15 cm	Bulk cortical allograft with skeletal stabilization vs. synostosis with skeletal stabilization vs. bracing vs. amputation

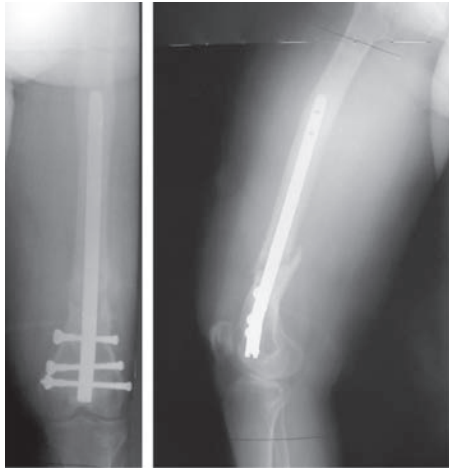
p1530 Deformity correction in a stiff nonunion is more challenging. Acute correction typically requires surgical take-down of the nonunion site or an osteotomy at the nonunion site. Both effectively correct the deformity but damage the nonunion site and may impair bony healing. With a large deformity, the ultimate fate of the neighboring soft tissues and neurovascular structures must be considered when acute deformity correction is contemplated. Gradual correction of a deformity in a stiff nonunion may be accomplished using Ilizarov external

fixation. Correction of length, angulation, rotation, and translation may be performed in conjunction with compression or distraction at the nonunion site. The Taylor Spatial Frame (Smith & Nephew, Memphis, TN) has simplified frame preconstruction and expanded the combinations of deformity components that can be treated simultaneously (Figs. 22-40 through 22-43).⁹⁷

The extent of deformity that can be tolerated without correction varies by anatomic location and from patient to patient. Generally, if the deformity is anticipated to

p1540

f0390 **FIGURE 22-39** *Example of a femoral nonunion that has failed multiple exchange nailings. This 51-year-old woman had three failed prior exchange nailing procedures.*



limit function following successful bony union, correction should be considered.

SURFACE CHARACTERISTICS

s0560

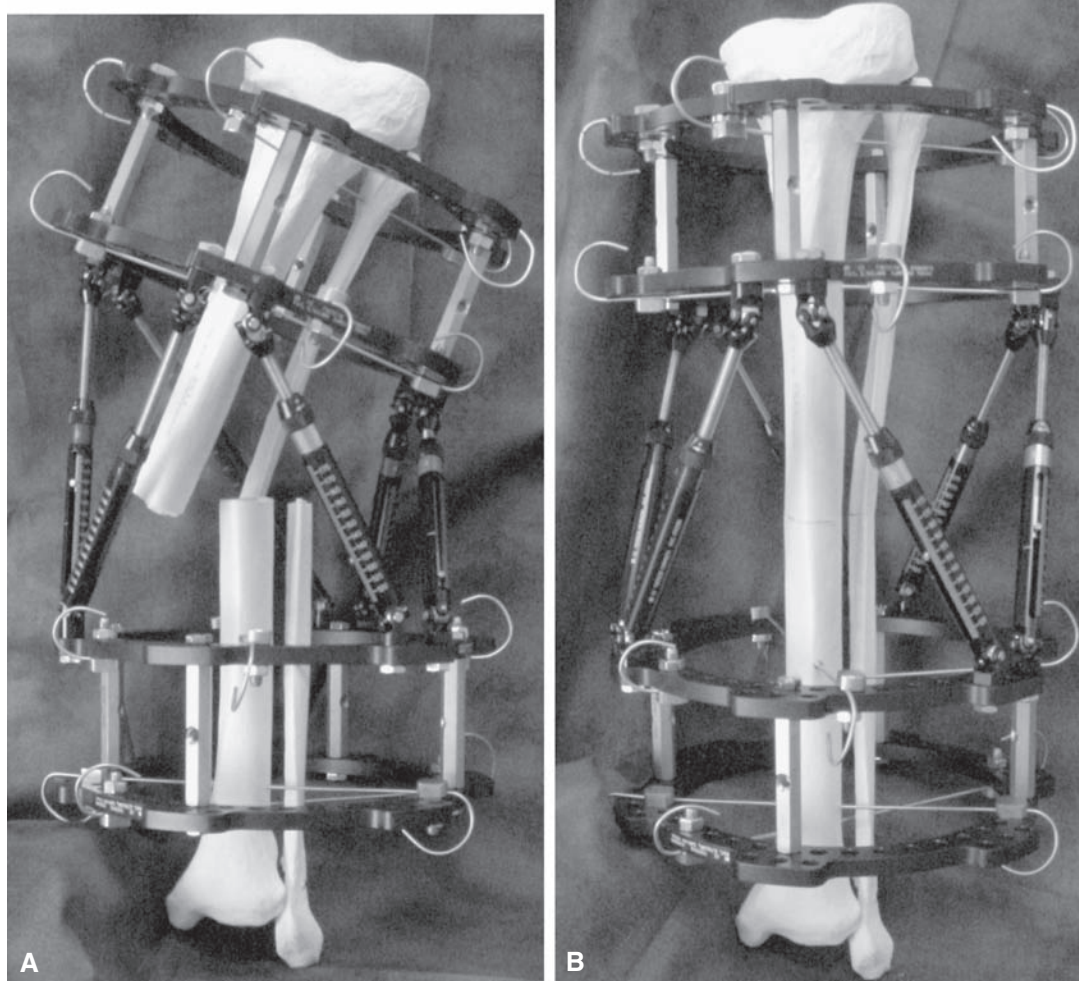
Nonunions that have large, transversely oriented adjacent surfaces with good bony contact are generally stable to axial compression and relatively easy to bring to successful bony union. By contrast, nonunions with small, vertically oriented surfaces and poor bony contact are generally more difficult to bring to bony union (Fig. 22-44).

p1550

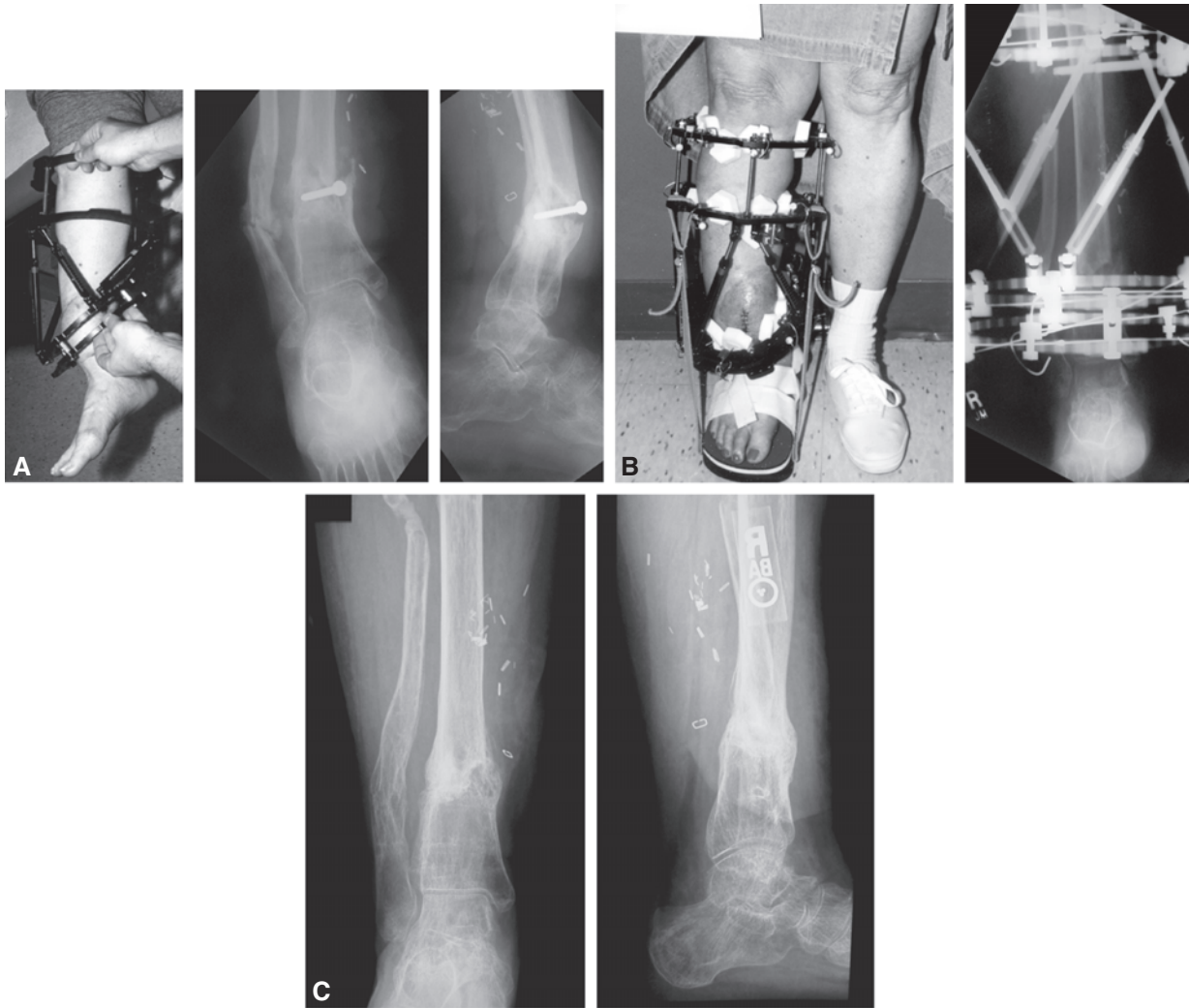Compression generally leads to bony union in nonunions when the opposing fragments have a large surface area. When the surface area is small, trimming of the ends of the bone may be necessary to improve the surface area for bony contact (Fig. 22-45). Similarly, transversely oriented nonunions respond well to compression. Oblique or vertically oriented nonunions have some component of shear, with the bones sliding past each other when subjected to axial compression. Use of interfragmentary screws with plate-and-screw fixation or steerage pins with external fixation minimizes these shear moments (Figs. 22-33 and 22-46).

p1560

f0400 **FIGURE 22-40** *The Taylor Spatial Frame (Smith & Nephew, Memphis, TN) allows for simultaneous correction of deformities involving length, angulation, rotation, and translation. **A**, Saw bone demonstration of a tibial nonunion with a profound deformity. Note how the Taylor Spatial Frame mimics the deformity. **B**, Following deformity correction accomplished by adjusting the Spatial Frame struts. The strut lengths are calculated with a computer software program provided by the manufacturer.*



f0410 **FIGURE 22-41** **A**, Preoperative clinical photograph showing frame fitting in the office, AP and lateral radiograph of a 58-year-old woman with a distal tibial nonunion with deformity 14 months following a high-energy open fracture. **B**, Clinical photograph and AP radiograph during correction using the Taylor Spatial Frame. **C**, Final radiographic result.



s0570 **PAIN AND FUNCTION**

p1570 The “painless” nonunion is seen in three specific instances: hypertrophic nonunions, elderly patients, and Charcot neuropathy.

p1580 Some hypertrophic nonunions have relative stability and therefore may not cause symptoms during normal daily activities unless the fracture nonunion site is stressed (e.g., running, jumping, lifting, or pushing). Painless hypertrophic nonunions occur mostly in the clavicle, humerus, ulna, tibia, and fibula. They are identified by a fine line of cartilage at a hypertrophic fracture site visible only on an overexposed radiograph. Subsequent tomograms or a CT scan confirms the nonunion (Fig. 22-47).

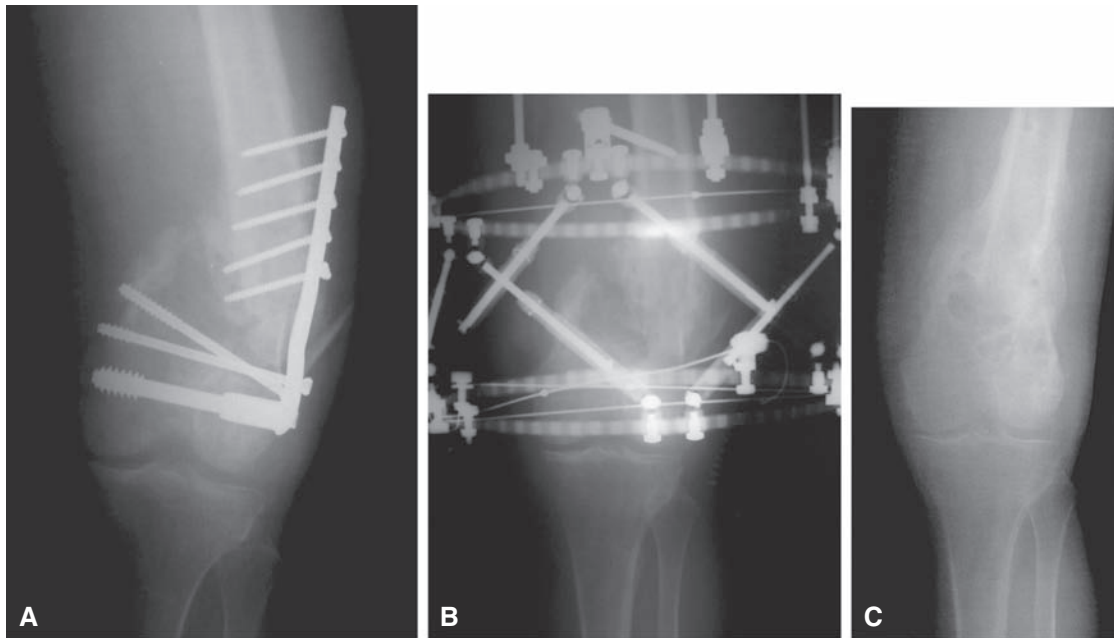
p1590 Painless nonunions are also seen in the elderly, most typically involving the humerus, but occasionally in the proximal ulna, and less frequently in the femur, tibia, and fibula. Nonoperative treatment can be acceptable as long as day-to-day function is not affected. Nonoperative treatment should be considered in the elderly patient with

multiple medical comorbidities that increase the risk of perioperative complications. In such cases, immobilization in a brace or cast (Fig. 22-48), possibly including ultrasonic or electrical stimulation of the nonunion site, may be warranted.²⁴⁶ Operative stabilization may be necessary if the patient’s routine daily activities are impaired or if there is concern about the overlying soft tissues (Fig. 22-49).

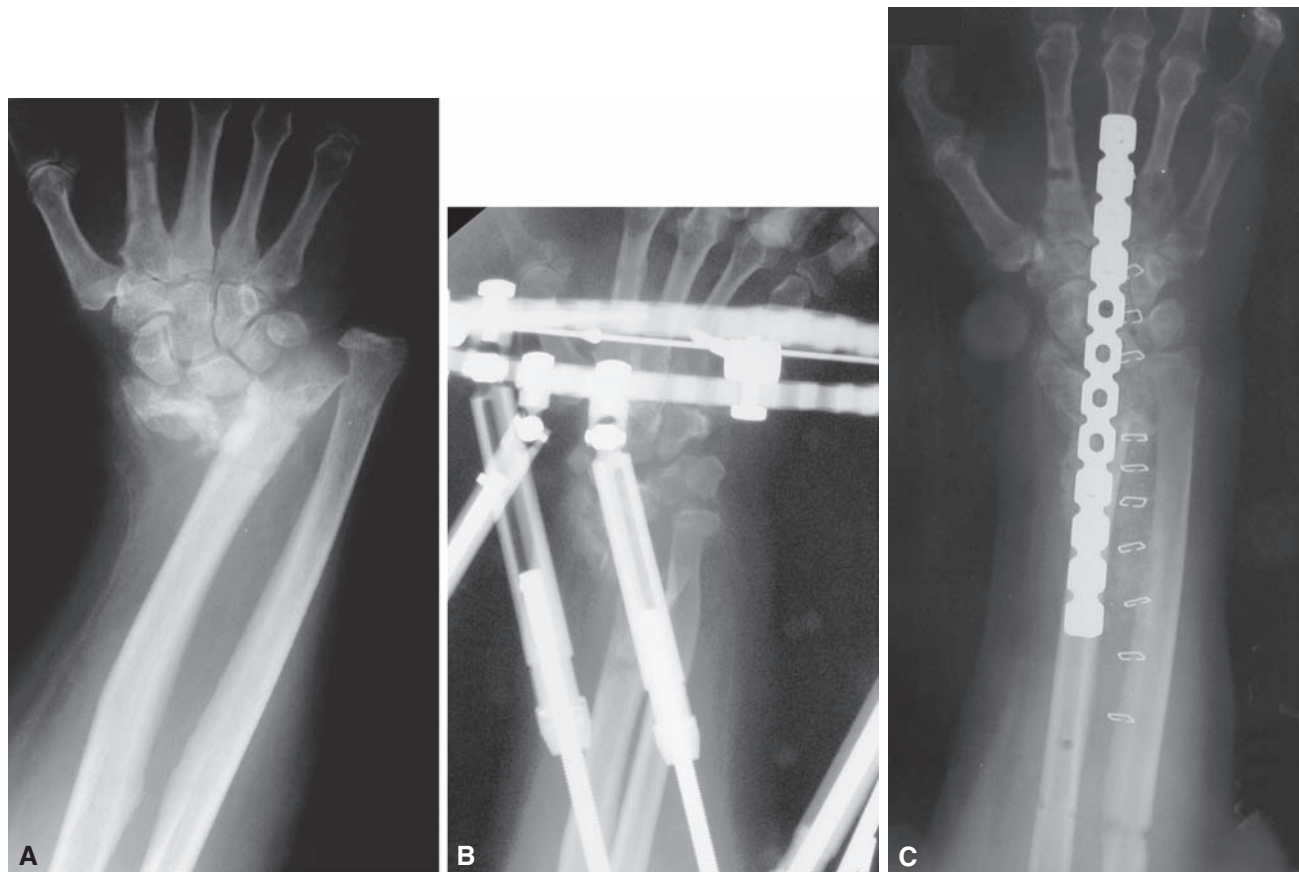
Fracture nonunion in the presence of Charcot neuropathy can produce severely deformed and injured bones and joints that are relatively painless. These cases are usually treated with bracing and without surgery unless the overlying soft tissues are jeopardized (see Fig. 22-49).

In all cases of painless fracture nonunion, the medical history, physical examination, and imaging studies should all be carefully considered when determining the treatment strategy. Operative intervention does not always improve the patient’s condition and can result in serious problems. Simple, nonoperative treatment may control the patient’s symptoms and maintain or restore function, thus providing a satisfactory outcome.

f0420 **FIGURE 22-42** **A**, Preoperative radiograph of a 60-year-old man with a distal femoral nonunion with deformity 6 months following open reduction internal fixation. **B**, Radiograph during correction using the Taylor Spatial Frame. **C**, Final radiographic result.



f0430 **FIGURE 22-43** **A**, Preoperative AP radiograph of a 73-year-old woman with a distal radius nonunion with a fixed (irreducible) deformity 9 months following injury. **B**, AP radiograph during deformity correction using the Taylor Spatial Frame. **C**, Early postoperative radiograph following deformity correction and plate-and-screw fixation with bone grafting for a wrist arthrodesis.



f0440 **FIGURE 22-44** Lateral radiograph of tibial nonunion in a 59-year-old man 6 months following fracture. Nonunions such as this with vertically oriented surfaces and poor bony contact can be challenging.

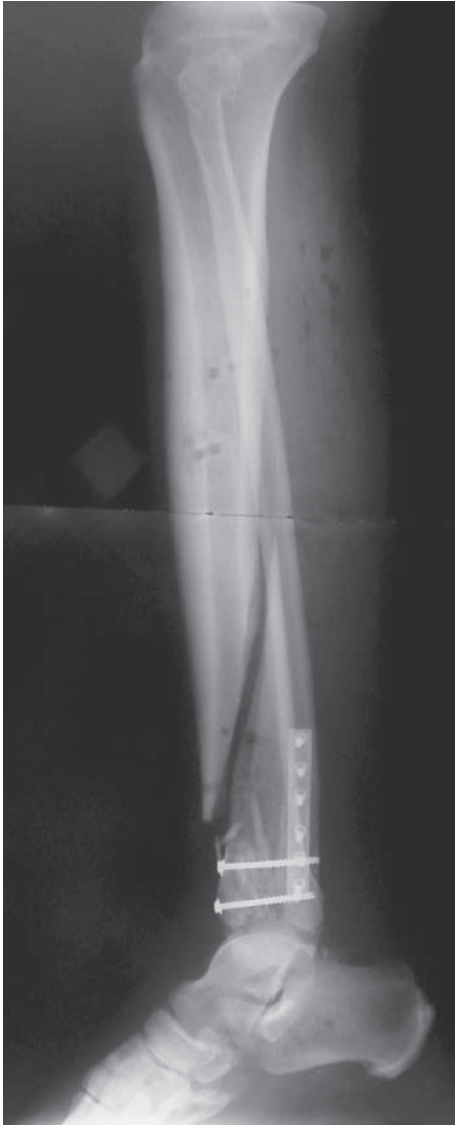


FIGURE 22-46 Steerage pins (arrow) enhance skeletal stabilization.

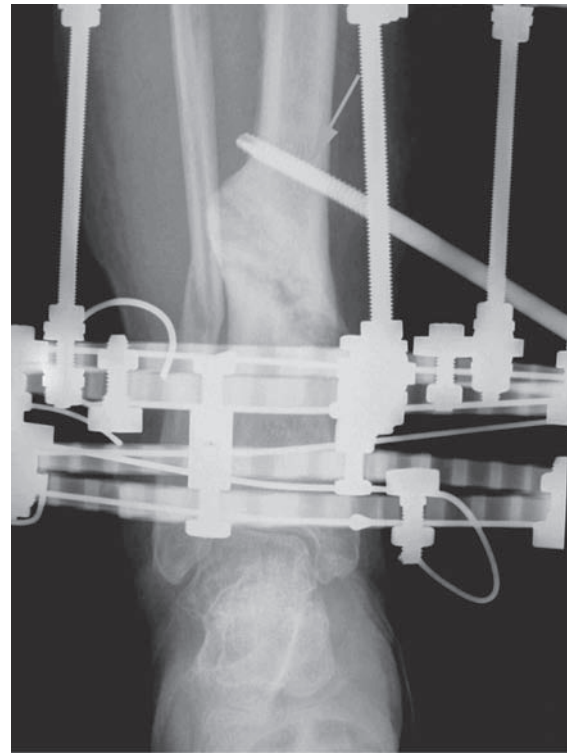
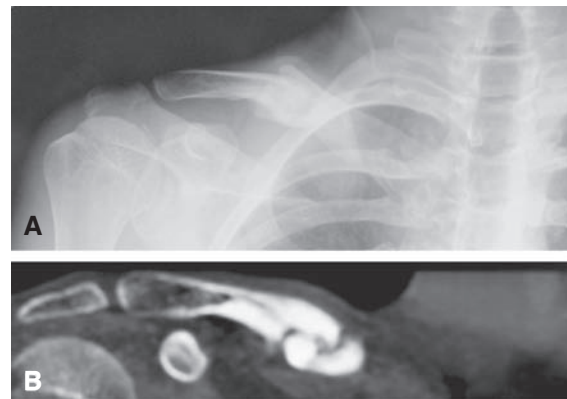
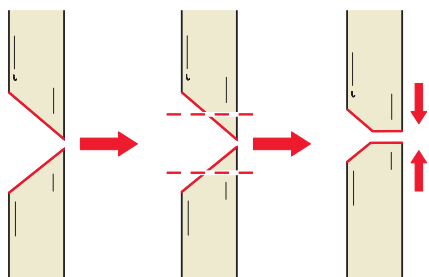


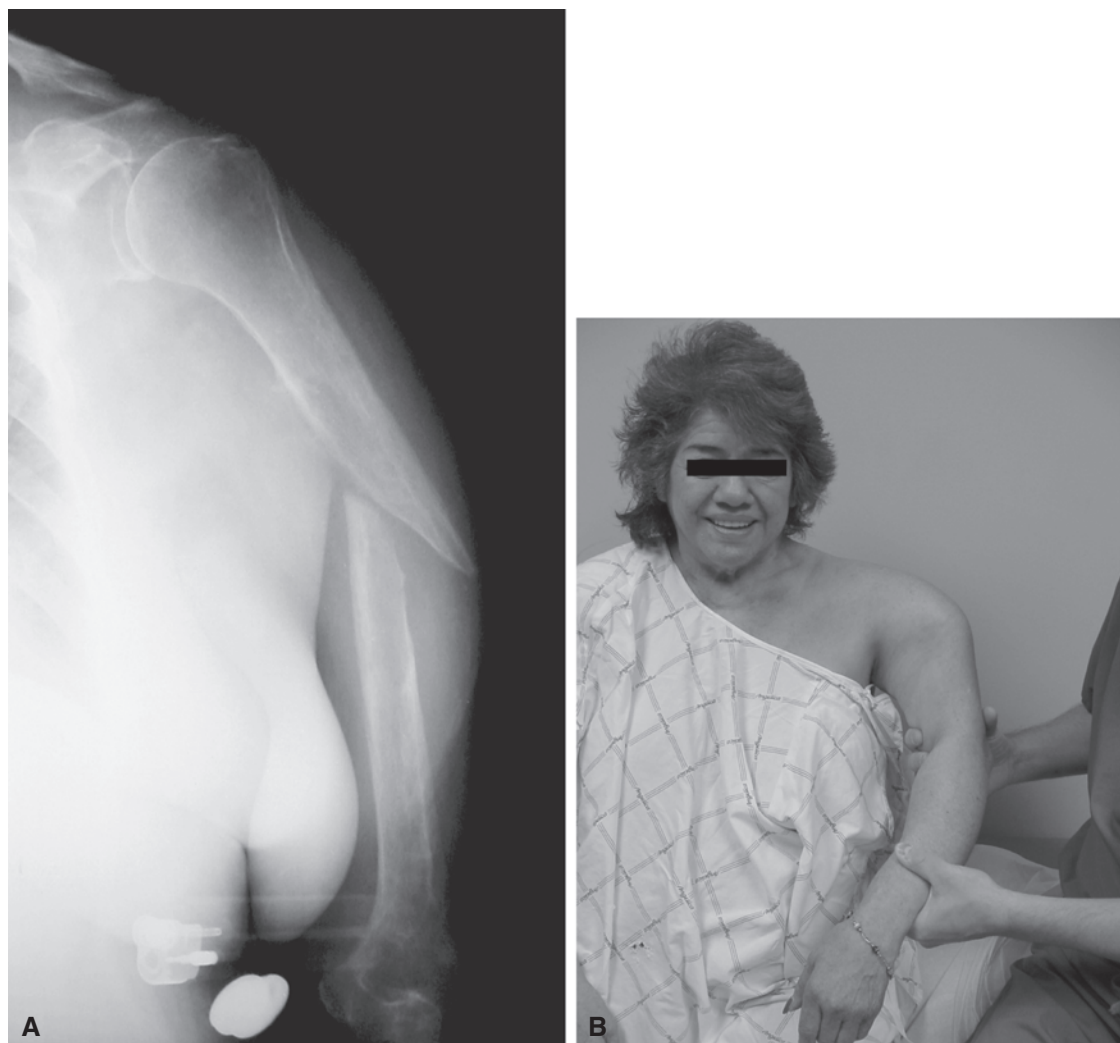FIGURE 22-47 **A**, AP radiograph of a 17-year-old male 6 months following a clavicle fracture. He had been told by his prior treating physician that his clavicle was solidly healed. He had no complaints of pain. He was brought in by his mother, who was concerned about the bump on his collarbone. **B**, CT scan confirms the diagnosis of nonunion.



f0450 **FIGURE 22-45** Trimming of the ends of the bone at a nonunion site may improve the surface area for bony contact.



f0480 **FIGURE 22-48** **A**, AP radiograph of a 71-year-old right-hand-dominant woman with multiple medical problems 27 months after a left humeral shaft fracture. **B**, Clinical examination is consistent with a lax (flail) nonunion that is not associated with pain. This patient is an excellent candidate for nonoperative treatment with functional bracing.



s0580 **OSTEOPENIA**

p1620 Nonunions in patients with osteopenic bone are especially challenging. Osteopenia may be isolated to one bone, as with an atrophic or infected nonunion, or it may involve many areas of the skeleton, as in osteoporosis or metabolic bone disease. Metabolic bone disease should be suspected in patients with nonunions in locations that do not typically have healing problems (Fig. 22-50), in long-standing cases that have failed to unite despite adequate treatment, or in cases with loss of hardware fixation but without technical deficiencies.

p1630 Intramedullary nailing is a good technique for osteopenic bone. Intramedullary nails function as internal splints and have beneficial load-sharing characteristics. Proximal and distal interlocking screws help maintain rotational and axial stability. Specially designed interlocking screws for purchase in poor bone stock are available. In cases requiring rigid fixation, an “intramedullary plate” construct can be achieved with a custom intramedullary nail and multiple interlocking screws (Fig. 22-51).

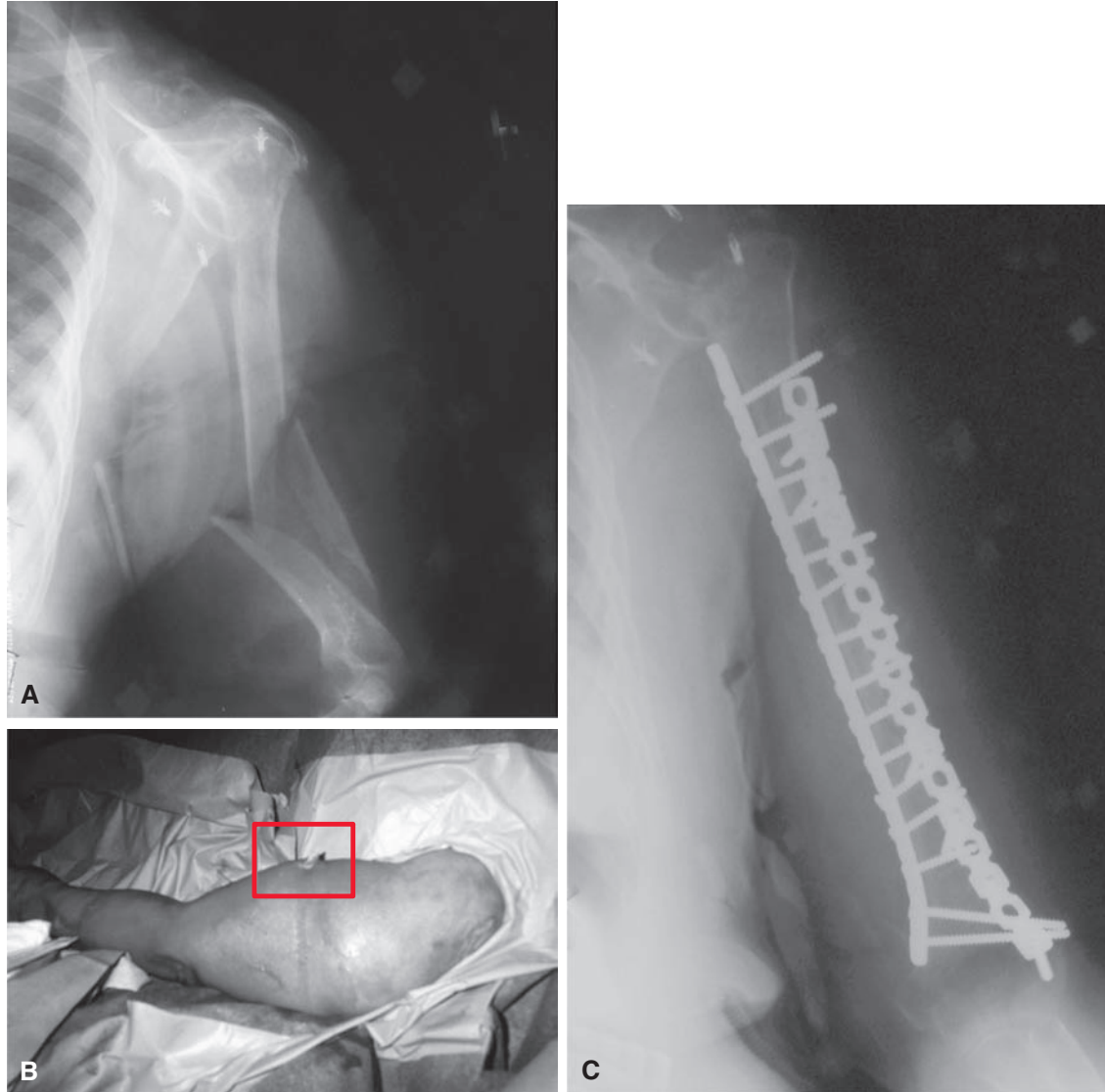
Plate-and-screw devices are prone to loosening in osteopenic bone where purchase at the screw-bone junction may be poor. Fixation may have to be augmented in such cases. Van Houwelingen and McKee described the use of cortical allograft struts and bone grafting to augment fixation of a standard compression plate in the treatment of osteopenic humeral nonunions.³²⁰ Weber and Cech³²⁹ described the reinforcement of the screw holes with PMMA bone cement (Fig. 22-52), which is especially useful for nonunion of an osteopenic metaphysis. Locking plates greatly enhance fixation in osteopenic bone. Each screw acts as a fixed-angle device and distributes loads evenly across all screw-bone interfaces. Fixation is particularly enhanced with the use of diverging and converging locking screws.

The thin wires in Ilizarov external fixation provide surprisingly good purchase in osteopenic bone. Olive wires increase stability by discouraging translational moments at the wire-bone interface. A washer at the olive wire-bone interface distributes the load to prevent erosion of the olive into the bone.

f0490

FIGURE 22-49

A, Radiograph of an asymptomatic humeral shaft nonunion in an 82-year-old woman with Charcot neuropathy (and a Charcot shoulder) of the left upper extremity from a large syrinx. The patient had been managed nonoperatively with a functional brace by her initial treating physician. **B**, The patient was referred for skeletal stabilization when a bony spike at her nonunion site eroded through her tenuous soft tissue envelope. **C**, Definitive plate-and-screw stabilization following irrigation and débridement led to bony union.

s0590 **MOBILITY OF THE NONUNION**

p1660 A nonunion may be described as stiff or lax, based on the results of manual stress testing. A stiff nonunion has an arc of mobility of 7° or less, whereas a lax nonunion has an arc greater than 7° .^{144,294} These terms are most applicable when treatment involves Ilizarov external fixation.

p1670 Stiff hypertrophic nonunions may be treated using compression, distraction, or sequential monofocal compression-distraction. Lax hypertrophic and oligotrophic nonunions may be treated with gradual compression. Some authors²⁹⁴ recommend 2 to 3 weeks of compression followed by gradual distraction, but we have found distraction unnecessary in most cases (Fig. 22-53). Others²²⁰ have recommended sequential monofocal distraction-compression in the treatment of hypertrophic nonunions. Lax infected nonunions and synovial pseudarthrosis are

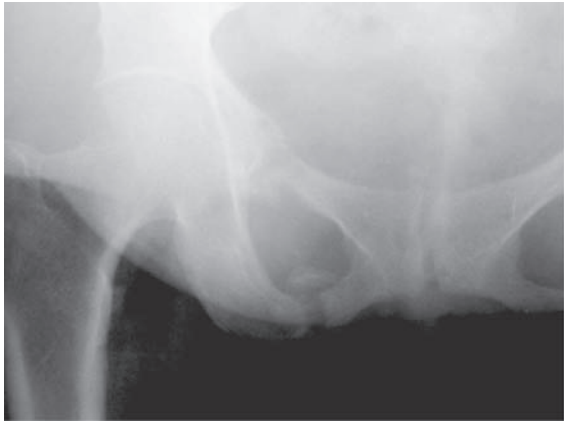
treated as described previously. The specifics of the Ilizarov methods are covered later in this chapter.

STATUS OF HARDWARE

s0600

Previously placed hardware affects nonunion treatment p1680 strategy. One consideration is whether removal of the existing hardware is required. Removal of previously placed hardware is recommended when it is associated with an infected nonunion, it interferes with the contemplated treatment plan, or it is broken or loose and causing symptoms. Previously placed hardware may be retained when it augments the contemplated treatment plan or when surgical dissection to remove the hardware might not be desirable (e.g., obesity, previous infection, or multiple prior soft tissue reconstructions) and the hardware does not interfere with the contemplated treatment plan.

f0500 **FIGURE 22-50** AP radiograph of the pelvis of a 50-year-old woman 16 months following a superior and inferior pubic rami fracture. The endocrinology workup in this patient with a nonunion in an unusual location revealed an underlying metabolic bone disease.



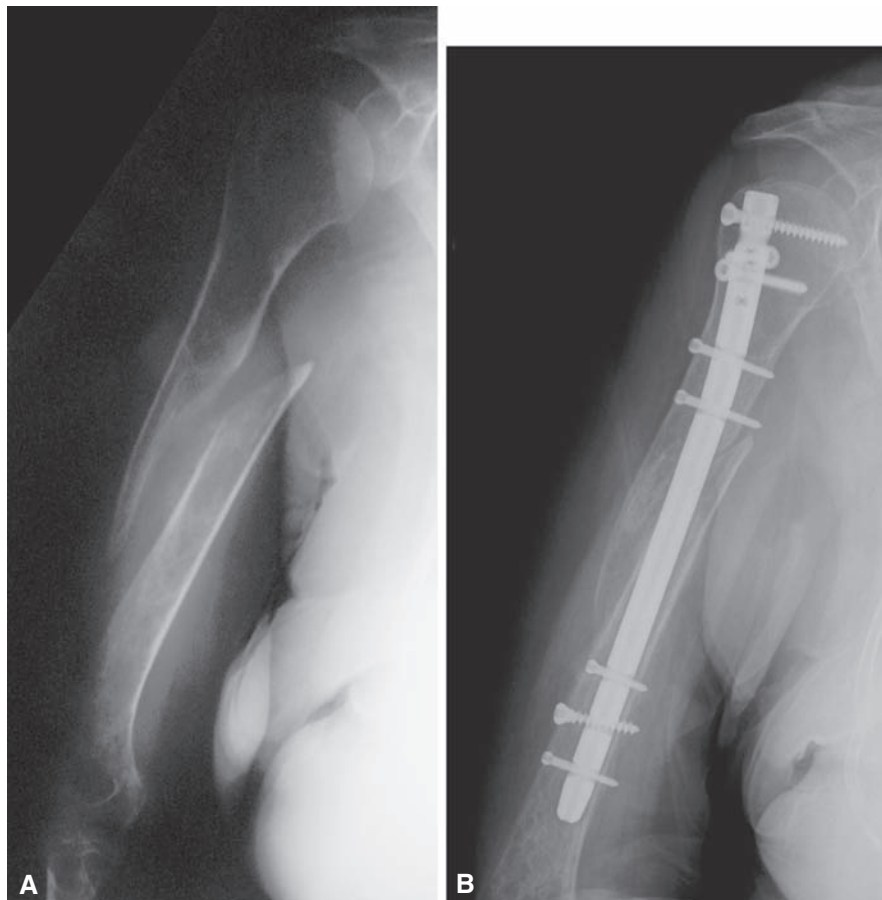
The previously placed hardware can sometimes be used in the definitive treatment. For example, if a statically locked nail is holding the bone fragments of an oligotrophic nonunion in distraction, the interlocking screws may be removed proximally or distally to compress the nonunion site acutely using an external device. p1690

MOTOR AND SENSORY DYSFUNCTION

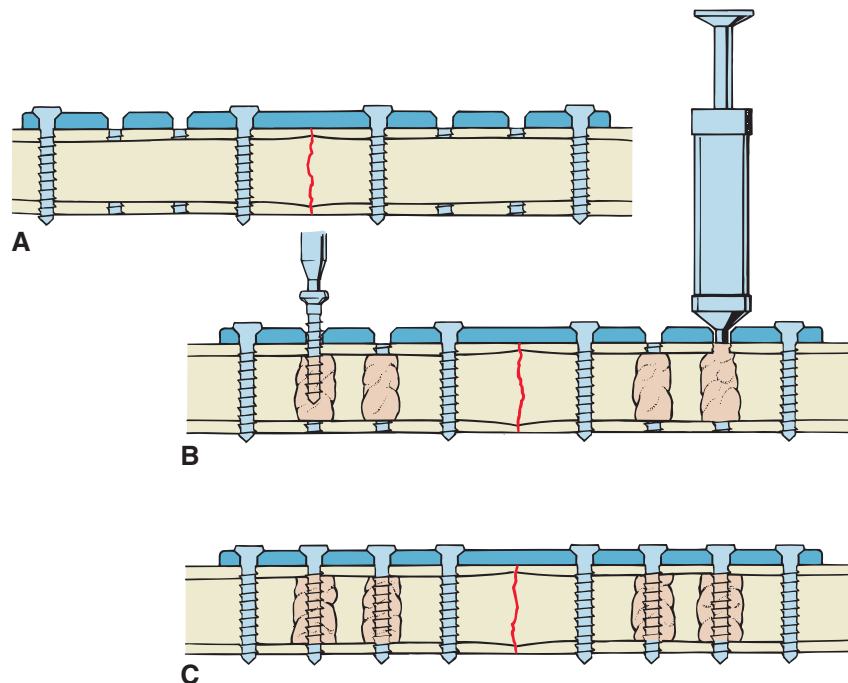
Many compensatory and adaptive strategies are available to address motor or sensory deficits associated with a nonunion. Bracing, strengthening of intact muscles in the region, and the use of assistive devices may preserve or restore function and thus allow retention of the limb. For example, if anterior compartment motor function of the leg is impaired following successful nonunion treatment, ambulation can be improved by applying an ankle-foot orthosis or by performing a tendon transfer. p1700

There are several factors to consider when designing a treatment plan in a patient with a nonunion associated with neural dysfunction (Table 22-8). If neural reconstruction cannot restore purposeful limb function, and techniques such as tendon transfers or bracing are not likely to be p1710

f0510 **FIGURE 22-51** Custom-manufactured intramedullary nails with multiple interlocking screw capability augment the rigidity of fixation and function as an “intramedullary plate.” We have used this type of construct with great success in elderly patients with symptomatic humeral shaft nonunions with large medullary canals and osteopenic bone. **A**, Preoperative radiograph of an 80-year-old woman with a painful humeral nonunion 14 months after fracture. **B**, Early postoperative radiograph following percutaneously performed “intramedullary plating” using a custom-made humeral nail.



f0520 **FIGURE 22-52** Polymethylmethacrylate (PMMA) cement is an effective method for obtaining screw purchase in osteoporotic bone. **A.** The loose screws are removed, except for those adjacent to or crossing the nonunion and those at the proximal and distal ends of the plate. **B.** Slow-setting PMMA is mixed for 1 minute and then poured into a 20-mL syringe. The liquid cement is injected into the screw holes. **C.** The screws are rapidly reinserted into the cement in the holes. The cement should not be allowed to enter the fracture site or go around the bone. After approximately 10 minutes to allow cement hardening, the screws are tightened and checked for stability. If the end screws are essential for fixation and are also loose, they are removed, another batch of cement is mixed and injected, and the end screws are reinserted. (Redrawn from Weber, B.G; Cech, O. Pseudarthrosis. Bern, Hans Huber, 1976).



benefit, amputation may be considered. While limb ablation has obvious disadvantages, it is less prolonged, less costly, and less traumatizing than multiple reconstructions that may not improve an insensate or flaccid limb or improve the patient's quality of life.

s0620 **PATIENT HEALTH AND AGE**

p1730 Patients who have serious medical conditions may be poor surgical candidates, and elderly patients are more likely to have such medical conditions. In addition, elderly patients who have been nonambulatory for an extended period, are cognitively impaired, or are confined to a long-term care facility may not benefit from reconstructive surgery for nonunions. The functional status of these patients is unlikely to improve with surgery, and noncompliance with postoperative instructions may produce further complications. In such cases, nonoperative treatment such as bracing is appropriate and engenders greater compliance.

p1740 When health is such that survival takes precedence over healing the nonunion, amputation may be considered. On the other hand, elderly patients often benefit from treatment that allows immediate weight-bearing and functional activity, which may decrease the risk of complications such as pneumonia and thromboembolism (Fig. 22-54).

s0630 **PROBLEMS AT ADJACENT JOINTS**

p1750 Stiffness or deformity of the joints adjacent to the nonunion can limit outcome. Nonoperative therapies, such

as joint mobilization and range-of-motion exercises, are commonly prescribed either preoperatively, to prepare for postoperative activity, or postoperatively, to restore limb function following successful nonunion treatment. Alternatively, joint stiffness or deformity can be treated with arthrotomy or arthroscopy either concomitantly with the procedure for the nonunion or as a subsequent, staged surgical procedure. Several treatment options for a compensatory joint deformity adjacent to a nonunion with an angular or rotational deformity exist: joint mobilization via physical therapy, surgical lysis of adhesions at the time of surgery for the fracture nonunion, surgical lysis of adhesions after the nonunion has solidly united in a reduced anatomic position, arthrodesis of the involved joint with acute correction of the compensatory deformity at the time of surgery for the fracture nonunion, and arthrodesis of the involved joint with acute correction of the compensatory deformity after the nonunion has solidly united in a reduced anatomic position.

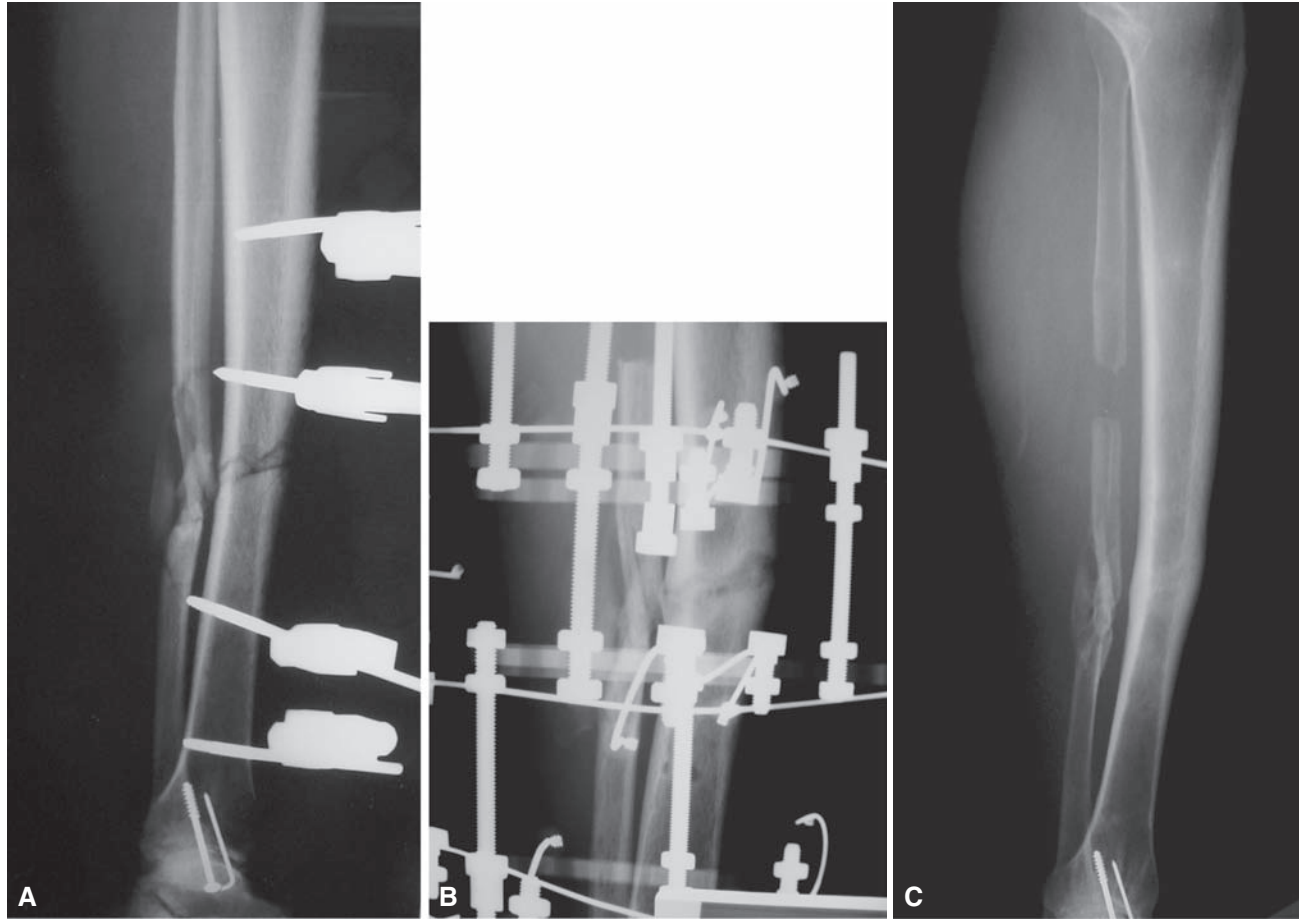
SOFT TISSUE PROBLEMS

Patients with nonunion often have substantial overlying soft tissue damage resulting from the initial injury or multiple surgical procedures, or both. Whether to approach a nonunion through previous incisions or by elevating a soft tissue flap or through virgin tissues is a difficult decision made on a case-by-case basis. Consulting a plastic reconstructive surgeon is advisable.

s0640

p1760

f0530 **FIGURE 22-53** **A**, Radiograph of a mid-shaft oligotrophic tibial nonunion in a 53-year-old man 10 months following unilateral external fixator stabilization for an open tibia fracture. Because of a history of recurrent pin tract infections and because the external fixator had been removed 3 weeks prior to presentation, intramedullary nail fixation was not believed to be an entirely safe treatment option. The patient was treated with gradual compression using an Ilizarov external fixator. **B**, Radiograph during treatment shows gradual dissolution of the nonunion site with gradual compression. **C**, Final radiographic result.



t0080

Table 22-8	
Considerations Affecting Treatment Strategy for a Nonunion with Neural Dysfunction	
Quality and extent of plantar or palmar sensation	
Location and extent of other sensory deficits	
Magnitude, location, and extent of motor loss	
Potential for improvement following reconstructive procedures	

p1770 Extremities with extensive soft tissue problems may benefit from less invasive methods such as Ilizarov external fixation and percutaneous marrow grafting. Nonunions associated with soft tissue defects, open wounds, or infection may require a rotational or free flap coverage procedure.

p1780 Occasionally, wound closure is facilitated by creating a deformity at the nonunion site to approximate the edges of the soft tissue defect (Fig. 22-55). Three to four weeks following wound closure, the deformity at the nonunion

site is gradually corrected, typically using Ilizarov fixation. This technique is useful for patients who are poor candidates for extensive soft tissue reconstructions, such as those who are elderly, are immunocompromised, or have significant vascular disease or medical problems.

Treatment Methods

s0650

Treatment methods that can be used in the care of patients with fracture nonunions include those that augment mechanical stability, those that provide biological stimulation, and those that both augment mechanical stability and provide biological stimulation (Table 22-9). Depending on the nonunion type and associated problems, nonunion treatment may require only a single method or several methods used in concert.

p1790

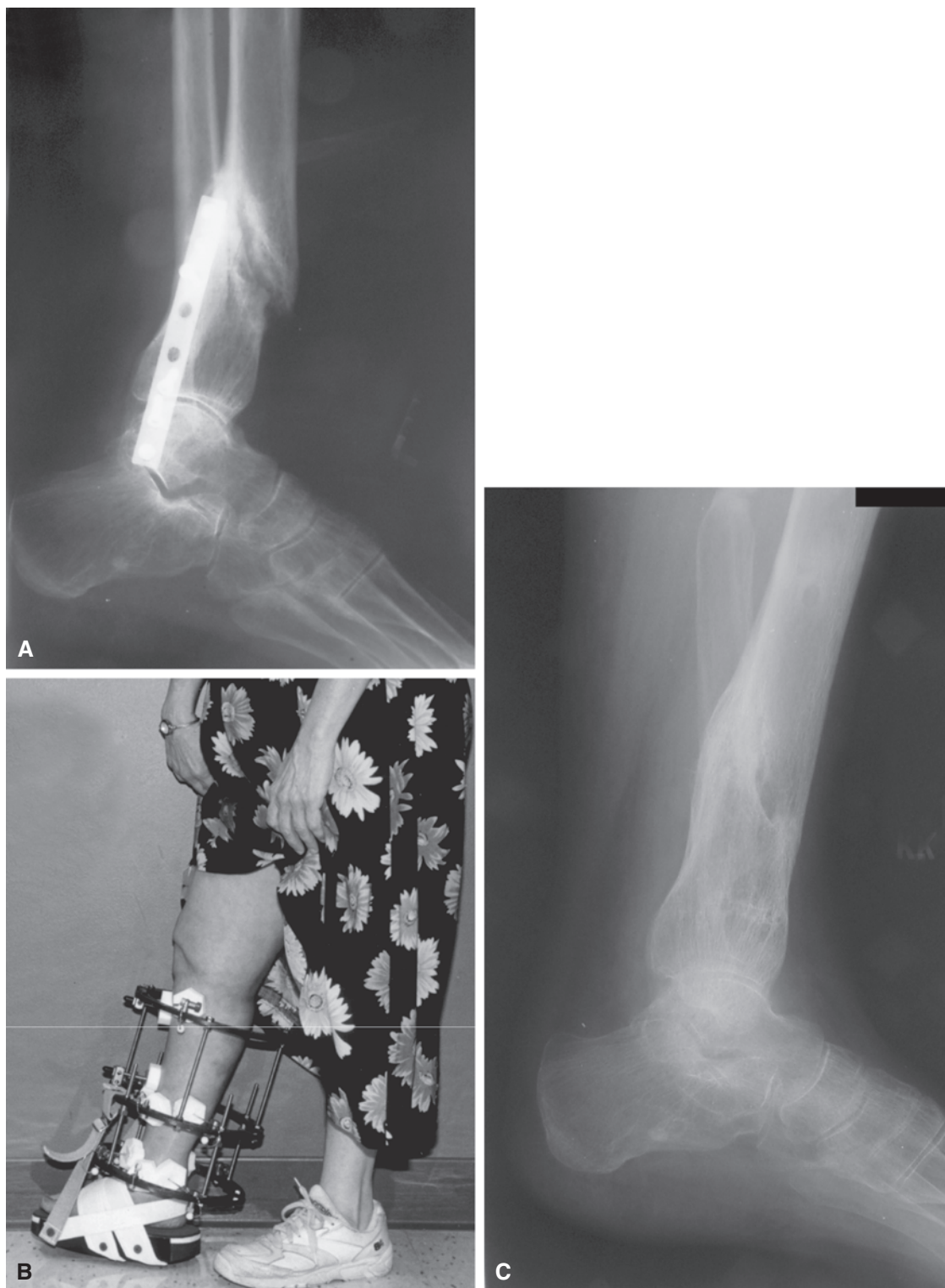MECHANICAL METHODS

s0660

Mechanical methods promote bony union by providing stability and, in some cases, bone-to-bone contact. They may be used alone or in concert with other methods.

p1800

f0540 **FIGURE 22-54** **A**, Presenting radiograph of a 73-year-old woman with a distal tibial nonunion 14 months following her initial injury. **B**, Ilizarov external fixation allows immediate weight-bearing and improvement in functional activities, which is important in elderly patients to decrease the risk of medical complications. **C**, Final radiographic result.



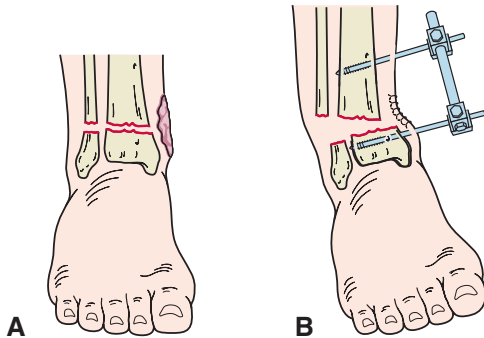
r0550

FIGURE 22-55

In certain cases, creating a deformity at the site of a nonunion facilitates wound closure. This is a particularly useful technique in elderly patients, immunocompromised patients, those with significant vascular disease, and those with severe medical problems who are not good candidates for extensive operative soft tissue reconstructions.

A, *In this example, there is a distal tibial nonunion with an open medial wound that cannot be closed primarily because of retraction of the soft tissues.*

B, *Creating a varus deformity at the nonunion site places the soft tissue edges in approximation and allows for primary closure. The deformity at the nonunion site may be corrected later following healing of the soft tissues.*



devices are most effective when used with weight-bearing for lower extremity nonunions. Functional cast bracing with weight-bearing as a treatment for tibial nonunion has been advocated by Sarmiento.²⁸⁵ The advantages of casting, bracing, and cast bracing are that they are noninvasive and useful for patients who are poor candidates for operative reconstruction. Disadvantages of these methods are that they do not provide the same degree of stability as operative methods of fixation, do not allow for concurrent deformity correction, may create or worsen deformities, and may break down the soft tissues in lax nonunions (see Fig. 22-49).

External supportive devices are most effective for stiff hypertrophic nonunions of the lower extremity. Oligotrophic nonunions that are not rigidly fixed in a distracted position may also benefit from casting or bracing and weight-bearing. Unless surgery is absolutely contraindicated, external supportive devices have no proven role in the treatment of atrophic nonunions, infected nonunions, or synovial pseudarthrosis.

DYNAMIZATION Dynamization entails creating a construct that allows axial loading of bone fragments, ideally while discouraging rotational, translational, and shear moments. Dynamization is most commonly used as an adjunctive treatment method for nonunions of the lower extremity that are being treated by intramedullary nail fixation or external fixation.

Removing the interlocking screws of a statically locked intramedullary nail allows the bone fragments to slide toward one another over the nail during weight-bearing. This results in improved bone contact and compression at the nonunion site. In most cases, the interlocking screws on one side of the nonunion (proximal or distal) are removed, typically those at the greatest distance from the nonunion site (Fig. 22-57). When dynamization of an intramedullary nail is contemplated, axial stability and anticipated shortening must be considered. If shortening is anticipated to the extent that the intramedullary nail will penetrate the joint proximal or distal to the nonunion, treatment methods other than dynamization should be employed.

The advantages of nail dynamization are that it is minimally invasive and allows for immediate weight-bearing.

s0670p1810

WEIGHT-BEARING Weight-bearing is used for nonunions of the lower extremity, primarily the tibia. Weight-bearing is usually used in conjunction with an external supportive device, dynamization, or excision of bone (Fig. 22-56).

s0680p1820

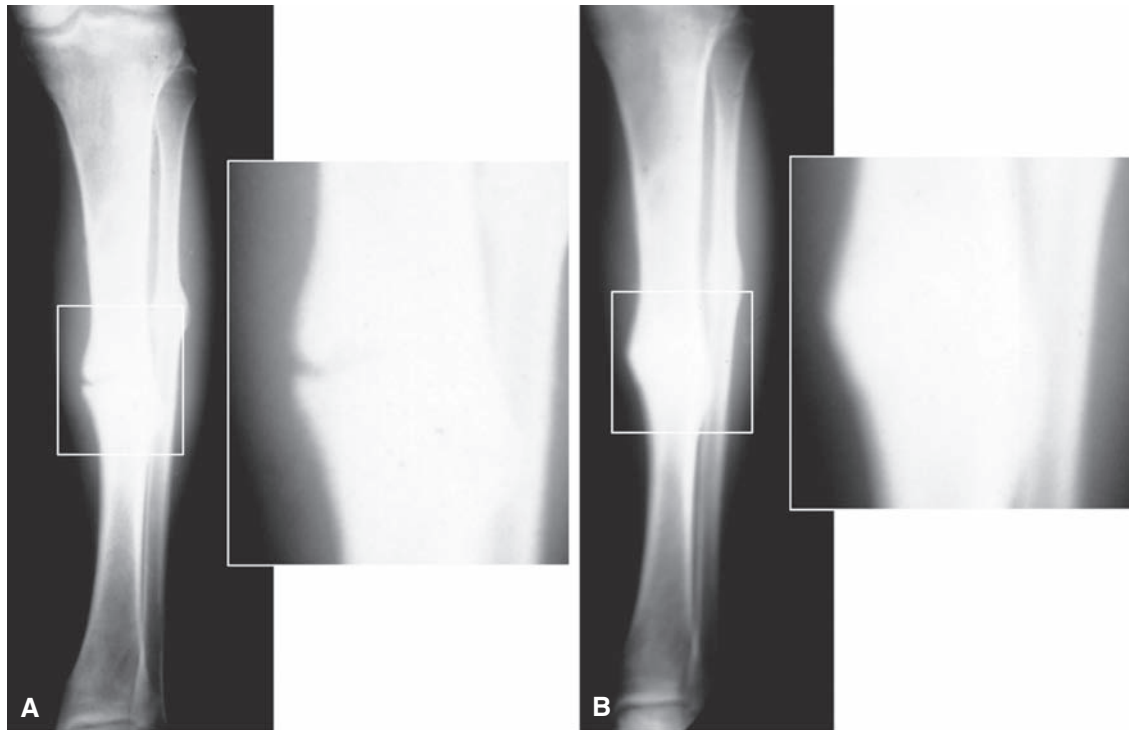
EXTERNAL SUPPORTIVE DEVICES Casting, bracing, and cast bracing can augment mechanical stability at the site of nonunion. In certain instances, especially hypertrophic nonunions, the increase in stability from these devices may result in bony union. External supportive

Table 22-9

Treatment Methods for Nonunions

Mechanical Methods	Biological Methods	Methods That Are Both Mechanical and Biological
Weight-bearing	Nonstructural bone grafts	Structural bone grafts
External supportive devices	Decortication	Exchange nailing
Dynamization	Electromagnetic, ultrasound, and shock wave stimulation	Synostosis techniques
Excision of bone		Iizarov method
Screws		Arthroplasty
Cables and wires		Arthrodesis
Plate-and-screw fixation		Amputation
Intramedullary nail fixation		
Osteotomy		
External fixation		

f0560 **FIGURE 22-56** **A**, Presenting radiograph of a 44-year-old man 8 months following a tibial shaft fracture. The patient did not desire any operative intervention and was treated with weight-bearing in a functional brace. **B**, Final radiograph 5 months following presentation shows solid bony union.



Disadvantages are that it results in axial instability with possible shortening³⁴¹ and in rotational instability, although some intramedullary nails have oblong interlocking screw holes that prevent rotational instability (see Fig. 22-57). The technique may be useful for hypertrophic and oligotrophic nonunions of the lower extremity. Atrophic and infected nonunions and synovial pseudarthroses are best treated by other methods.

p1870 **Dynamization of an external fixator** involves removal, loosening, or exchange of the external struts spanning the nonunion. The method is most effective for lower extremity cases and is commonly used only after bony incorporation at the nonunion site is believed to be under way. Dynamizing an external fixator is therapeutic because axial loading at the nonunion site promotes further bony union. It is also diagnostic because an increase in pain at the nonunion site following dynamization suggests motion, indicating that bony union has not progressed to the extent presumed.

s0700p1880 **EXCISION OF BONE** Excision of bone in the treatment of a nonunion is performed by three distinct methods. The first involves excision of one or more bone fragments to alleviate pain associated with the rubbing of the fragments at the nonunion site. Injection of local anesthetic into the nonunion site may suggest the extent of pain relief anticipated following bone excision (Fig. 22-58). Excision of bone will alleviate pain without impairing function at the fibula shaft (assuming the syndesmotic tissues are competent) and the ulna styloid. Partial excision of un-united fragments of the olecranon and patella may be indicated

in certain cases. Partial excision of the clavicle as a treatment for nonunion has been reported by Middleton et al.²⁰⁰ and Patel and Adenwalla,²²⁹ although we do not advocate this treatment option.

In the second method, excision of bone is performed on an intact bone to allow for compression across an un-united bone in limbs with paired bones. Most commonly, partial excision of the fibula allows compression across an un-united tibia in conjunction with external fixation or intramedullary nail fixation (Fig. 22-59).

The third method of bone excision is trimming and débriding to improve the surface characteristics (surface area, bone contact, and bone quality) at the nonunion site. This technique may be used for atrophic and infected nonunions and synovial pseudarthroses.

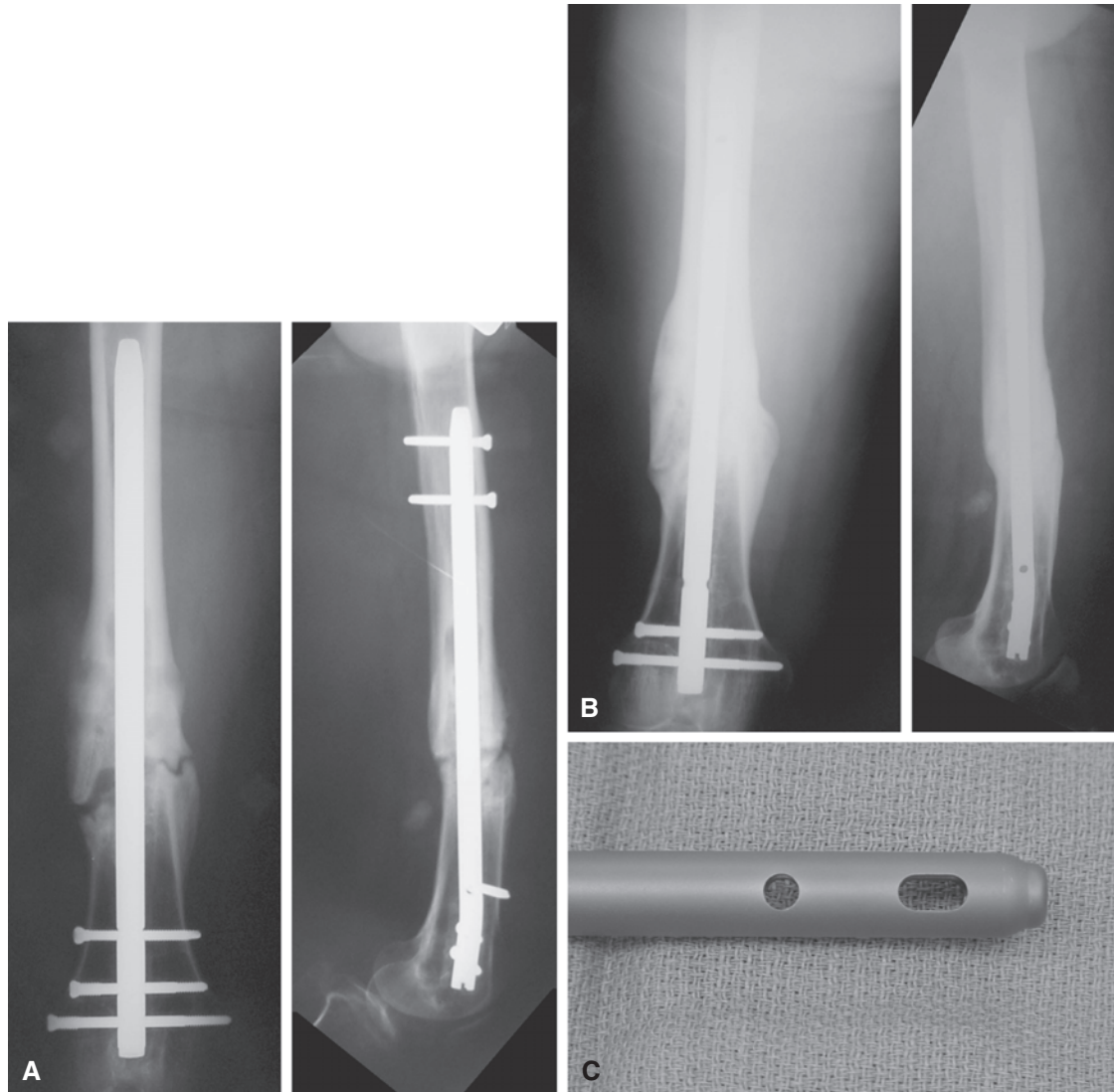
SCREWS Interfragmentary lag screw fixation is an effective treatment for epiphyseal nonunions (see Fig. 22-28), patella nonunions¹⁶³ (Fig. 22-60), and olecranon nonunions.²²⁵ Interfragmentary lag screw fixation may also be used with other forms of internal or external fixation for metaphyseal nonunions. Screw fixation alone is not recommended for nonunions of the metaphysis or diaphysis.

CABLES AND WIRES Cables or a cable-plate systems can be used to stabilize a periprosthetic bone fragment that contains an intramedullary implant, thus eliminating the need for implants transversing the occupied medullary canal. This type of reconstruction is commonly performed with autogenous cancellous bone grafting, either with or without structural allograft bone struts (Fig. 22-61).

f0570

FIGURE 22-57

A, Presenting radiographs of a 40-year-old man 31 months following a closed femur fracture. This patient had unsuccessful multiple prior procedures including exchange nailing and open bone grafting. The patient refused to have any type of major surgical reconstruction and was treated with nail dynamization by removal of the proximal interlocking screws. **B**, Final radiographs showing solid bony union 14 months following dynamization. **C**, Intramedullary nails designed with oblong interlocking screw holes allow for dynamization without loss of rotational stability.



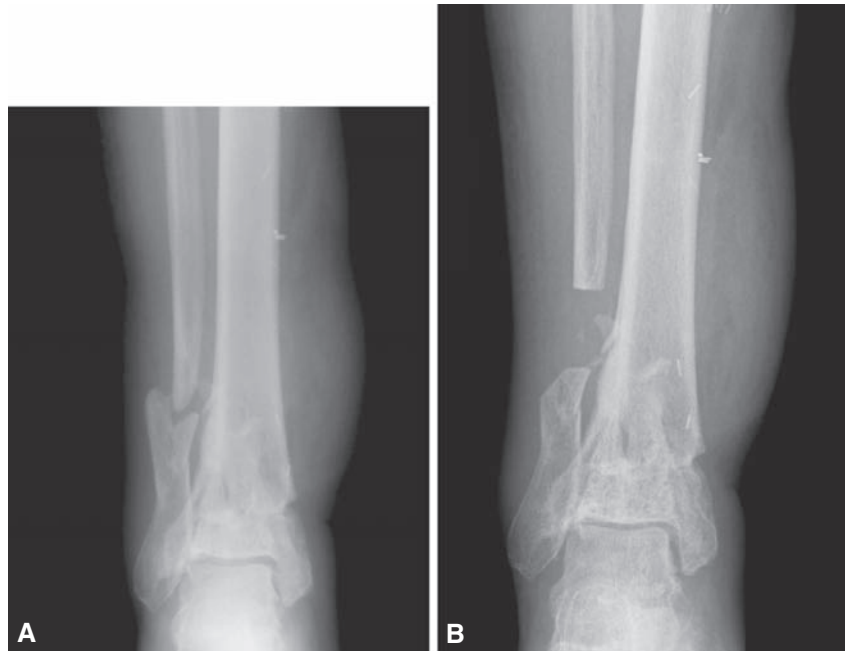
p1930 Tension band and cerclage wire techniques may also be used to treat nonunions of the olecranon and patella,¹⁶³ although we prefer more rigid fixation techniques.

s0730p1940 **PLATE-AND-SCREW FIXATION** The modern era of nonunion management with internal fixation can be traced to the establishment of the Swiss AO (Arbeitsgemeinschaft für Osteosynthesefragen) by Müller, Allgöwer, Willenegger, and Schneider in 1958. Building from the foundation of the pioneers that had preceded them^{49,68,83,150,151,160,172,173,234} and utilizing the metallurgic skills of Swiss industries and a research institute in Davos, the AO Group developed a system of implants and instruments that remain in use today. The AO Group developed the most widely utilized modern concepts of nonunion treatment (Table 22-10).

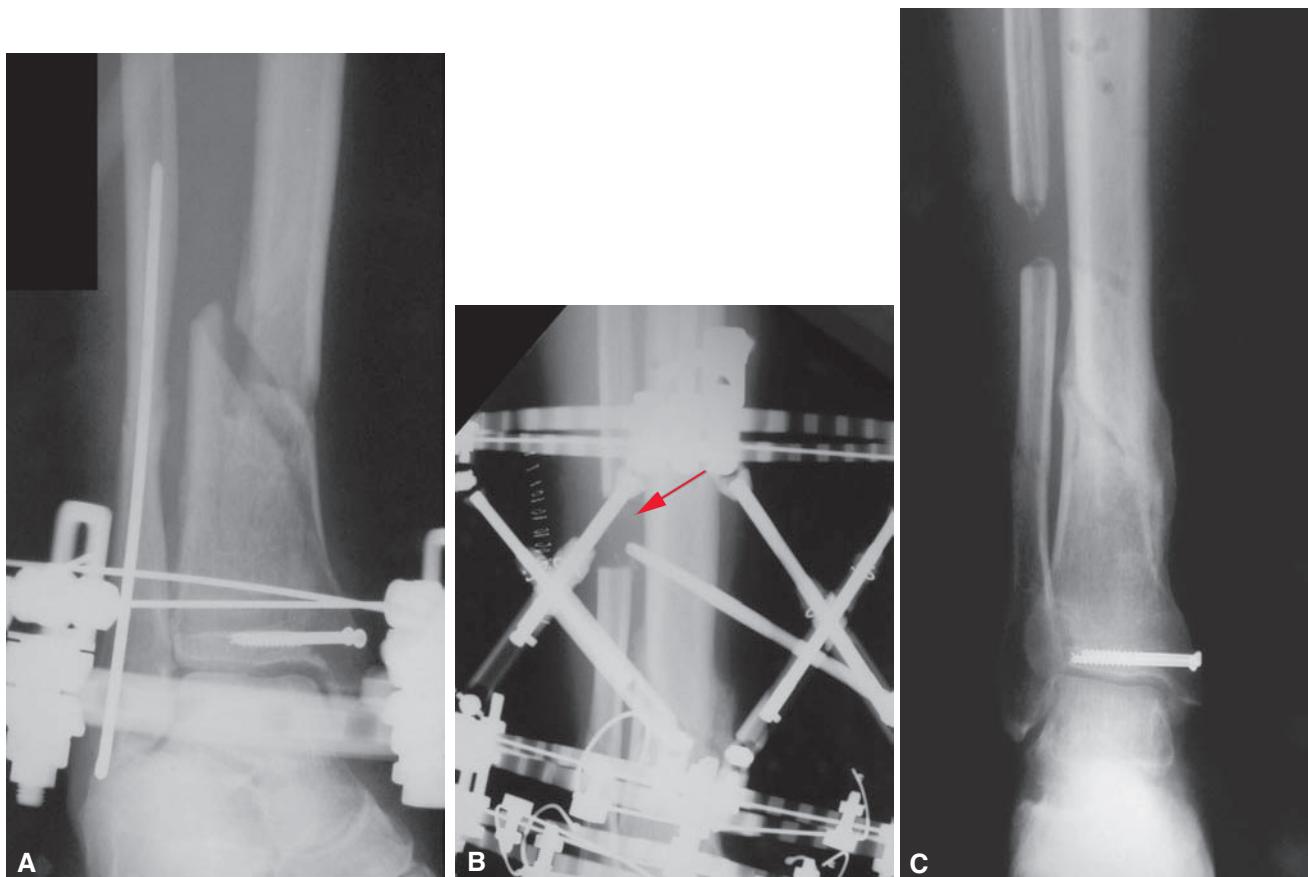
Advantages of plate-and-screw fixation include rigidity p1950 of fixation; versatility for various anatomic locations (Fig. 22-62) (e.g., periarticular and intra-articular nonunions) and situations (e.g., periprosthetic nonunions); correction of angular, rotational, and translational deformities (under direct visualization); and safety following failed or temporary external fixation. Disadvantages of the method include extensive soft tissue dissection, limitation of early weight-bearing for lower extremity applications, and inability to correct significant foreshortening from bone loss. Plate-and-screw fixation is applicable for all types of nonunions. In cases with large segmental defects, other methods of skeletal stabilization should be considered.

Many reports have documented success using plate- p1960 and-screw fixation for nonunions of the intertrochanteric

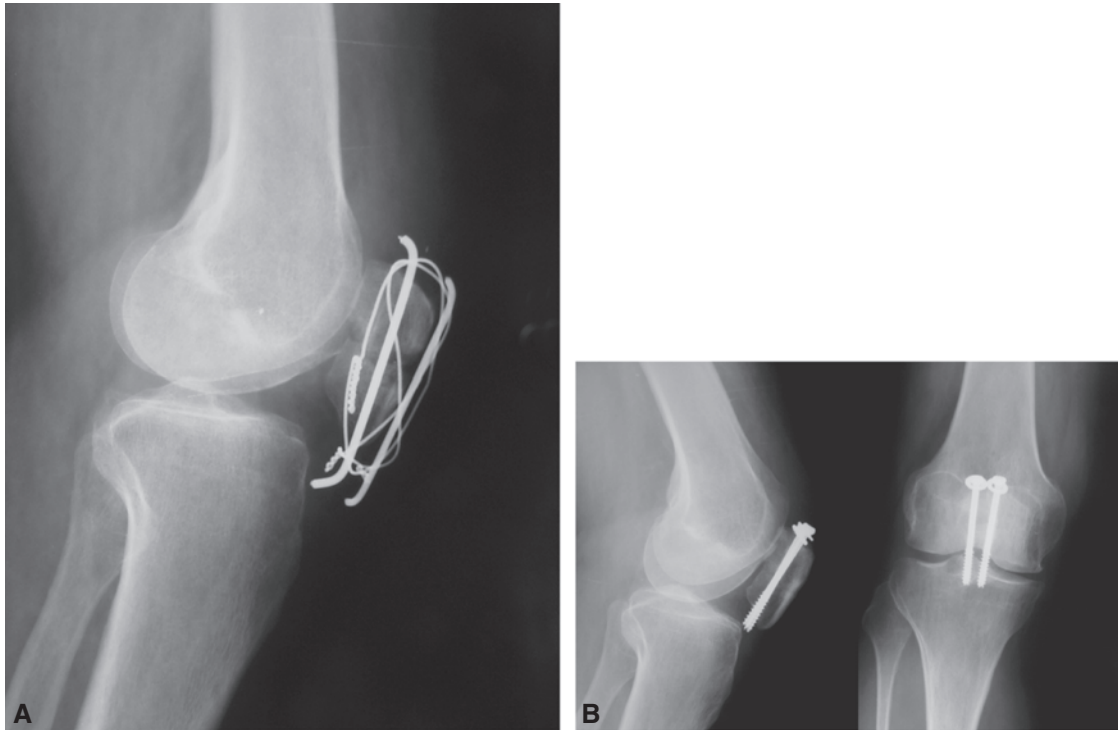
f0580 **FIGURE 22-58** **A**, Presenting radiograph of a 70-year-old man 28 months following a high-energy pilon fracture. The patient's primary complaint was pain over the fibula nonunion. Injection in this area with local anesthetic resulted in complete relief of the patient's pain. **B**, Final radiograph following treatment of the fibula nonunion via partial excision. The procedure resulted in complete pain relief.



f0590 **FIGURE 22-59** **A**, Presenting radiograph of a 42-year-old man 5 months following a distal tibia fracture. **B**, The patient was treated with deformity correction and slow, gradual compression using an Ilizarov external fixator. This required partial excision of the fibula (arrow). **C**, Final radiographic result.



f0600 **FIGURE 22-60** **A**, Presenting radiograph of a 55-year-old woman with a patella nonunion who had had four prior failed reconstructions. The patient was treated with open reduction and interfragmentary lag screw fixation. **B**, Final radiographic result shows solid bony union.



femoral region,²⁸⁴ femur,^{23,314,317} proximal tibia,^{40,43,339} tibial diaphysis,^{127,240} distal tibial metaphysis,^{52,250} fibula,³²¹ clavicle,^{31,71,80,153,218,348} scapula,^{47,99,199} proximal humerus,^{107,126} humeral shaft,^{109,186,274,310,345} distal humerus,^{24,128,193,260,283,299} olecranon,⁶⁹ proximal ulna,²⁶² ulnar and radial diaphysis,²⁵⁹ and distal radius.^{88,98} A variety of plate types and techniques are available and are presented in the chapters covering specific anatomic regions.

p1970 Locking plates use screws with threaded heads that lock into threaded screw holes on the corresponding plate. The locking of the screws creates a fixed-angle device, or “single-beam” construct, because no motion is allowed between the screws and the plate (Fig. 22-63).^{42,85,121} The locked screws resist bending moments and thus resist progressive deformity during bony healing. A locking plate construct distributes axial load across all screw-bone interfaces, in contrast to traditional plate-and-screw constructs in which axial load is distributed unevenly across the screws.^{85,121}

p1980 The bone fragments must be reduced prior to locking the plate, although newer designs include various adjunctive devices to assist in fracture reduction.^{42,121} Care must also be taken to avoid leaving gaps at the nonunion site, because the rigidity of the locking plate construct will maintain distraction at the site.¹²¹ In addition, locking plates are considerably more expensive than traditional plates, and they should therefore be reserved for use in cases that are not amenable to traditional plate-and-screw fixation.⁴²

p1990 The use of locking plates has been reported to be successful in the treatment of nonunions of the clavicle,¹⁶⁵ humerus,^{263,334} femur,² and distal femur²³ as well as in the treatment of prosthetic femoral nonunions.²⁵³

INTRAMEDULLARY NAIL FIXATION Intramedullary (IM) nailing is an excellent method of providing mechanical stability to a fracture nonunion of a long bone whose injuries have previously been treated by another method (removal of a previously placed nail followed by placement of a new nail is exchange nailing, a distinctly different technique discussed below).

IM nail fixation is particularly useful for lower extremity nonunions because of the strength and load-sharing characteristics of IM nails. IM implants are an excellent treatment option for osteopenic bone where purchase may be poor.

IM nail fixation as a treatment for nonunion is commonly combined with a biological method such as open bone grafting, IM bone grafting, or IM reaming. These techniques stimulate biological activity at the nonunion site, but IM nailing itself is strictly a mechanical method.

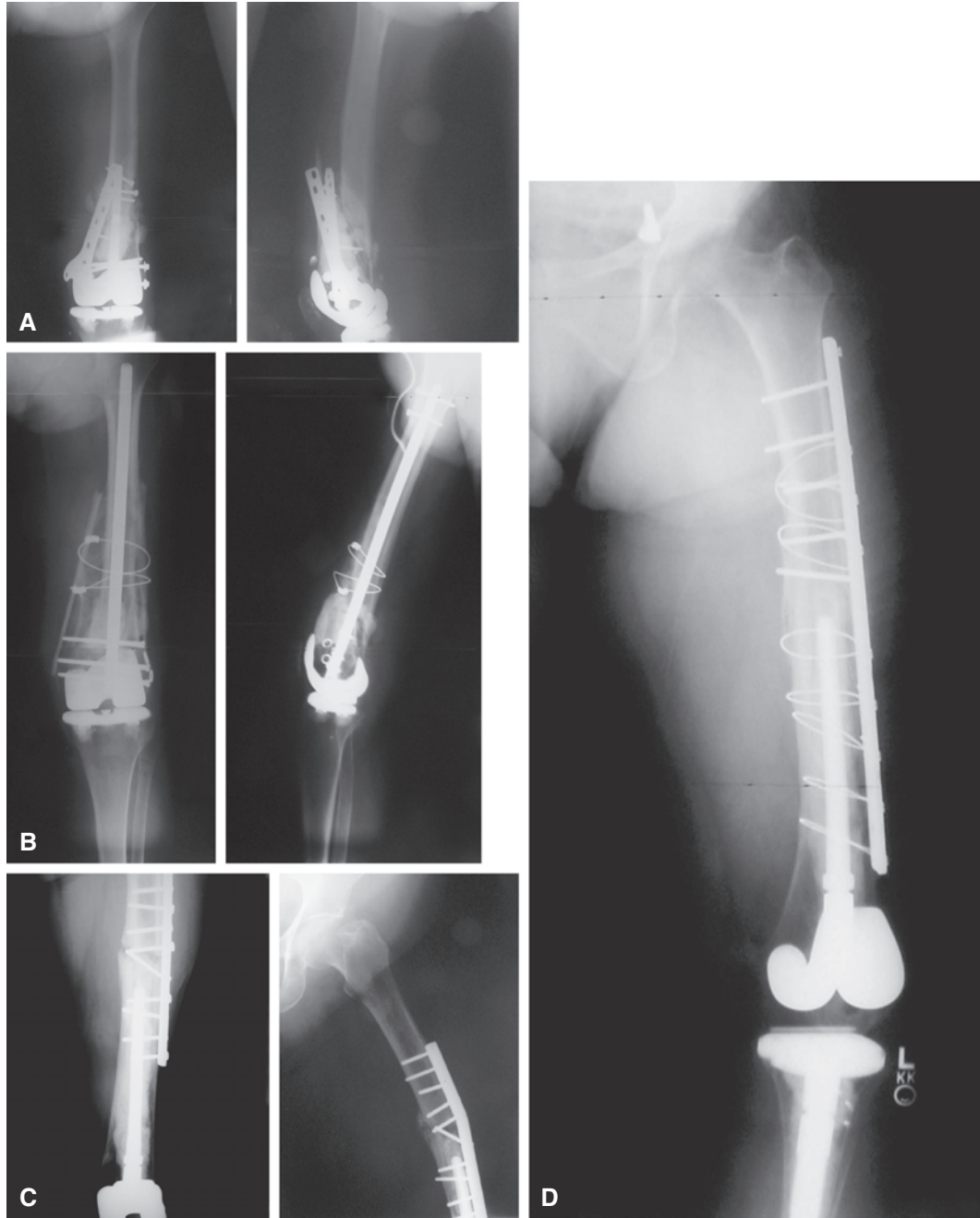Hypertrophic, oligotrophic, and atrophic nonunions, as well as synovial pseudarthroses, may be treated with IM nailing. IM nailing in cases with active infection has been reported^{164,167,196,296} but remains controversial. Because of the potential risk of seeding the medullary canal, and because safer options exist, we and others¹⁹¹ generally recommend against IM nailing in cases of active or prior deep infection. Exchange nailing in the face of infection is a different situation because the medullary canal has likely already been seeded and can therefore be appropriate in selected patients.

Differing opinions also exist regarding IM nailing in patients who have previously been treated with external fixation.^{27,148,189,192,198,257,338} The risk of infection following IM nailing in a patient with prior external fixation

f0610

FIGURE 22-61

A, Presenting radiograph of an 83-year-old man with a periprosthetic fracture nonunion of the femur. The patient was treated with intramedullary nail stabilization with allograft strut bone graft with circumferential cable fixation. **B**, Final radiographic result shows solid bony union and incorporation of the allograft struts. **C**, Presenting radiographs of an 80-year-old woman with multiple failed attempts at surgical reconstruction of a periprosthetic femoral nonunion. The patient was treated with plate stabilization with allograft strut bone graft with circumferential cable fixation. **D**, Final radiograph shows solid bony union.



t0100

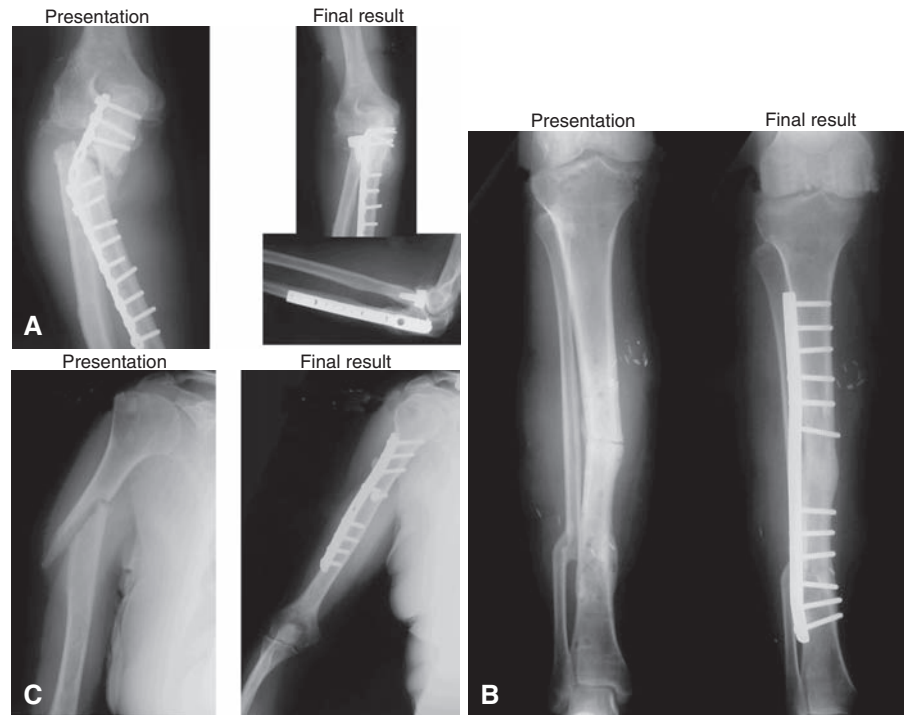
Table 22-10	
AO Concepts for Nonunion Treatment	
Stable internal fixation under compression	
Decortication	
Bone grafting in nonunions associated with gaps or poor vascularity	
Leaving the nonunion tissue undisturbed for hypertrophic nonunions	
Early return to function	

is related to a long duration (months) of external fixation, a short time span (days to weeks) from removal of external fixation to IM nailing, and a history of pin site infection (pin site sequestra on current radiographs).

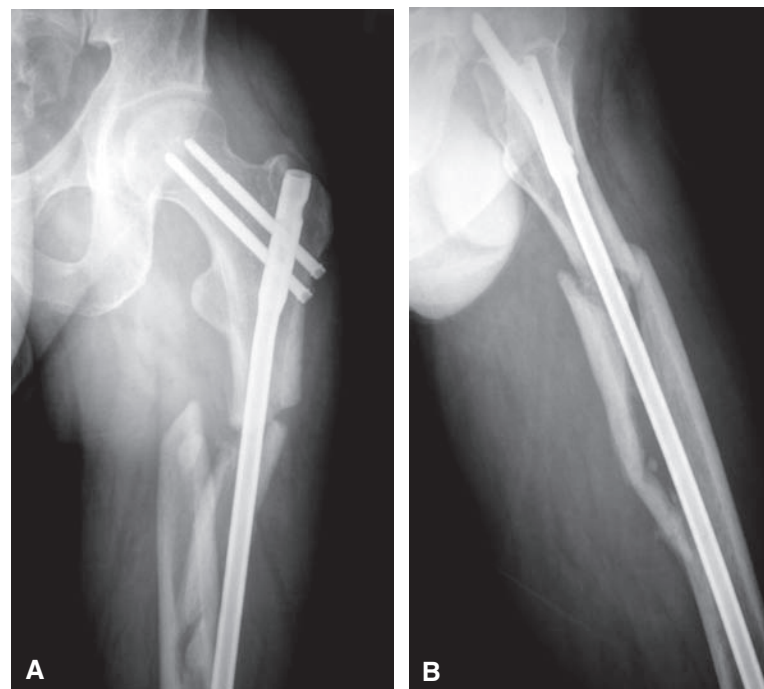
Other factors that likely are related to the risk of infection are related to the application of the external fixator: implant type (tensioned wires vs. half pins), surgical technique (intermittent low-speed drilling under constant irrigation decreases thermal necrosis of bone when placing half pins

p2050

- f0620 **FIGURE 22-62** **A**, Presenting and final radiographs of a proximal ulna nonunion in a 60-year-old man who had three prior failed attempts at reconstruction. Blade plate fixation provided absolute rigid stabilization and in conjunction with autogenous bone grafting led to rapid bony union. **B**, Presenting and final radiographs of a tibial shaft nonunion that had failed treatment with an external fixator. Plate-and-screw fixation with autogenous bone grafting led to successful bony union. **C**, Presenting and final radiograph of a humeral shaft fracture that had failed nonoperative treatment and had gone on to nonunion. Plate-and-screw fixation with autogenous bone grafting led to successful bony union.



- f0630 **FIGURE 22-63** **A** and **B**, Presenting radiographs of a 41-year-old man who 4 months after a high-energy femoral fracture treated at the time of injury by intramedullary nailing. **C** and **D**, The patient was treated with open reduction and internal fixation with locking plates, which led to successful bony union.



and wires), and implant location (implants that traverse less soft tissue create less local irritation).

p2060 A variety of other factors must be considered when treating long bone nonunions with IM nail fixation. First, the alignment of the proximal and distal fragments should be assessed on AP and lateral radiographs to determine whether closed passage of a guide wire will be possible. Second, plain radiographs and, when necessary, CT scans should be studied to determine whether the medullary canal is open or sealed at the nonunion site and whether it will allow passage of a guide wire and reamers. Use of T-handle reamers or a pseudoarthrosis chisel for closed recanalization is effective only when the proximal and distal fragments are relatively well aligned. If these methods fail, a percutaneously performed osteotomy (without wide exposure of the nonunion site), or percutaneous drilling of the medullary canals of both fragments, or both (using fluoroscopic imaging), may facilitate passage of the guide wire and nail (Fig. 22-64). Following the percutaneously performed osteotomy, deformity correction may be facilitated by the use of a femoral distractor or a temporary external fixator. Third, the fixation strategy using interlocking screws must be considered; the choices include static interlocking, dynamic interlocking, and no interlocking. This decision is based on a number of factors: nonunion type, the surface characteristics of the nonunion, the location and geometry of the nonunion, the importance of rotational stability, and others. Fourth, loading and bone contact at the nonunion site can be optimized by a few special techniques. When static locking is to be performed, distal locking followed by “backslapping” the nail (as if extracting it) followed by proximal locking may improve contact at the nonunion site. Some IM nails allow acute compression at the nonunion site during the operative procedure. In addition, a femoral distractor or a temporary external fixator may aid in compression or deformity correction, or both, at a nonunion site being stabilized with IM nail fixation (see Fig. 22-34). For tibial nonunions, partial excision of the fibula facilitates acute correction of tibial deformities as well as compression at the nonunion site during nail insertion and later during weight-bearing ambulation.

p2070 Some authors advocate exposure and open bone grafting for all nonunions being treated with IM nail fixation.^{227,296,342,343} Other authors recommend exposure of the nonunion site only in cases requiring hardware removal,^{196,198} deformity correction,^{196,198,277} “nonunion takedown,”¹⁶⁷ open recanalization of the medullary canal,¹⁹¹ and soft tissue release.¹⁹⁶ Still others,^{7,191,340} as do we, discourage routine open bone grafting of nonunion sites being treated with IM nail fixation. Closed nailing without exposure of the nonunion site has the following advantages: no damage to the periosteal blood supply, lower infection rate, and no disruption of the tissues at the nonunion site that have osteogenic potential.

p2080 In cases requiring a wide exposure of the nonunion site for open bone grafting, resection of bone, deformity correction, or hardware removal, we use other methods of fixation, such as plate and screws or external fixation to avoid impairing both the endosteal (IM nailing) and periosteal (open exposure of the nonunion site) blood supplies.

Exceptions for which we may somewhat reluctantly combine these methods include the following:

1. Nonviable nonunions in patients with poor bone quality, where bone grafting is needed to stimulate the local biology and nail fixation is mechanically advantageous o0050
2. Segmental nonunions with bone defects when we do not believe reaming will result in union and believe nailing is the best method to stabilize the segmental bone fragments o0060
3. Nonunions associated with deformities in noncompliant or cognitively impaired individuals where the biomechanical advantages of IM nail fixation are required (over plate fixation) and external fixation is a poor option o0070
4. Nonunions with large segmental defects where bulk cortical allograft and IM nail fixation are the chosen treatment (Fig. 22-65) o0080

Closed intramedullary bone grafting, as described by Chapman,⁴⁶ may be used in conjunction with nail fixation to treat diaphyseal defects. We have used this technique to treat nonunions of the femur and tibia with excellent results (Fig. 22-66). Grafting by means of IM reaming is another excellent method (discussed below with Exchange Nailing).

IM nail fixation as a treatment for tibial nonunions has healing rates reported to range from 92 to 100 percent.^{7,158,191,196,198,203,240,255,277,296,302,325,338} With the availability of specialized and custom-designed nails, the anatomic zone of the tibia that can be treated with IM nail fixation has expanded from that recommended by Mayo and Benirschke¹⁹³ in 1990. Each tibial nonunion should be evaluated on a case-by-case basis with templating performed when nail fixation is contemplated for proximal or distal diaphyseal or metaphyseal nonunions.

A situation worth noting is the slow or arrested proximal tibial regenerate following an Ilizarov lengthening or bone transport procedure. In a very few patients, we have treated this problem with external fixator removal; 6 to 8 weeks of casting and bracing (to allow healing of the pin sites); and reamed, statically locked IM nailing.

This protocol has been used only in patients who were poor candidates for open techniques (bone grafting, plate-and-screw fixation) because of soft tissue concerns (morbid obesity, multiple prior soft tissue reconstructions). Most regenerates fully mature 3 to 6 months following reamed nailing without development of infection (Fig. 22-67).

The clinical results of nail fixation for femoral nonunions have generally been favorable.^{19,48,100,158,196,326,343,344,346} Koval et al.,¹⁶⁷ however, reported a high rate of failure for distal femoral nonunions treated with retrograde IM nailing.

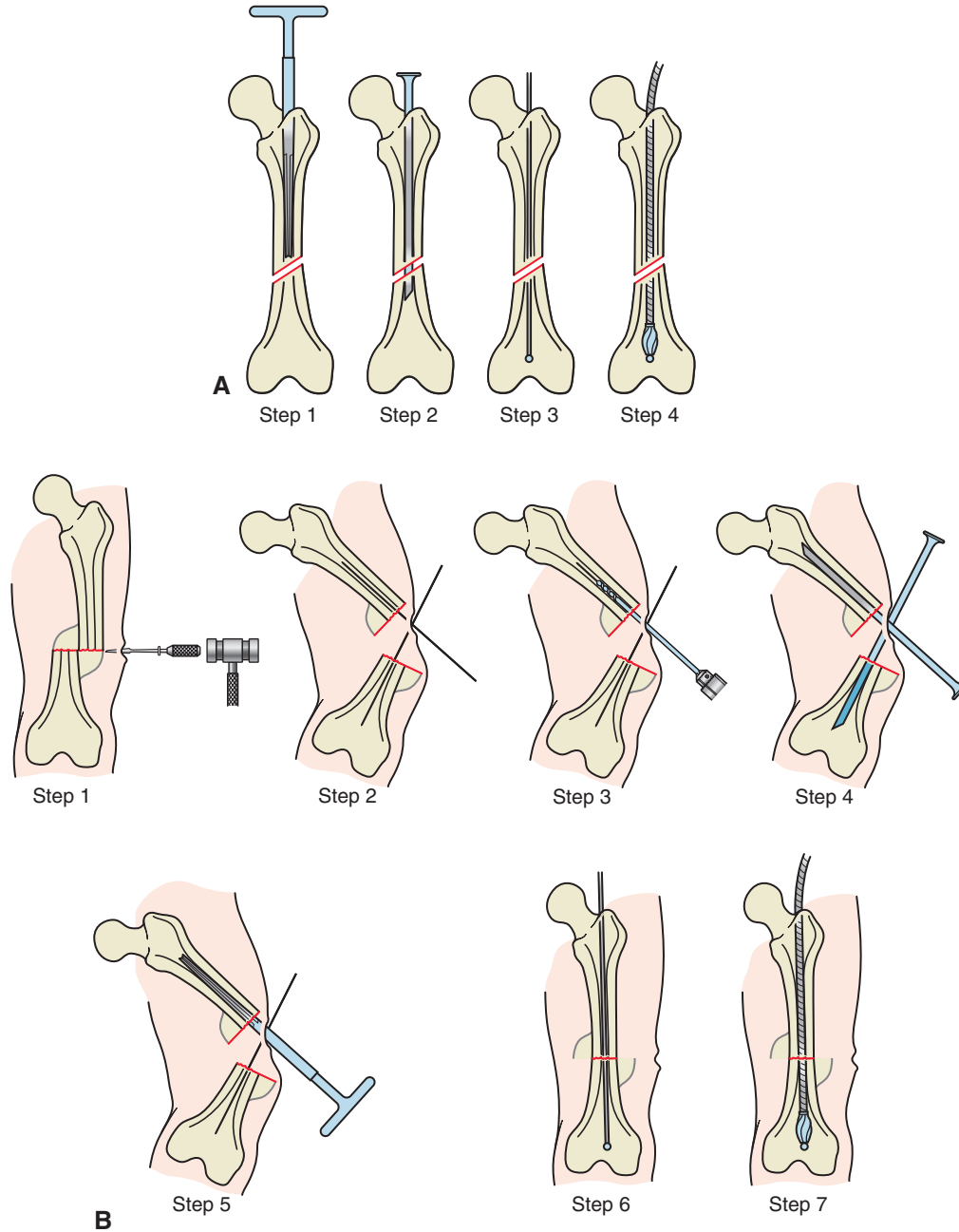
IM nail fixation as a treatment for nonunion has also been reported in the clavicle,²⁸ proximal humerus,²¹³ humeral shaft,^{187,342} distal humerus,²²⁷ olecranon,⁶⁶ and fibula.³

OSTEOTOMY An osteotomy is used to reorient the plane of the nonunion. Reorienting the angle of inclination of a nonunion from a vertical to a more horizontal position encourages healing by promoting compressive

f0640

FIGURE 22-64

Procedure for recannulating a sealed off medullary canal associated with a nonunion to be treated with intramedullary nail insertion. **A**, Without significant deformity (proximal and distal canals aligned). Step 1: Manual T-handle reaming. Step 2: Pseudarthrosis chiseling. Step 3: Passage of a bulb tip guide rod. Step 4: Flexible reaming. **B**, With significant deformity (proximal and distal canals are not aligned). Step 1: Percutaneous osteotomy. Step 2: Percutaneous guide wire placement (fluoroscopically guided) into the proximal and distal canals. Step 3: Cannulated drilling of the proximal and distal canals. Step 4: Manual T-handle reaming. Step 5: Pseudarthrosis chiseling. Step 6: Passage of a bulb tip guide rod. Step 7: Flexible reaming.



forces across the nonunion site. The osteotomy can be performed either through the nonunion site, such as trimming the bone ends to decrease the inclination, or adjacent to the nonunion site, such as Pauwels' osteotomy, for a femoral neck nonunion^{16,188,235} or a dome osteotomy for cubitus valgus deformity associated with lateral humeral condylar nonunion.³¹²

EXTERNAL FIXATION External fixation has primarily been used to treat infected nonunions of the femur,³¹⁸ tibia,^{50,91,232} and humerus.^{51,176,240} The method is commonly combined with serial débridement, antibiotic beads, soft tissue coverage procedures, and bone grafting. The Ilizarov method of external fixation is discussed below in Methods That Are Both Mechanical and Biological. p2160 s0760

s0770 **BIOLOGICAL METHODS**

p2170 Biological methods stimulate the local biology at the nonunion site. These methods may be used alone but typically are combined with a mechanical method.

s0780 **NONSTRUCTURAL BONE GRAFTS**s0790 **Autogenous Cancellous Graft**

p2180 Autogenous cancellous bone grafting remains an important weapon in the trauma surgeon's armamentarium. Successful treatment of oligotrophic, atrophic, and infected nonunions, as well as synovial pseudarthroses, often depends on copious autologous cancellous bone grafting.

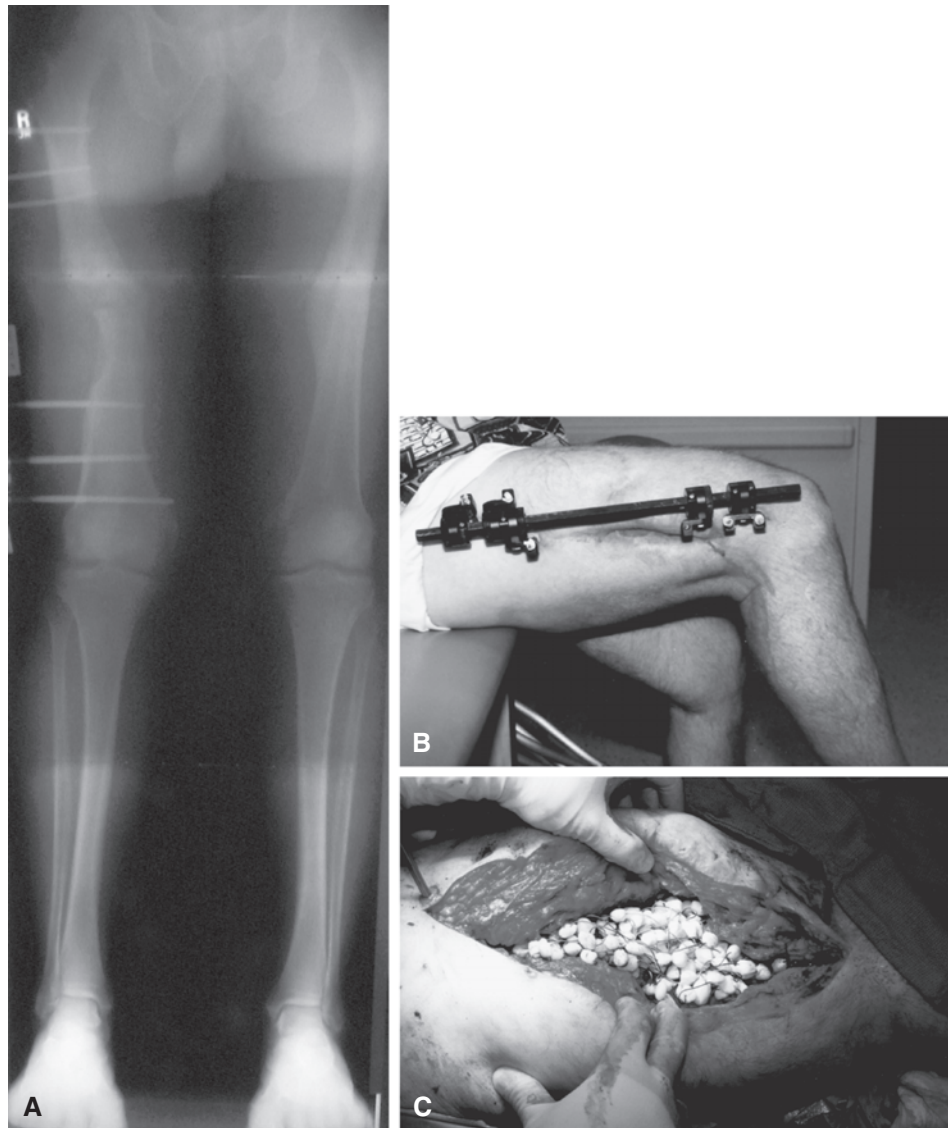
p2190 Cancellous autograft is osteogenic, osteoconductive, and osteoinductive. The graft stimulates the local biology in viable nonunions that have poor callus formation and

in nonviable nonunions. The graft's initially poor structural integrity improves rapidly during osseointegration.

Cancellous autograft is not necessary in the treatment of hypertrophic nonunions, which are viable and often have abundant callus formation. p2200

Oligotrophic nonunions are viable and typically arise as a result of poor bone-to-bone contact. Cancellous autograft bone promotes bridging of un-united bone gaps. The decision about whether to bone-graft an oligotrophic nonunion is determined by the treatment strategy. If the strategy involves operative exposure of the nonunion site (e.g., plate-and-screw fixation), then decortication and autogenous bone grafting is recommended. If the strategy does not involve exposure of the nonunion site (e.g., compression via external fixation), we do not routinely bone-graft. p2210

f0650 **FIGURE 22-65** **A**, Presenting radiograph of an infected femoral nonunion resulting from an open femur fracture 32 years earlier. This 51-year-old man had undergone more than 20 prior attempts at surgical reconstruction, the most recent being external fixation and bone grafting performed at an outside facility. **B**, Clinical photograph at the time of presentation. **C**, Clinical photograph showing antibiotic beads in situ.

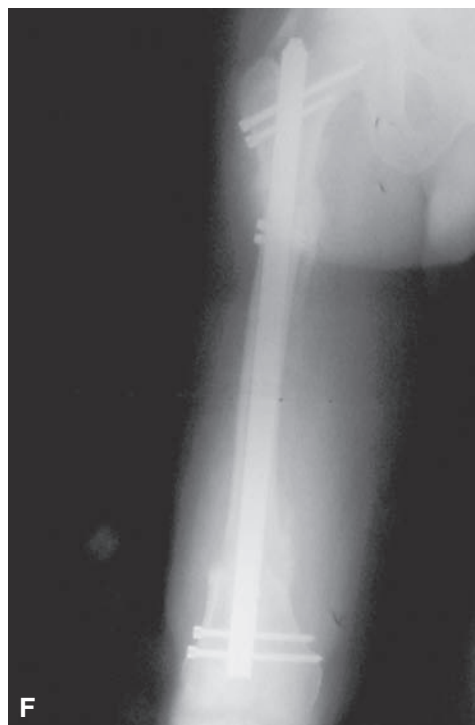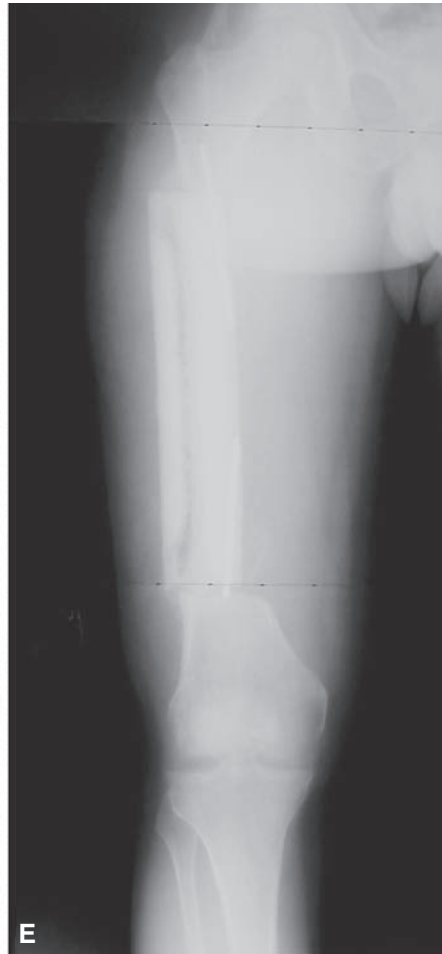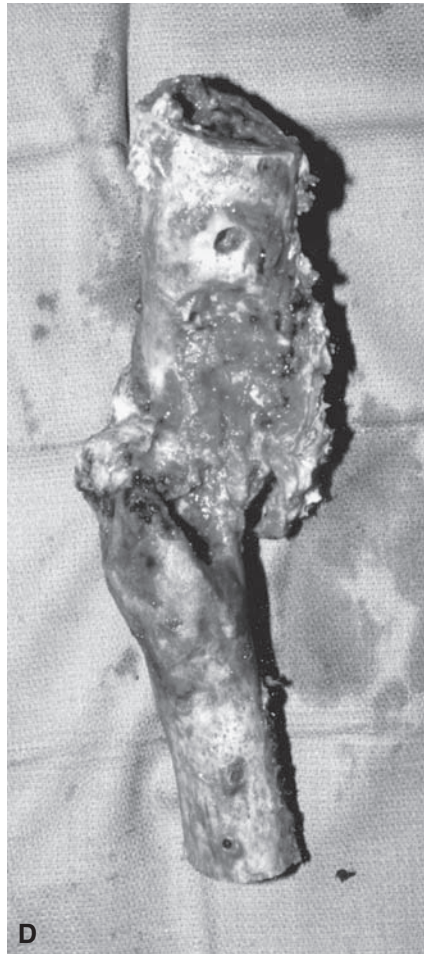


(Continued)

f9010

FIGURE 22-65

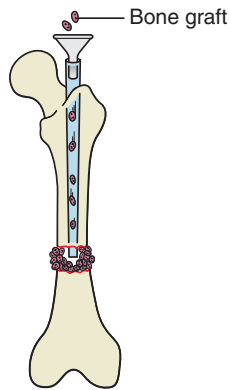
(Continued) **D**, Gross specimen. **E**, Radiograph following radical resection shows a bulk antibiotic spacer that remained in situ for 3 months. **F**, Radiographs 7 months following reconstruction using a bulk femoral allograft and a custom two-piece femoral nail (the proximal portion of the nail is an antegrade reconstruction nail; the distal portion of the nail is a retrograde supracondylar nail). **G**, Clinical photograph 7 months following reconstruction.



f0660

FIGURE 22-66

Closed intramedullary autogenous cancellous bone grafting can be used to treat diaphyseal bony defects. Autogenous cancellous bone harvested from the iliac crest is delivered to the defect via a tube positioned in the medullary canal.



Atrophic and infected nonunions are nonviable and incapable of callus formation. They are typically associated with segmental bone defects. Recommendations vary regarding the maximum size of a complete segmental defect that will unite following autogenous cancellous bone grafting (see Table 22-6).^{55,91,95,116,185,190,232} Our recommendations for segmental bone defects are shown in Table 22-7.

p2220

Synovial pseudarthrosis is typically treated with excision of the pseudarthrosis tissue and opening of the medullary canal. Decortication and autogenous cancellous bone grafting are recommended to encourage healing.

p2230

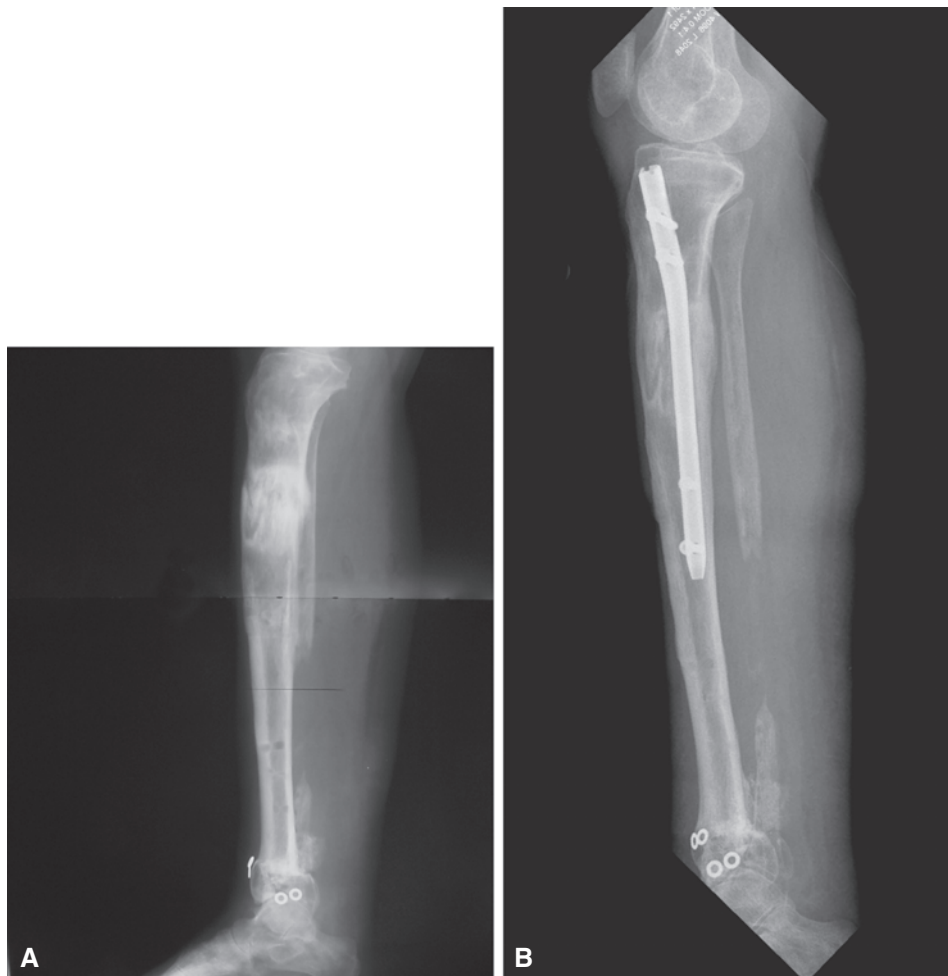Cancellous autogenous bone graft may be harvested from the iliac crest, the distal femur, the greater trochanter, the proximal tibia, and the distal radius. The iliac crest yields the most osseous tissue. The posterior iliac crest yields dramatically more bone, less postoperative pain, and a lower risk of postoperative complications in comparison to the anterior iliac crest.⁶ The posterior iliac crest bone of intramembranous origin (ilium) appears to be

p2240

f0670

FIGURE 22-67

A, Radiograph of the proximal tibial regenerate in a 54-year-old woman who had undergone bone transport for an infected distal tibial nonunion. Although the technique led to solid bony union of the distal tibial nonunion site, her bony regenerate failed to mature and was mechanically unstable. This patient was treated with removal of her external fixator and 8 weeks of bracing. Following complete healing of the pin sites, a reamed, statically locked, custom (short) intramedullary nail was placed. **B**, Follow-up radiograph at 8 months after intramedullary nailing shows solid healing and maturation of the proximal tibial regenerate.



- more osteoconductive than bone of enchondral origin (tibia, femur, radius).²⁴¹
- p2250 Autogenous cancellous autograft techniques for the treatment of nonunions include the following:
- u0010 Papineau technique (open cancellous bone grafting)²²⁶
 - u0020 Posterolateral grafting of the tibia
 - u0030 Anterior grafting of the tibia (following soft tissue coverage)
 - u0040 Intramedullary grafting⁴⁶
 - u0050 Intramedullary reaming
 - u0060 Endoscopic bone grafting¹⁶⁴
 - u0070 Percutaneous bone grafting^{25,130,131,159}
 - u0080 Furthermore, various protocols for the timing of bone grafting exist. These include
 - u0090 Early bone grafting without prior bony débridement or excision
 - u0100 Early open bone grafting following débridement and skeletal stabilization
 - u0110 Delayed bone grafting following débridement, skeletal stabilization, and soft tissue reconstruction.
- p2260 The disadvantages of autogenous bone grafting are the limited quantity of bone available for harvesting and donor site morbidity and complications.
- s0800 **Allogenic Cancellous Graft**
- p2270 In the treatment of nonunions, allogenic cancellous bone is commonly mixed with autogenous cancellous bone graft or bone marrow. Since allogenic cancellous bone functions primarily as an osteoconductive graft, mixing it with autograft enhances the graft's osteoinductive and osteogenic capacity. Combining cancellous allograft and autograft also increases the volume of graft available to fill a large skeletal defect. Little is known about using allograft cancellous bone alone to treat nonunions. We do not recommend using allogenic cancellous bone (alone or mixed with cancellous autograft) in patients with any history of recent or past infection associated with their nonunion.
- p2280 Allogenic bone can be prepared in three ways: fresh, fresh-frozen, and freeze-dried. Fresh grafts have the highest antigenicity. Fresh-frozen grafts are less immunogenic than fresh grafts and preserve the graft's bone morphogenetic proteins (BMPs). Freeze-dried grafts are the least immunogenic, have the lowest likelihood of viral transmission, are purely osteoconductive, and have the least mechanical integrity.
- s0810 **Bone Marrow**
- p2290 Bone marrow contains osteoprogenitor cells capable of forming bone.^{130,131} Animal models of fracture and nonunion have shown enhanced healing with bone marrow grafting,^{224,311} especially when demineralized bone matrix (DBM) is mixed with bone marrow.³¹¹ Injection of marrow-derived mesenchymal progenitor cells also showed enhanced bone formation during distraction osteogenesis in a rat model.²⁵⁴
- p2300 Percutaneous bone marrow injection as a clinical treatment for fracture nonunion has been reported with favorable results.^{60,61,295} Percutaneous bone marrow grafting involves harvesting autogenous bone marrow from the anterior or posterior iliac crest with a trochar needle.¹³¹

We prefer the posterior iliac crest, an 11-gauge, 4-in. Lee-Lok needle (Lee Medical Ltd., Minneapolis, MN), and a 20-mL heparinized syringe (Fig. 22-68). Small aliquots are harvested to increase the concentration of osteoblast progenitor cells. The preferred volume of bone marrow aspirated from each site is 2-mL to 4-mL.²¹² We harvest marrow in 4-mL aliquots, changing the position of the trochar needle in the posterior iliac crest between aspirations. Depending on the size and location of the nonunion site, we harvest 40 to 80 mL of marrow. Marrow is injected into the nonunion site percutaneously under fluoroscopic imaging using an 18-gauge spinal needle. The technique is minimally invasive, has low morbidity, and can be performed on an outpatient basis.¹³¹ The technique works well for nonunions with small defects (<5 mm) that have excellent mechanical stability (see Fig. 22-68). Percutaneous marrow injection also enhances healing at the docking site in cases of Ilizarov bone transport.

Bone Graft Substitutes

Bone graft substitutes, such as calcium phosphate, calcium sulfate, hydroxyapatite, and other calcium-based ceramics, may have a future role in the treatment of nonunions. Some of these materials may be impregnated with antibiotic and used in the treatment of infected nonunions.^{22,195} Some may be combined with autogenous bone graft to expand the volume of graft material.^{30,282} To date, the efficiency of and indications for these substitutes in the treatment of nonunions remain unclear.

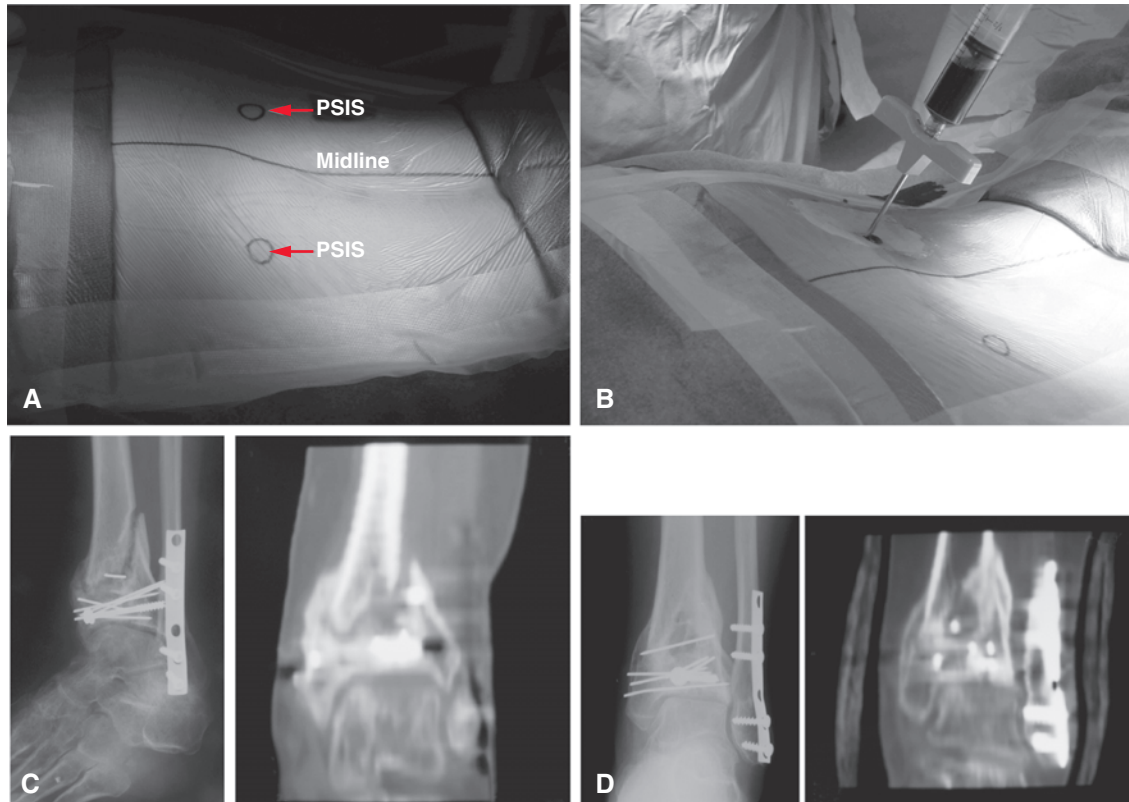
Growth Factors

Ongoing research in the area of growth factors holds promise for rapid advancement in the treatment of fracture nonunions.^{75,77,81,82,86,106}

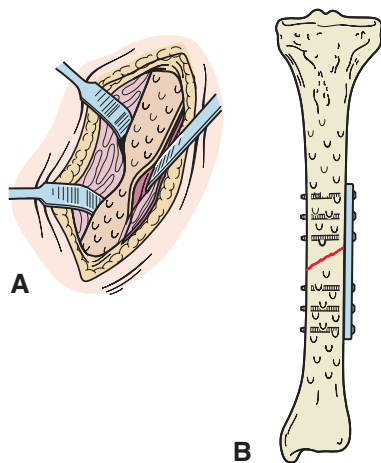
DECORTICATION Shingling, as described by Judet et al.^{150,151} and Phemister²³⁹ (Fig. 22-69), entails the raising of osteoperiosteal fragments from the outer cortex or callus from both sides of the nonunion using a sharp osteotome or chisel. Using an osteotome, thin (2 to 3 mm) fragments of cortex each measuring approximately 2 cm in length are elevated. The resulting decorticated region measures approximately 3 to 4 cm in length on either side of the nonunion and involves approximately two thirds of the bone circumference. The periosteum and muscle, which remain attached and viable, are then retracted with a Hohmann retractor. This increases the surface area between the elevated shingles and the decorticated cortex into which cancellous bone graft can be inserted to stimulate bony healing.

If the bone is osteoporotic, shingling may weaken the thin cortex and should therefore be avoided. In addition, shingling should not be performed over the area of the bone fragments where a plate is to be applied. Petaling,²¹⁰ or "fish scaling" (see Fig. 22-69), is performed with a tiny gouge. Once elevated, the osteoperiosteal flakes resemble the petals of a flower or scales of a fish. Alternatively, a small drill bit cooled with irrigation can be used to drill multiple holes. Petaling or drilling is performed over a region 3 to 4 cm on either side of the nonunion. These techniques promote revascularization of the cortex, especially when combined with cancellous bone grafting.

f0680 **FIGURE 22-68** **A**, Clinical photograph showing the bony landmarks for harvesting bone marrow from the posterior iliac crest. The patient has been positioned prone. **B**, Marrow being harvested in 4-mL aliquots. **C**, Presenting radiograph and CT scan of a 39-year-old woman with a stable oligotrophic distal tibial nonunion. **D**, Radiograph and CT scan 4 months following percutaneous marrow injection shows solid bony union.



f0690 **FIGURE 22-69** Decortication techniques. **A**, Shingling. **B**, Fish scaling (petaling).



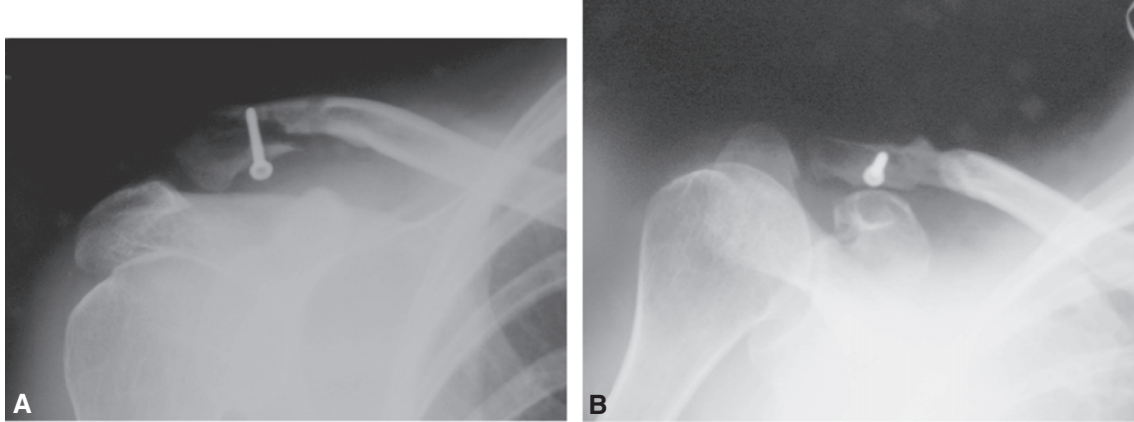
s0850 **ELECTROMAGNETIC, ULTRASOUND, AND SHOCK-WAVE STIMULATION** Electrical stimulation of nonunions by invasive and noninvasive methods has gained popularity since the 1970s,²³¹ with some practitioners reporting success in a high percentage of cases.³⁰⁰ We have been delighted by successes in a number of cases (Fig. 22-70).

Devices available to treat nonunions via electrical stimulation are of three varieties: constant direct current, time-varying inductive coupling (including pulsed electromagnetic fields), and capacitive coupling.^{1,56,118,214} Direct current lowers the partial pressure of oxygen and increases proteoglycan and collagen synthesis.²¹⁴ Time-varying inductive coupling affects the synthesis and function of growth factors and other cytokines, particularly TGF- β , that modulate chondrocytes and osteoblasts.^{56,214} Pulsed electromagnetic fields also induce mRNA expression of bone morphogenetic proteins, producing an osteoinductive effect.⁵⁶ Capacitive coupling induces a proliferation of bone cells that is thought to be related to the activation of voltage-gated calcium channels increasing prostaglandin E₂, cytosolic calcium, and calmodulin.²¹⁴

Electrical stimulation does not correct deformities and usually requires a long period (3 to 9 months) of non-weight-bearing and cast immobilization, which may give rise to muscle and bone atrophy and joint stiffness. Electrical stimulation may be used to treat stiff nonunions without significant deformity or bone defect. The method is seldom effective for atrophic nonunions, infected nonunions, synovial pseudarthroses, nonunions with gaps of more than 1 cm, or lax nonunions.²¹⁴

Ultrasound stimulates bone healing by activating potassium ions, calcium incorporation in differentiating cartilage and bone cells, adenylate cyclase activity, and various

f0700 **FIGURE 22-70** **A**, Presenting radiograph of a 40-year-old woman 26 months following open reduction internal fixation of a distal clavicle fracture. This patient did not wish any type of surgical intervention and therefore was treated with external electrical stimulation. **B**, Radiograph following 8 months of electrical stimulation shows solid bony union.



cytokines.^{214,228,278} Ultrasound therapy has been an FDA-approved treatment for fracture healing since 1994 and for the stimulation of healing of established nonunions since February 2000.²¹⁴ Several studies of ultrasound therapy in the treatment of nonunion have reported bony union rates ranging from 85 to 91 percent.^{108,215,278} According to Parvizi and Vegari, ultrasound may be used to treat stiff atrophic, oligotrophic, or hypertrophic nonunions that have no significant deformity.²²⁸ It is inappropriate for infected nonunions, nonunions with a large segmental defect, and lax nonunions.

p2390 High-energy extracorporeal shock wave therapy for nonunions has been reported by a number of investigators, with union rates exceeding 75 percent.^{289,292,319,322} The technique may be more effective in pseudarthroses or nonunions showing uptake on technetium bone scan.²⁶⁶ Atrophic nonunions may show no signs of healing until more than 6 months after the initial shock wave application.³²² It should not be used when the gap at the nonunion site is greater than 5 mm; when open physes, alveolar tissue, brain or spine, or malignant tumor are in the shock wave field; or in patients with coagulopathy or pregnancy.²⁸⁹

s0860 **METHODS THAT ARE BOTH MECHANICAL AND BIOLOGICAL**

s0870 p2400 **STRUCTURAL BONE GRAFTS** Several types of structural bone grafts are available. Each type has specific advantages and disadvantages (Table 22-11).

p2410 *Vascularized autogenous cortical bone grafts* provide structural integrity and living osseous tissue to the site of bony defects. Some vascularized grafts respond to functional loading via hypertrophy,^{45,139} thus increasing in strength over time. Vascularized bone grafts may be obtained from several sites for the treatment of nonunions of various bones,^{64,70,281,287,330,340,349} but the vascularized fibula is currently preferred because of its shape, strength, size, and versatility.^{112,137,149,178,279}

p2420 *Nonvascularized autogenous cortical bone grafts* provide structural integrity using the patient's own tissue to the site of bony defects.

Bulk cortical allografts may be used to reconstruct large post-traumatic skeletal defects⁵³ (see Figs. 22-64 and 22-70). Bone of virtually every shape and size from the bone bank is available, permitting reconstruction in most anatomic locations. Graft fixation may be achieved using a variety of methods; we prefer intramedullary fixation when possible because of its ultimate strength, load-sharing characteristics, and protection of the graft. Bulk allografts can be used in four ways: intercalary, alloarthro-
p2430
p2440

Infected nonunions may be treated with bulk allograft after the infected cavity has been débrided and sterilized. For infected nonunions with massive defects, we perform serial débridement with antibiotic bead exchanges until the cavity is culture negative. A custom-fabricated antibiotic-impregnated PMMA spacer is then implanted, and the soft tissue envelope is closed or reconstructed. At a minimum of 3 months, the spacer is removed and the defect is reconstructed using bulk cortical allograft (Figs. 22-64 and 22-72). Active infection is an absolute contraindication to bulk cortical allograft.

Strut cortical allografts may be used to reconstruct partial (incomplete) segmental defects, reconstruct complete segmental defects in certain cases, augment fixation and stability in osteopenic bone,³²³ and augment stability in periprosthetic nonunions (see Fig. 22-61).

Intramedullary cortical allografts are typically used for long bone nonunions associated with osteopenia where the method of treatment is plate-and-screw fixation with cancellous autografting. The technique is particularly useful for humeral nonunions in elderly patients with osteopenic bone who have had multiple prior unsuccessful treatments (Fig. 22-73).

Mesh cage–bone graft constructs are a relatively new technique for treating segmental long bone defects.⁵⁹ The segmental defect is spanned using a titanium mesh cage (DuPuy Motech, Warsaw, IN) of slightly larger diameter than the adjacent bone. The cage is packed with allogenic cancellous bone chips and demineralized bone matrix. This construct is reinforced by an IM nail traversing the mesh cage–bone graft construct.

t0110

Table 22-11			
Types of Structural Bone Graft			
Type of Bone Graft	Potential Harvest Site	Advantages	Disadvantages
Vascularized autogenous cortical bone graft	Fibula ^{330,340,349}	Immediate structural integrity	Technically demanding
	Iliac crest ²⁸¹	One-stage procedure	Propensity for fracture fatigue, particularly in lower extremity applications
	Ribs ³³⁰	Potential for graft hypertrophy	Prolonged non-weight-bearing
		Ability to span massive segmental defects	Poorer results in patients with a history of infection ¹²³
			Donor site morbidity: pain, neurovascular injury, joint instability or limited motion
			Fixation problems with the defect is periarticular
			Contraindicated for children
Nonvascularized Autogenous cortical bone graft	Fibula	Can be used to reconstruct large defects	Prolonged non-weight-bearing
	Tibia		Prolonged support required in upper extremity applications
	Iliac crest		Donor site morbidity, including fracture for grafts from the tibia
			Graft weakening during revascularization (years)
			Propensity for fatigue fracture
Bulk cortical allograft	Virtually unlimited	Less technically demanding than vascularized grafts	Infection
		No donor site morbidity	Fatigue fracture
		Can be used in four ways: intercalary, alloarthrodeic, osteoarticular, and alloprosthetic	Nonunion at the host-graft junction
			Disease transmission from donor to recipient
Strut cortical allograft	Virtually unlimited	Versatility; may be used to treat partial (incomplete) segmental defects and complete segmental defects, augment fixation and stability in osteopenic bone, and augment stability in periprosthetic nonunions	Infection
			Fatigue fracture
			Nonunion at the host-graft junction
			Disease transmission from donor to recipient
Intramedullary cortical allograft	Virtually unlimited	Used in long bone nonunions with osteopenia	Infection
		Augments stability by acting like an intramedullary nail	Fatigue fracture
		Improves screw purchase; screws each traverse four cortices	Nonunion at the host-graft junction
			Disease transmission from donor to recipient

[Au1]

s0880p2480 **EXCHANGE NAILING** IM nail fixation, a purely mechanical treatment method, is distinguished from exchange nailing in that the latter is a method that is both mechanical and biological.

s0890 **Technique**

p2490 By definition, exchange nailing requires the removal of a previously placed IM nail. With a nail already spanning the nonunion site, the problem of a sealed-off medullary

canal is not an issue. Additionally, the medullary canal is already known to accept passage of an IM nail, unless the nail has broken and there has been progressive deformity over time. Such a case may require extensive bony and soft tissue dissection at the nonunion site, so other treatment options may need to be considered.

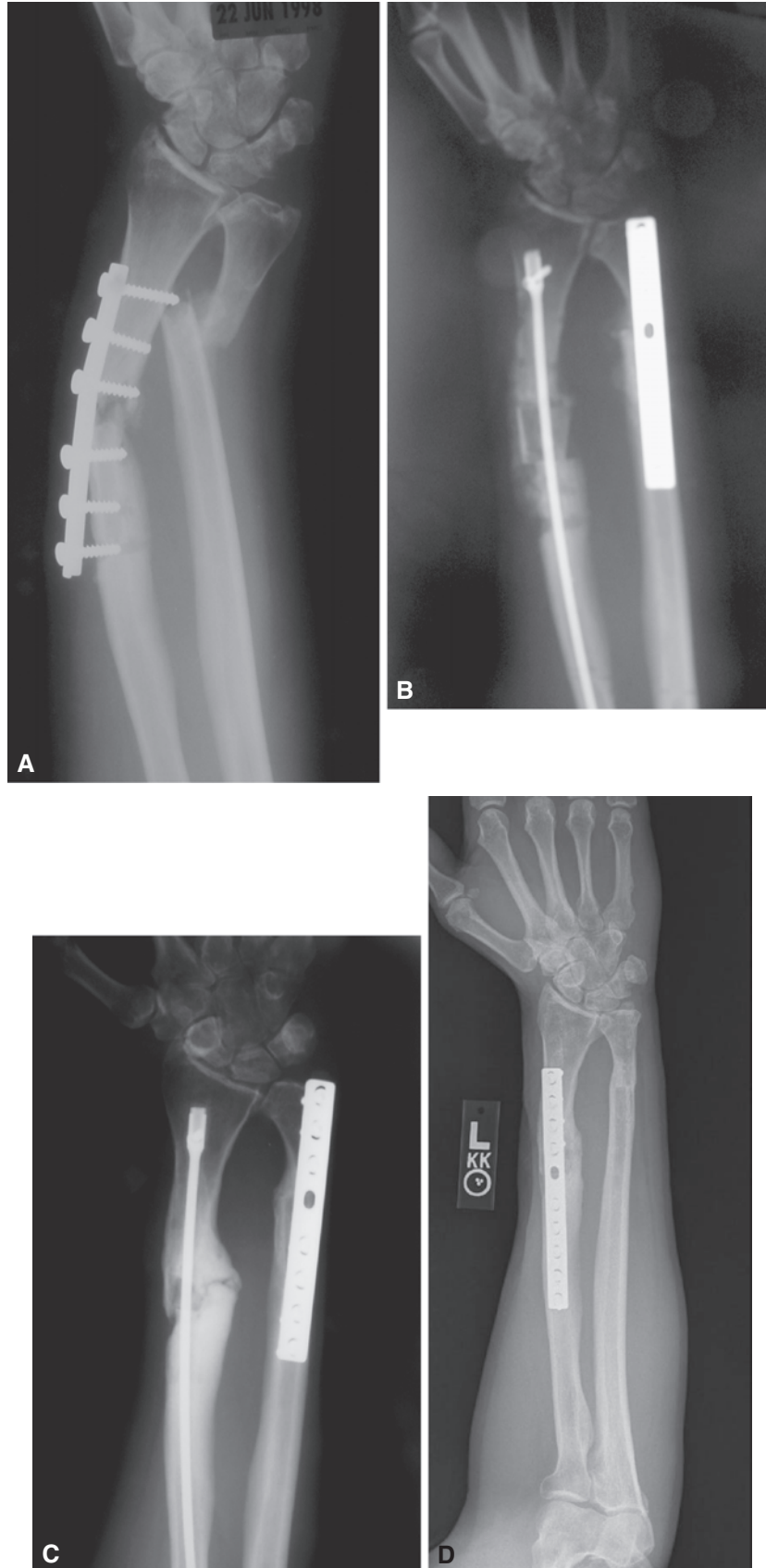Once the previously placed nail has been removed, the medullary canal is reamed with progressively larger reamer tips in 0.5-mm increments until bone is observed in the

p2500

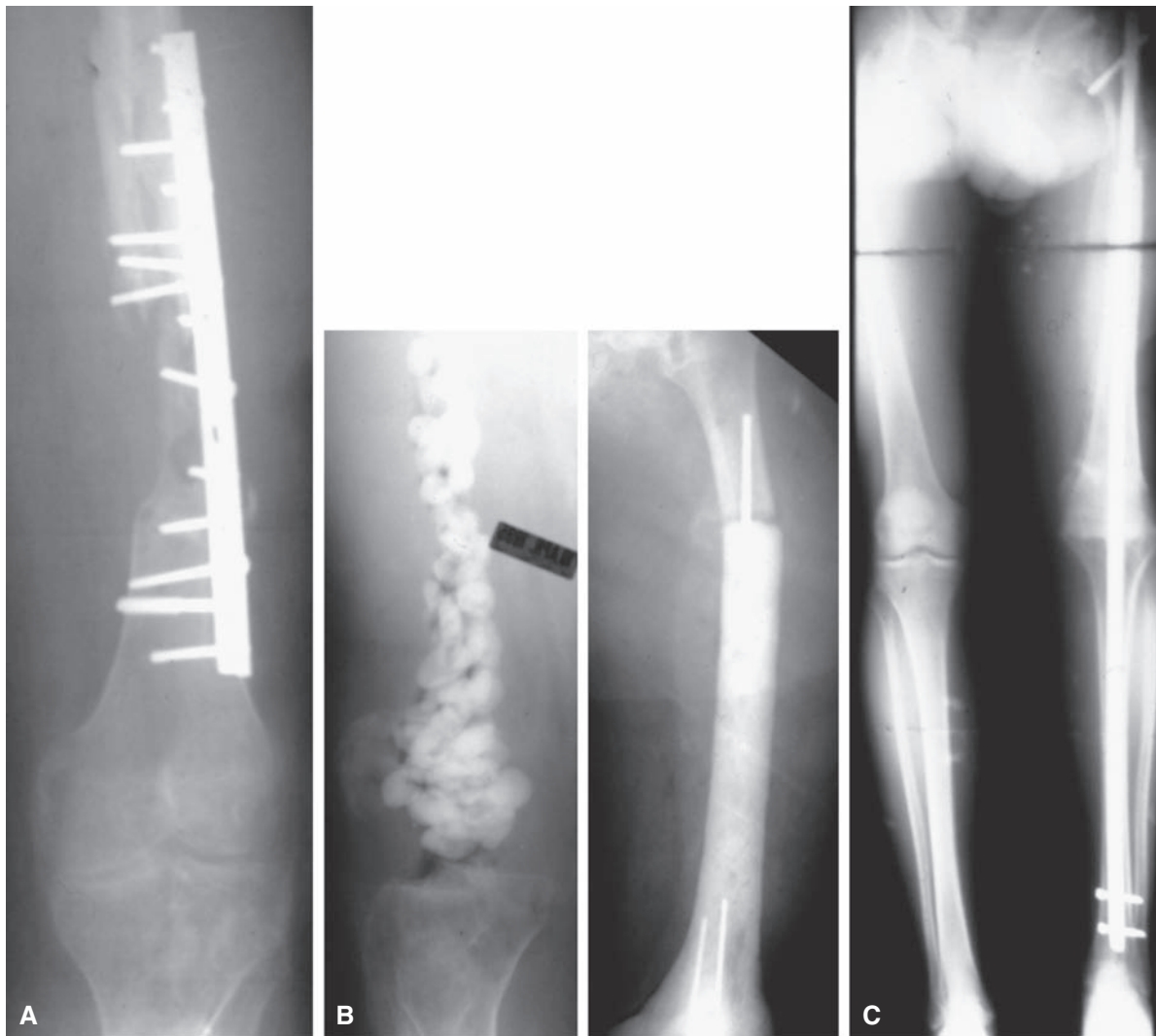
f0710

FIGURE 22-71

A, Presenting radiograph of a 25-year-old man treated with open reduction internal fixation of an open femur fracture taken 16 months following the injury. Clinical examination revealed gross purulence and exposed bone at the nonunion site with global knee joint instability and an arc of knee flexion/extension of approximately 20°. Aspiration of the knee yielded frank pus. **B**, Radiographs following radical débridement with placement of antibiotic beads and later an antibiotic spacer. **C**, Follow-up radiograph 6 years after alloarthrodesis using a bulk cortical allograft and a knee fusion nail shows solid bony incorporation. The patient is fully ambulatory, is without pain, and has no evidence of infection.



f0720 **FIGURE 22-72** **A**, Presenting radiograph of a 45-year-old man 7 months following open reduction internal fixation of a both-bone forearm fracture. This patient had an open wound draining purulent material over the radius. The patient was treated with serial débridement and antibiotic beads. Following serial débridement, the patient was left with a segmental defect of the radius. **B**, Radiograph following placement of a bulk cortical allograft over an intramedullary nail and plate-and-screw fixation of the ulna. **C**, Follow-up radiograph at 11 months after reconstruction shows solid union of the proximal host-graft junction but a hypertrophic nonunion of the distal host-graft junction of the radius. The hypertrophic nonunion was treated with compression plating (without bone grafting). **D**, Final radiograph 14 months following compression plating shows solid bony union.



flutes of the reamers. As a general rule, we try to use an exchange nail that is 2 to 4 mm in diameter larger than the previous nail, and we over-ream 1 mm larger than the new nail. Reaming, therefore, typically proceeds to a reamer tip size 3 to 5 mm larger than the removed nail.

p2510 Following reaming, a larger diameter nail is inserted. We prefer to use a closed technique to preserve the periosteal blood supply. Closed nailing likely also lessens the risk of infection. Provided that good bony contact exists at the nonunion site, we statically lock exchange nails, although many authors do not.^{62,122,308,335,346} In most instances, we do not favor partial excision of the fibula with exchange nailing of the tibia because it diminishes stability of the construct.

Modes of Healing

Exchange nailing stimulates healing of nonunions by improving the local mechanical environment in two ways and by improving the local biological environment in two ways (Fig. 22-74).

The first mechanical benefit is that reaming to enlarge the medullary canal allows a larger diameter nail, which is stronger and stiffer. The stronger, stiffer nail augments stability, which promotes bony union. The second mechanical benefit is that reaming widens and lengthens the isthmus portion of the medullary canal, which increases the endosteal cortical contact area of the nail.

The first biological benefit is that the reaming products act as local bone graft at the nonunion site to stimulate

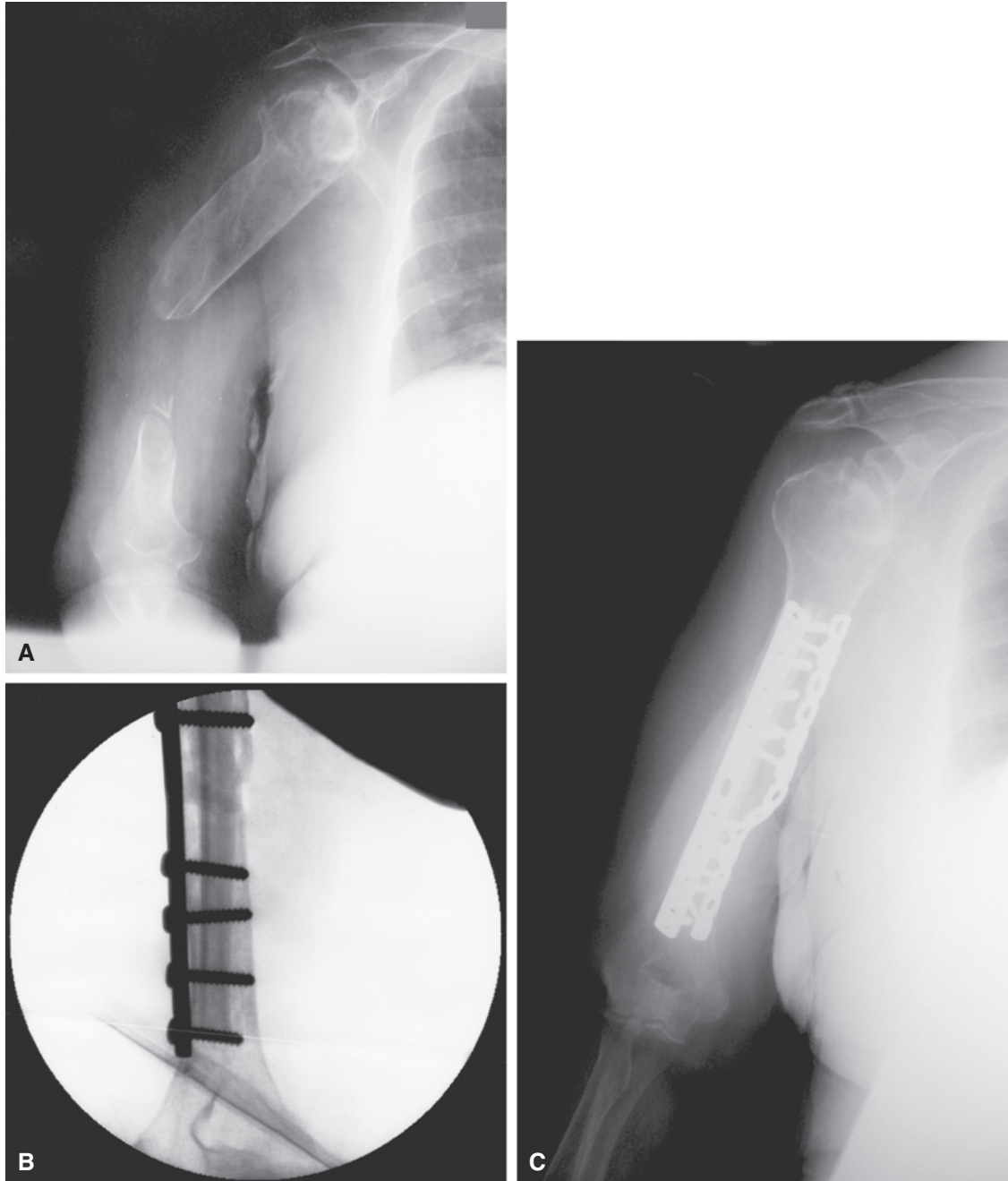
s0900

p2520

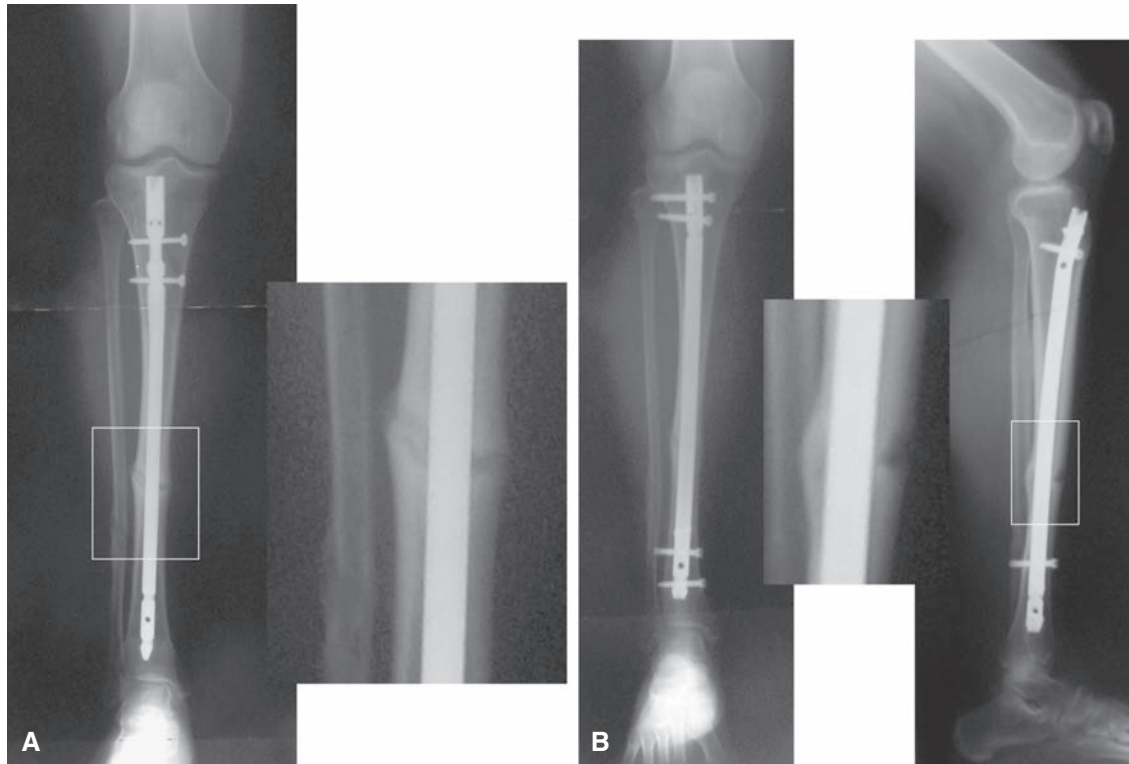
p2530

p2540

- f0730 **FIGURE 22-73** **A**, Presenting radiograph of an 83-year-old woman 15 months following a humeral shaft fracture. The patient found this humeral nonunion painful and debilitating. Because of the patient's profound osteopenia, she was treated with an intramedullary cortical fibular allograft and plate-and-screw fixation. **B**, Intraoperative fluoroscopic image showing positioning of the intramedullary fibula. **C**, Final radiograph 7 months following reconstruction shows bony incorporation without evidence of hardware loosening or failure. At follow-up, the patient was without pain and had marked improvement in function.



f0740 **FIGURE 22-74** **A**, Presenting radiograph of a 51-year-old woman 29 months following intramedullary nail fixation of an open tibia fracture. **B**, Five months following exchange nailing, the tibia is solidly united.



medullary healing. The second biological benefit is that medullary reaming results in a substantial decrease in endosteal blood flow.^{35,119,146,217,301} This loss of endosteal blood flow stimulates a dramatic increase in both periosteal flow²⁵¹ and periosteal new bone formation.⁶⁷

p2550 These mechanical and biological effects of exchange nailing make it applicable for both viable and nonviable nonunions.

s0910 **Other Issues**

p2560 Three noteworthy circumstances relative to exchange nailing are nonunions with incomplete bony contact, nonunions associated with deformity, and infected nonunions.

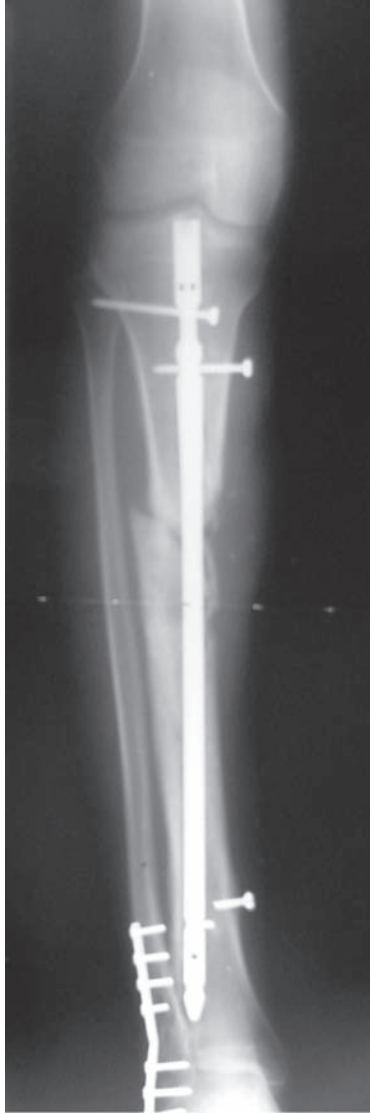p2570s0920 **Bone Contact** Exchange nailing is excellent when good bone-to-bone contact is present, but not when large partial or complete segmental bone defects exist. Because healing of nonunions with defects depends on many factors (as discussed above), it is difficult to determine which defects will unite with exchange nailing. Templeman and coauthors³⁰⁸ advocate exchange nailing in the tibia when there is 30 percent or less circumferential bone loss. Court-Brown and coauthors⁶² reported failures for exchange nailing in tibial nonunions when bone loss exceeded 2 cm in length and involved more than 50 percent circumferential bone loss. We have used intramedullary bone grafting⁴⁶ with excellent results during exchange nailing of long bones

with defects, although the indications for this technique for nonunions are still evolving.

Deformity We are astonished by how a straight nail can result in a very crooked bone (Fig. 22-75). Deformities that will ultimately limit the patient's function require correction. In a previously nailed long bone, clinically significant deformities may include length, angulation, and rotation. Translational deformities are somewhat limited by the nail (if unbroken) and are uncommonly clinically significant. s0930 p2580

Deformity correction can be acute or gradual and can be performed during or after treatment of the nonunion. If deformity correction is to follow successful bony union, exchange nailing may be undertaken as described above. If the decision is to address the nonunion and the deformity concurrently, then it must be decided whether to correct the deformity gradually or acutely. If acute deformity correction is felt to be safe, exchange nailing with acute deformity correction simplifies the overall treatment strategy. Acute deformity correction is relatively simple for lax nonunions. Stiff nonunions may require a percutaneously performed osteotomy and the intraoperative use of a femoral distractor or a temporary external fixator to achieve acute deformity correction. If the status of the soft tissues or bone favors gradual correction, then exchange nailing is rejected and the Ilizarov method is used. p2590

FIGURE 22-75 Presenting radiograph of a 22-year-old man following multiple failed treatments of a tibial nonunion. Note that a crooked bone can result despite the use of a straight nail.



Infection Numerous authors have reported the use of intramedullary nail fixation for infected nonunions.^{7,122,164,167,196,296,343} There is no consensus in the literature regarding the use of exchange nailing as a treatment for infected nonunions. For cases in which the injury has been previously treated with a method other than nailing, placement of an intramedullary nail can seed the entire medullary canal. The case of exchange nailing is entirely different. With an in situ intramedullary nail, the intramedullary canal is likely already infected, to some degree, along its entire length, and we are therefore not strictly opposed to exchange nailing of an infected nonunion (Fig. 22-76).

Exchange nailing for infected nonunions is best suited to the lower extremity in patients who are poor candidates

for plate-and-screw fixation (osteopenia, multiple soft tissue reconstructions, segmental nonunions) or external fixation (poor compliance or cognitive impairment), where the load-sharing characteristics of a nail may be of great benefit. When exchange nailing is utilized for infected nonunions, aggressive reaming of the medullary canal is a means of débridement. Reaming should use progressively larger reamer tips in 0.5-mm increments until the reamer flutes contain what appears to be viable healthy bone. All reamings should be sent for culture and sensitivity in cases of known or suspected infection. The medullary canal is irrigated copiously with antibiotic solution, and the larger diameter nail is placed. Serial débridement can be performed with an antibiotic-eluting nail being placed down the medullary canal at each operative session.

Literature Review

The reported results for exchange nailing of uninfected tibial nonunions have been excellent. Court-Brown and coauthors⁶² reported an 88 percent rate of union (29 of 33 cases) following a single exchange nailing of the tibia; the four remaining cases united following a second exchange nailing. Templeman and coauthors³⁰⁸ reported a 93 percent rate of union (25 of 27 cases), and Wu and coauthors³⁴⁷ reported a 96 percent rate of union (24 of 25 cases) with exchange nailing of the tibia.

The reported results for exchange nailing of femoral nonunions have been less consistent. Oh and co-workers²¹⁶ and Christensen⁵⁴ both reported a 100 percent union rate for aseptic femoral nonunions treated with exchange nailing, whereas Hak and coauthors¹²² reported a union rate of only 78 percent (18 of 23 cases). Weresh and coauthors³³⁵ reported a union rate of only 53 percent (10 of 19 cases) and Banaszkiwicz and coauthors of only 58 percent (11 of 19 cases) for exchange nailing of nonunions of the femoral shaft.¹⁷ Both sets of authors pointed out that recent technological advances have allowed IM nailing to be used in the treatment of more comminuted and complex femoral fractures than had previously been possible. When these types of fracture go on to nonunion, they may not be appropriate for exchange nailing.^{17,335}

The results of exchange nailing for humeral shaft nonunions have been suboptimal. McKee and co-workers¹⁹⁴ reported a 40 percent union rate (4 of 10 cases) for exchange nailing of humeral nonunions. Flinkkilä and coauthors¹⁰¹ reported union in only 23 percent (3 of 13 cases) of humeral shaft nonunions treated with antegrade exchange nailing.

Summary

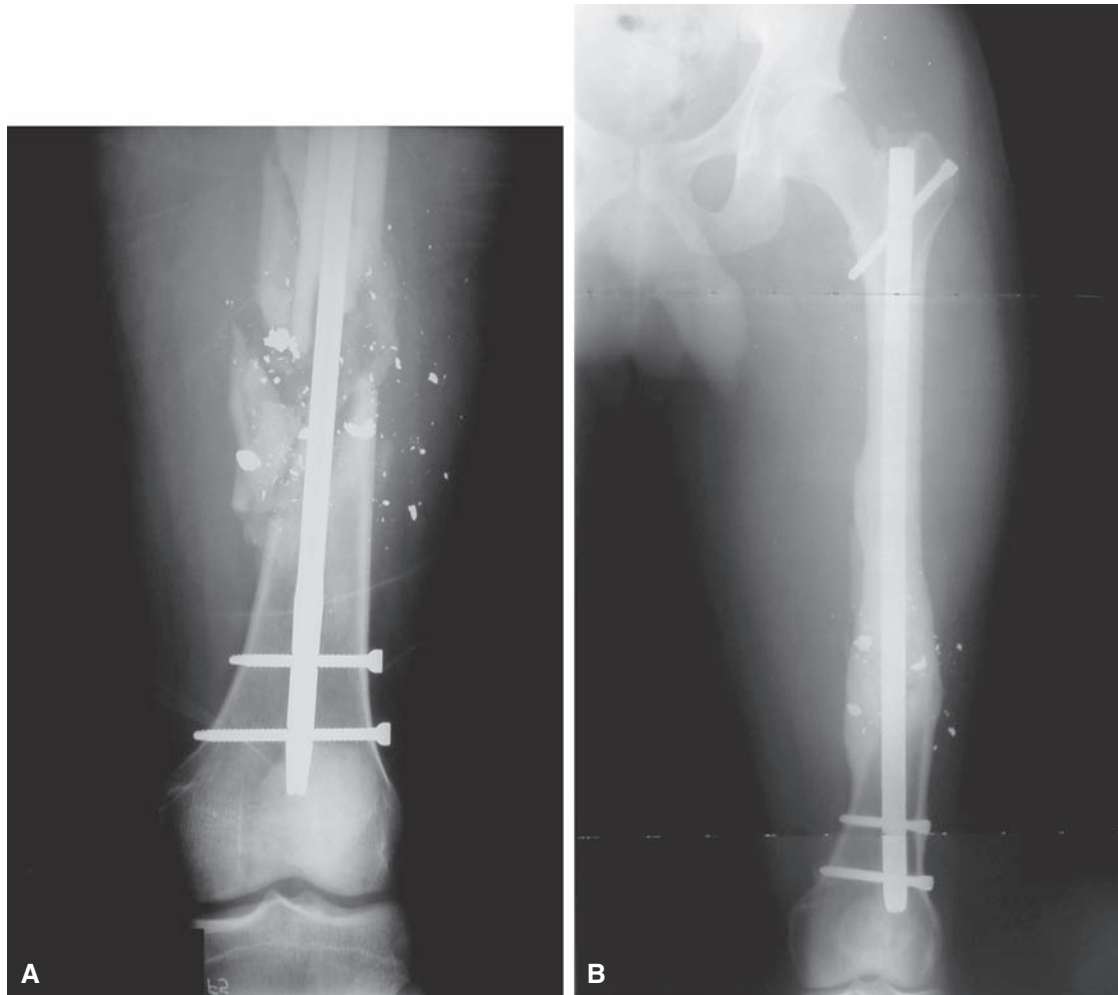
Based on the literature and our own experience, the following comments and recommendations are offered:

1. Tibia—Exchange nailing achieves healing in 90 to 95 percent of tibial nonunions.
2. Femoral shaft—Exchange nailing remains the treatment of choice for aseptic, noncomminuted nonunions of the femoral shaft, but the success rate is lower than for tibial nonunions when nonunion follows IM nailing of a comminuted or complex femoral shaft fracture.
3. Supracondylar femur—The supracondylar femur is poorly suited for stabilization of a nonunion with

f0760

FIGURE 22-76

A, Radiograph of a 23-year-old man with an actively draining infected femoral nonunion resulting from a gunshot blast. This patient was treated with serial débridement followed by exchange nailing (with intramedullary autogenous iliac crest bone grafting) of the femoral nonunion. **B**, Follow-up radiograph 13 months after treatment shows solid bony healing. This patient has no clinical evidence of infection.



an IM nail; dismal results have been reported by Koval et al.¹⁶⁷ The medullary canal is flared in this region, resulting in poor cortical bone contact with the nail. Reaming during exchange nailing for nonunions of the supracondylar region may not increase periosteal blood flow or induce new bone formation. Other treatment methods should be utilized for supracondylar nonunion of the femur (Fig. 22-77).

o0120 4. Humeral shaft—Poor results have been reported for exchange nailing of humeral shaft nonunions.^{101,194}

Nail removal and plate-and-screw fixation with autogenous cancellous bone grafting is more effective. Ilizarov methods may be required for complex cases.

s0970p2660

SYNSTOSIS TECHNIQUES The leg and forearm benefit from structural integrity provided by paired bones, which permits the use of unique treatment methods for nonunions with bone defects. The literature regarding these methods is fraught with inconsistent and contradictory terms: fibula-pro-tibia, fibula transfer, fibula transference, fibula transposition, fibular bypass, fibulazation,

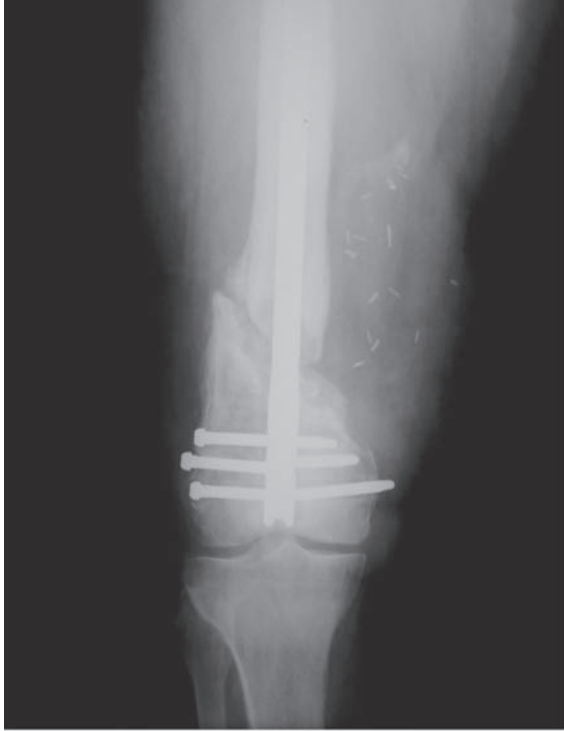medialization of the fibula, medial-ward bone transport of the fibula, posterolateral bone grafting, synostosis, tibialization of the fibula, transtibiofibular grafting, and vascularized fibula transposition.

All of these techniques can be distinguished as either a p2670 synostosis technique or local grafting from the adjacent bone (Fig. 22-78).

Synostosis techniques entail the creation of bone continuity between paired bones above and below the nonunion site. The bone neighboring the un-united bone unites to the proximal and distal fragments of the un-united bone such that the neighboring bone transmits forces across the nonunion site. From a functional standpoint, the limb becomes a one-bone extremity. Synostosis techniques do not necessarily rely on union of the original nonunion fragments to one another. p2680

Many techniques have been described to create a tibio-fibular synostosis for the treatment of tibial nonunions. p2690 Milch^{201,202} described a tibiofibular synostosis technique for nonunion using a splintered bone created by longitudinally splitting the fibula, which could be augmented

FIGURE 22-77 Radiograph of a 57-year-old man with a supracondylar femoral nonunion and two prior failed exchange nailing procedures. Exchange nailing is poor treatment method for nonunions in this region.



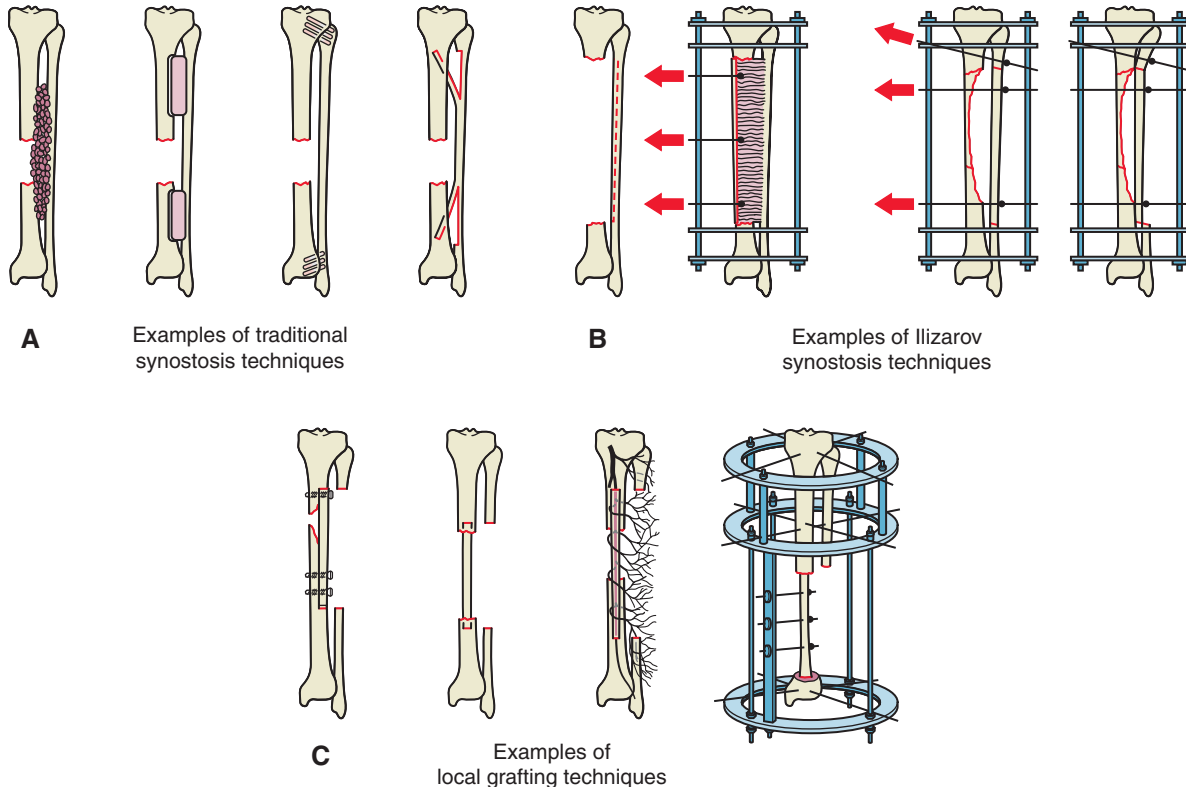
with autogenous iliac bone graft. McMaster and Hohl¹⁹⁷ used allograft cortical bone as tibiofibular cross-pegs to create a tibiofibular synostosis for tibial nonunion. Rijnberg and van Linge²⁵⁸ described a technique to treat tibial shaft nonunions by creating a synostosis with autogenous iliac crest bone graft through a lateral approach anterior to the fibula.

Ilizarov¹⁴¹ described the medial-ward (horizontal) bone transport of the fibula to create a tibiofibula synostosis for the treatment of tibial nonunions with massive segmental defects (see Fig. 22-78).

Weinberg and colleagues³³³ described a two-stage technique for cases with massive bone loss. In the first stage, a distal tibiofibula synostosis was created; at least 1 month later the second stage created a proximal tibiofibula synostosis.

The term fibula-pro-tibia sometimes describes a synostosis technique, but it is used inconsistently in the literature. Campanacci and Zanoli⁴¹ described a fibula-pro-tibia tibiofibular synostosis technique using internal fixation to stabilize the proximal and distal tibiofibular articulations for tibial nonunions without large defects. Banic and Hertel¹⁸ described a “double vascularized fibula” fibula-pro-tibia technique for large tibial defects in which the laterally grafted fibula with its intact blood supply creates a synostosis proximal and distal to the defect. By contrast, others^{190,324} have described transference of a vascularized fibula graft into a tibial defect as a fibula-pro-tibia technique; transference does not create a synostosis. None of the techniques in the literature described as fibular transference, fibular transfer, fibular transposition, and tibialization refer to synostosis procedures.^{5,15,45,137,154,297,313}

FIGURE 22-78 Synostosis techniques for the tibia compared with local bone grafting from the fibula.



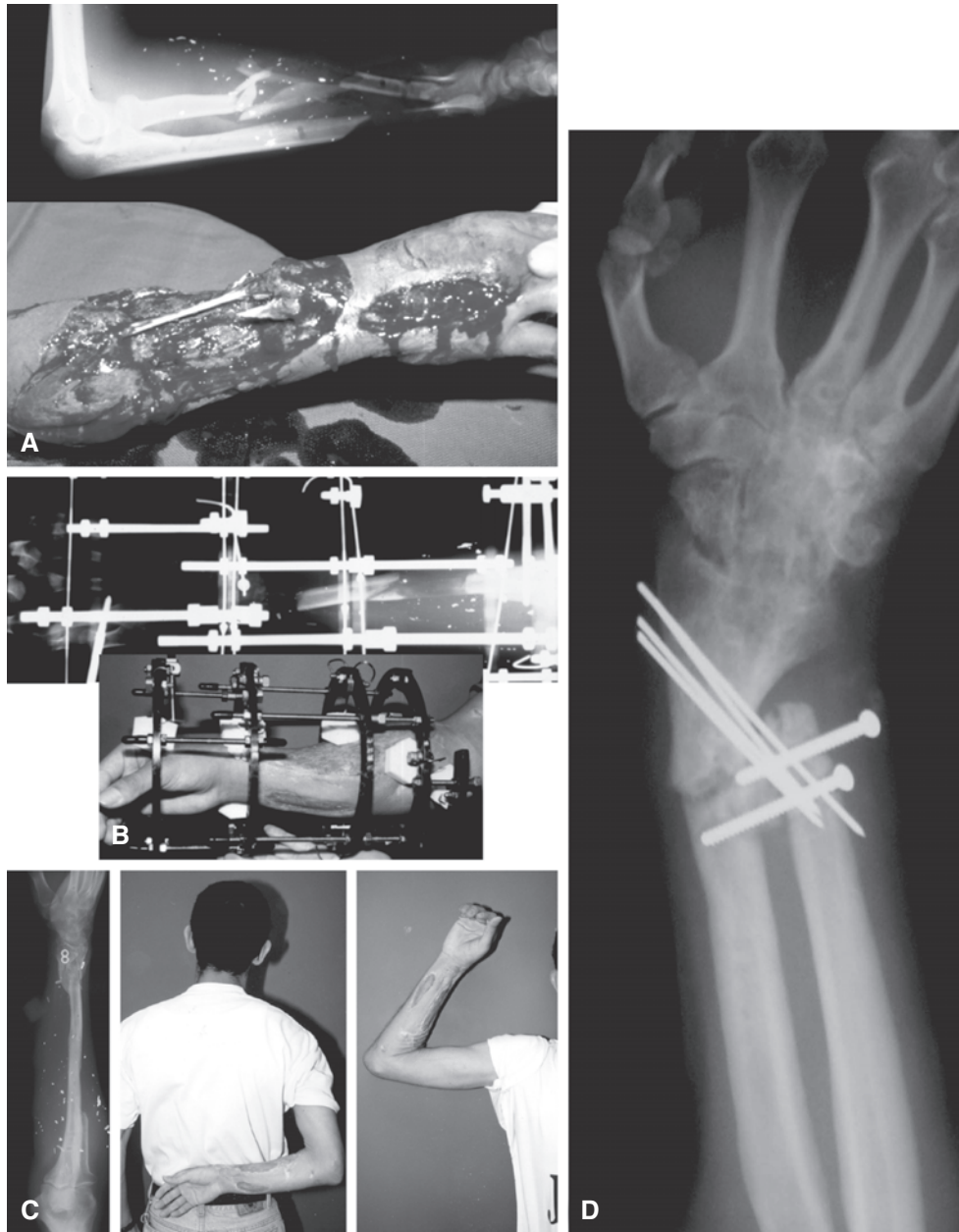p2730 The synostosis method may also be used to treat segmental defects or persistent nonunions of the forearm (Fig. 22-79). This technique is most commonly used for forearm nonunions when there is massive bone loss to both radius and ulna.

s0980p2740 **ILIZAROV METHOD** Ilizarov techniques for treatment of nonunions have many advantages (Table 22-12). The Ilizarov construct resists shear and rotational forces. The tensioned wires allow for the somewhat unique “trampoline effect” during weight-bearing activities. The Ilizarov method allows augmentation of the treatment as needed

through frame modification. Frame modification generally is not associated with pain, does not require anesthesia, and can be performed in the office. Frame modification is not treatment failure; it is continued treatment. Modifying other treatment methods, such as IM nailing, requires repeat surgical intervention and is therefore considered treatment failure.

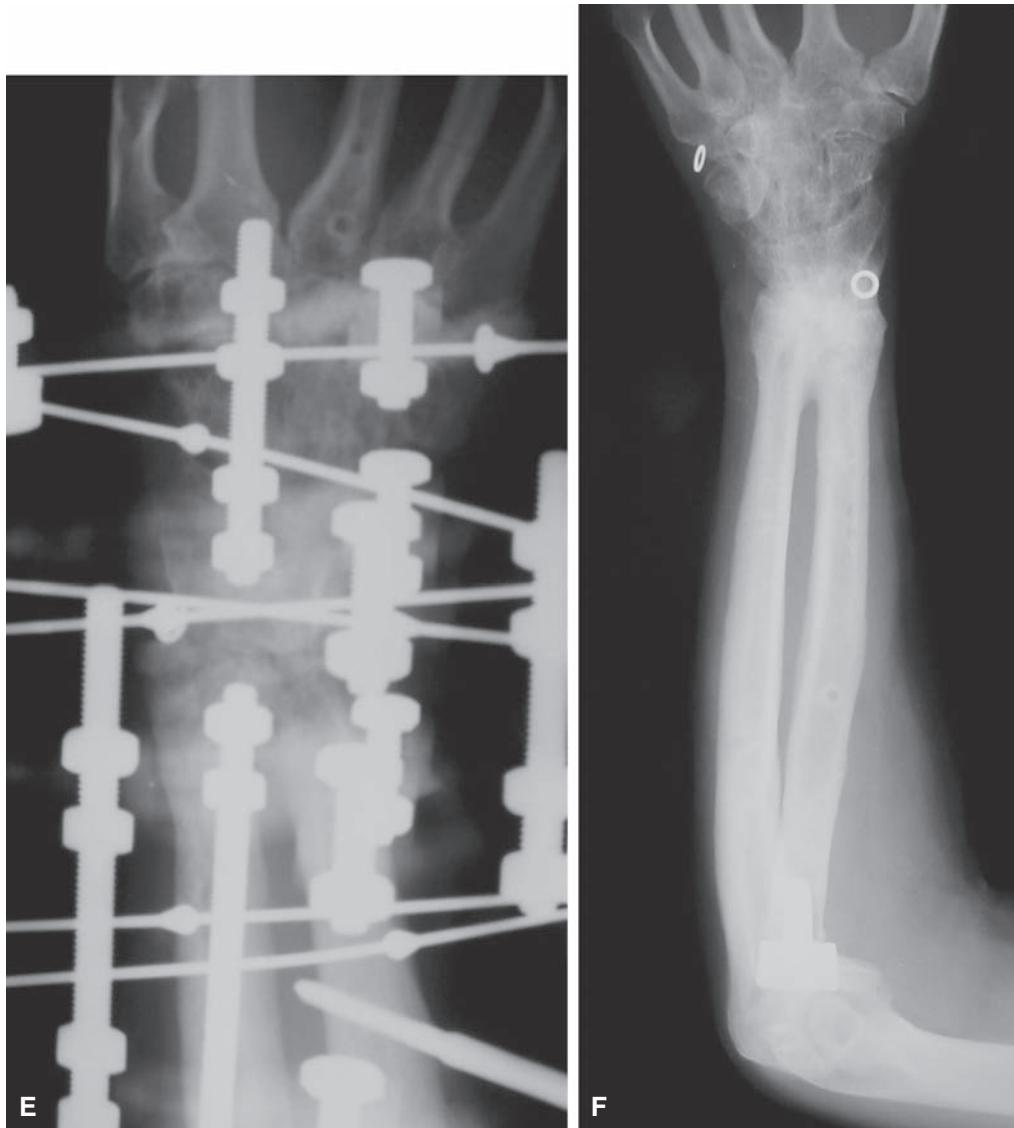The Ilizarov method is applicable for all types of nonunions, particularly those associated with infection, segmental bone defects, deformities, and multiple prior failed treatments. A variety of modes of treatment can be employed using the Ilizarov external fixator, including

f0790 **FIGURE 22-79** Two cases of forearm nonunions treated with synostosis. **A**, Presenting radiograph and clinical photograph of 32-year-old man with segmental bone loss from a gunshot blast to the forearm. **B**, Radiograph and clinical photograph of the forearm during bone transport of the proximal ulna into the distal radius to create a one-bone forearm (synostosis). **C**, Final radiograph and clinical photographs. **D**, Presenting radiograph of a 48-year-old man with multiple failed attempts at a synostosis procedure of the forearm.



(Continued)

f9020 **FIGURE 22-79** (Continued) **E**, Radiograph of the forearm during Ilizarov treatment with slow, gradual compression. **F**, Final radiographic result shows solid bony union.



compression, distraction, lengthening, and bone transport. Monofocal treatment involves simple compression or distraction across the nonunion site. Bifocal treatment denotes that two healing sites exist, such as a bone transport where healing must occur at both the distraction site (regenerate bone formation) and the docking (nonunion) site. Trifocal treatment denotes that three healing sites exist, such as in a double-level bone transport (Table 22-13).

p2760 **Au11** Compression (monofocal) osteosynthesis allows both simple compression and differential compression, which is used in deformity correction. The technique is applicable for hypertrophic nonunions (although distraction is classically used) (Fig. 22-80), oligotrophic nonunions (Figs. 22-80 through 22-83), and, according to Professor

Table 22-12

Advantages of Ilizarov Techniques

Minimally invasive
Can promote bony tissue generation
Often requires only minimal soft tissue dissection
Versatile
Can be used in the face of acute or chronic infection
Allow for stabilization of small intraarticular or periarticular bone fragments
Allow for simultaneous bony healing and deformity correction
Allow for immediate weight-bearing
Allow for early joint mobilization

t0120

t0130

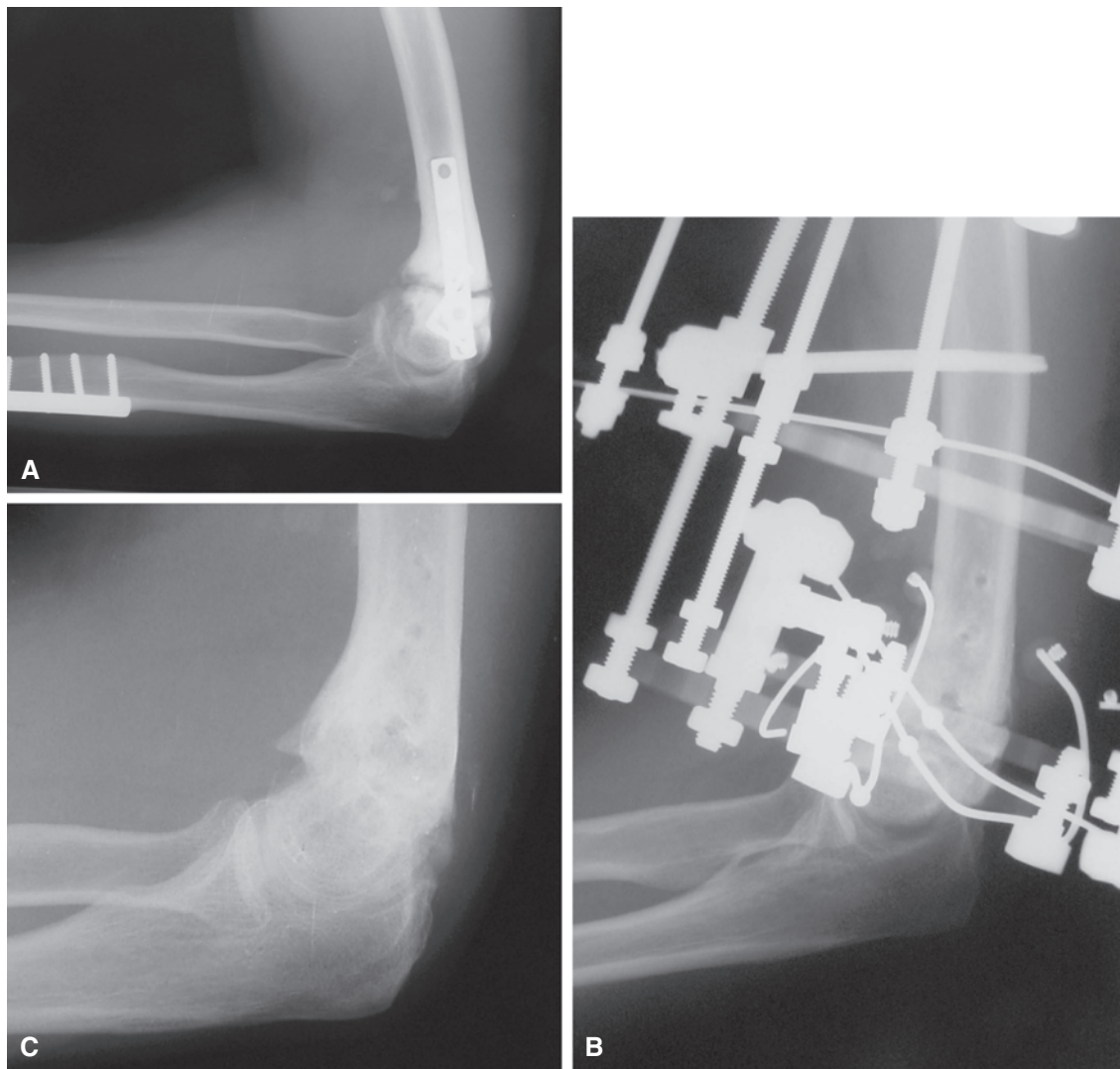
Table 22-13	
Ilizarov Treatment Modes	
Monofocal	
Compression	
Sequential distraction-compression	
Distraction	
Sequential compression-distraction	
Bifocal	
Compression-distraction lengthening	
Distraction-compression transport (bone transport)	
Trifocal	
Various combinations	

Ilizarov, synovial pseudarthroses.^{144,294} Gradual compression is generally applied at a rate of 0.25 to 0.5 mm per day for a period of 2 to 4 weeks. As the rings spanning the nonunion site move closer together after the bone ends are in contact, the thin wires bow (see Figs. 22-79 and 22-80). Compression stimulates healing for most hypertrophic and oligotrophic nonunions. Compression is usually unsuccessful for infected nonunions with purulent drainage and intervening segments of necrotic bone. There is disagreement regarding compression as a treatment for atrophic nonunions.^{174,220}

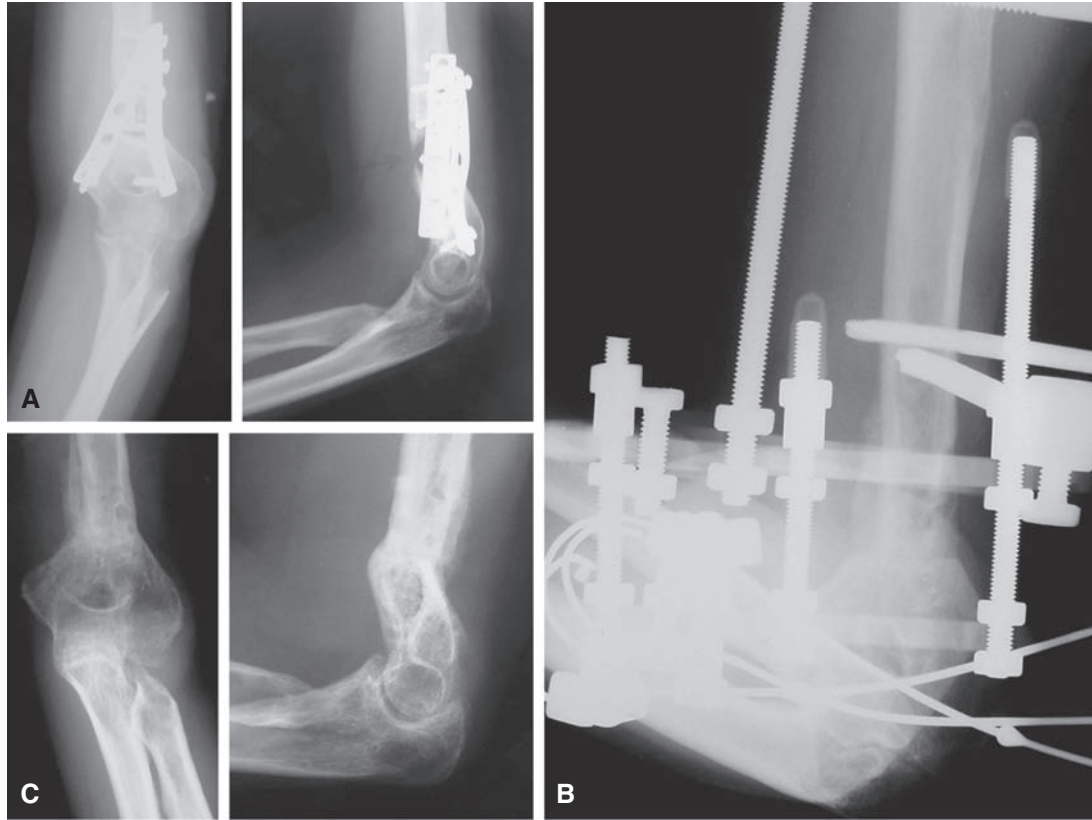Slow compression over a nail using external fixation (SCONE) is a useful method for certain patients in whom IM nailing has failed.^{36,145,230} We have used this technique

f0800

FIGURE 22-80 Ilizarov treatment of a hypertrophic distal humeral nonunion using gradual monofocal compression. **A**, Presenting radiograph. **B**, Radiograph during treatment using slow compression. Note the bending of the wires proximal and distal to the nonunion site, indicating good bony contact. **C**, Final radiographic result shows solid bony union.



f0810 **FIGURE 22-81** Example of an oligotrophic nonunion of the distal humerus treated with slow, gradual compression using Ilizarov external fixation. **A**, Presenting radiographs. **B**, Radiograph during treatment using slow, gradual compression. Note the bending of the wires, indicating good bony contact. **C**, Final radiographic result shows solid bony union.



with great success in two distinct patient populations: patients in whom multiple exchange femoral nailings have failed (Fig. 22-84) and morbidly obese patients with distal femoral nonunions in whom primary retrograde nail fracture fixation has failed (Fig. 22-85).³⁶ The SCONE method is performed with percutaneous application of the Ilizarov external fixator. The method augments stability and allows for monofocal compression at the nonunion site once the nail is dynamized. The presence of the nail in the medullary canal encourages compressive forces while discouraging translational and shear moments.

p2780 Sequential monofocal distraction-compression has been recommended as a treatment for lax hypertrophic nonunions and atrophic nonunions. According to Paley,²²⁰ “distraction disrupts the tissue at the nonunion site, frequently leading to some poor bone regeneration. This poor bone regeneration is stimulated to consolidate when the two bone ends are brought back together again.”

p2790 Distraction is the treatment method of choice for stiff hypertrophic nonunions, particularly those with deformity (Fig. 22-86). Distraction of the abundant fibrocartilaginous tissue at the nonunion site stimulates new bone formation^{44,141,220,280} and results in a high rate of healing.^{44,166,280}

p2800 Sequential monofocal compression-distraction involves an initial interval of compression followed by gradual distraction for lengthening or deformity correction. This

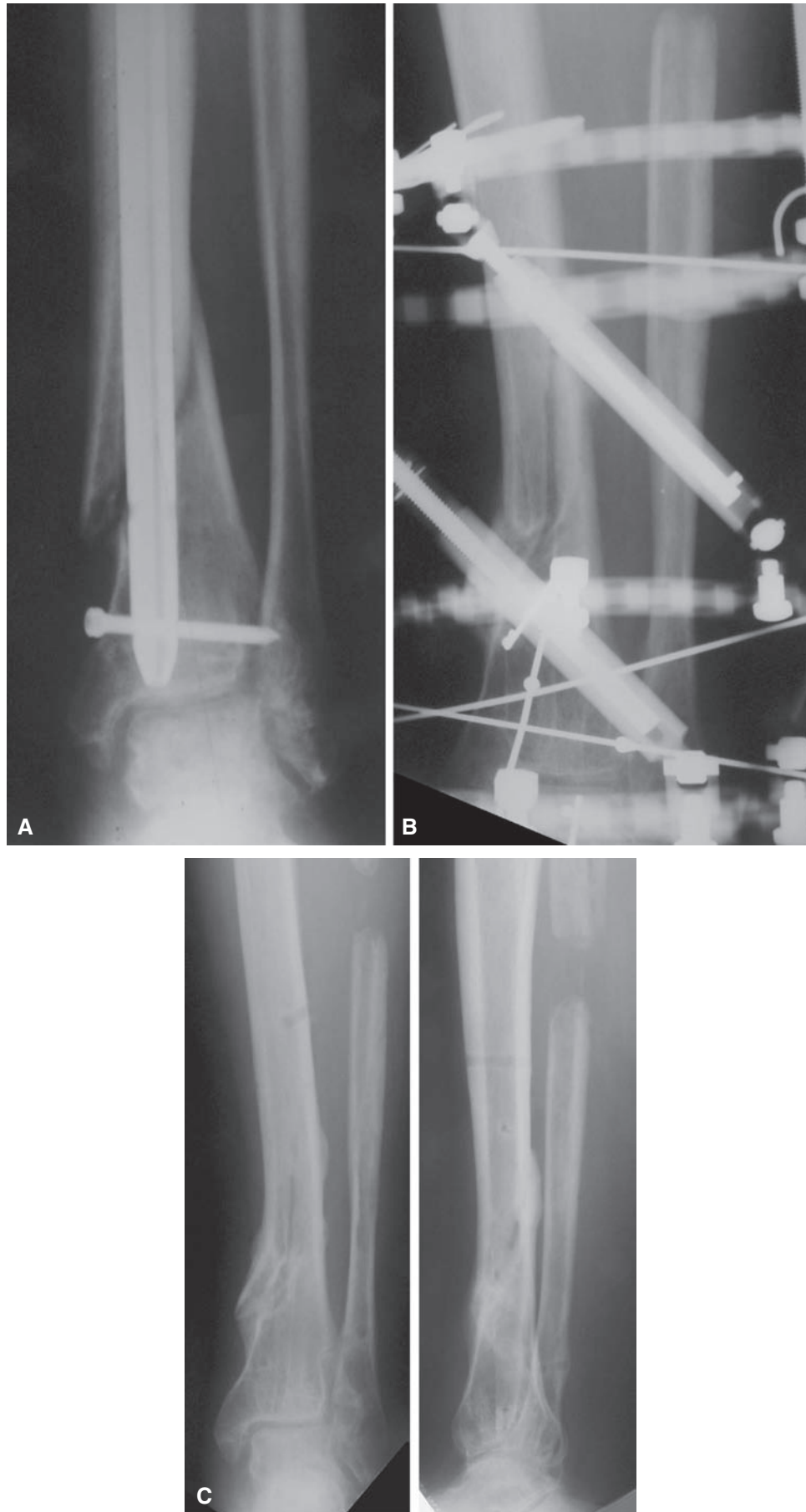
technique is applicable for stiff hypertrophic and oligotrophic nonunions but is not recommended for atrophic, infected, and lax nonunions.^{120,220}

Bifocal compression-distraction lengthening involves p2810 acute or gradual compression across the nonunion site with lengthening through an adjacent corticotomy (Fig. 22-87). This method is applicable for nonunions associated with foreshortening and nonunions with segmental defects. Segmental defects may also be treated with bifocal distraction-compression transport (bone transport) (Fig. 22-88). This method involves the creation of a corticotomy (usually metaphyseal) at a site distant from the nonunion. The bone segment produced by the corticotomy is then gradually transported toward the nonunion site (into the bony defect). As the transported segment arrives at the docking site, compression is successful in many cases in obtaining union. Occasionally bone grafting with marrow or open bone graft is required.

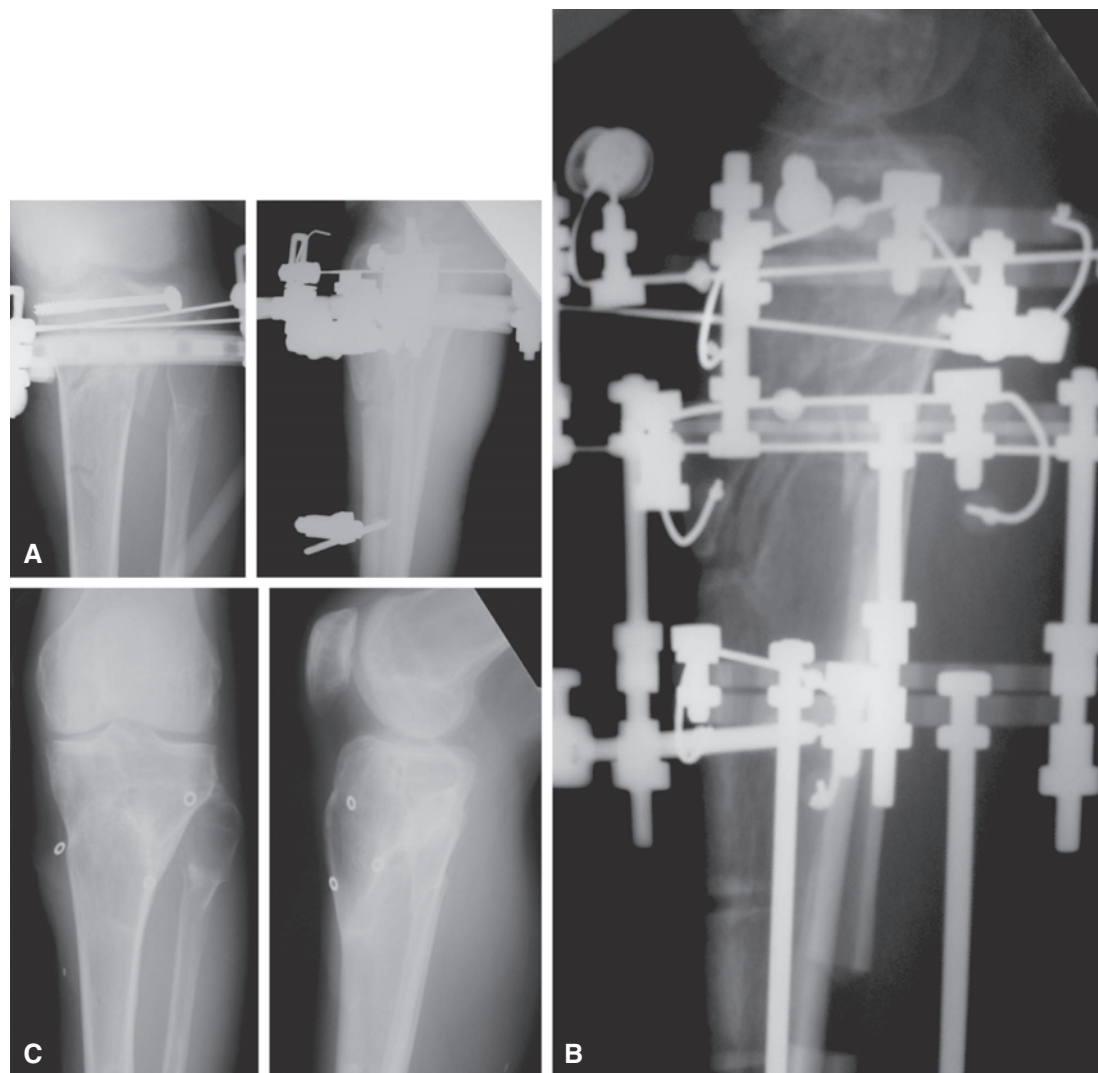
Corticotomy and bone transport result in profound p2820 biological stimulation, similar to bone grafting. In a study of dogs undergoing distraction osteogenesis, Aronson¹² reported that blood flow at the distraction site increased nearly ten-fold relative to the control limb, peaking about 2 weeks after surgery. The distal tibia, remote from the distraction site, showed a similar pattern of increased blood flow. Consequently, bone transport can be useful in the treatment of atrophic nonunions.

f0820

FIGURE 22-82 Example of an oligotrophic nonunion of the distal tibia treated with gradual deformity correction followed by slow, gradual compression using Ilizarov external fixation. **A**, Presenting radiograph. **B**, Radiograph during treatment. **C**, Final radiographic result shows solid bony union with complete deformity correction.



f0830 **FIGURE 22-83** Example of an oligotrophic nonunion of the proximal tibia treated with slow, gradual compression using Ilizarov external fixation. **A**, Presenting radiograph. **B**, Radiograph during treatment using slow, gradual compression. **C**, Final radiographic result shows solid bony union.



p2830 The bone formed at the corticotomy site in lengthening and bone transport is formed under gradual distraction (distraction osteogenesis).^{13,14,74,140,211} The tension-stress effect of distraction causes neovascularity and cellular proliferation. The method of bone regeneration is primarily via intramembranous bone formation.

p2840 Distraction osteogenesis depends on a variety of mechanical and biological requirements. The corticotomy/osteotomy must be performed using a low-energy technique. Corticotomy/osteotomy in the metaphyseal or metadiaphyseal region is preferred over diaphyseal sites. Stable external fixation promotes good bony regenerate. A latency period prior to distraction of 7 to 14 days is recommended. The rate and rhythm of distraction are controlled by the treating physician, who monitors the progression of the regenerate on x-rays. The distraction phase classically is performed at a rate of 1.0 mm per day in

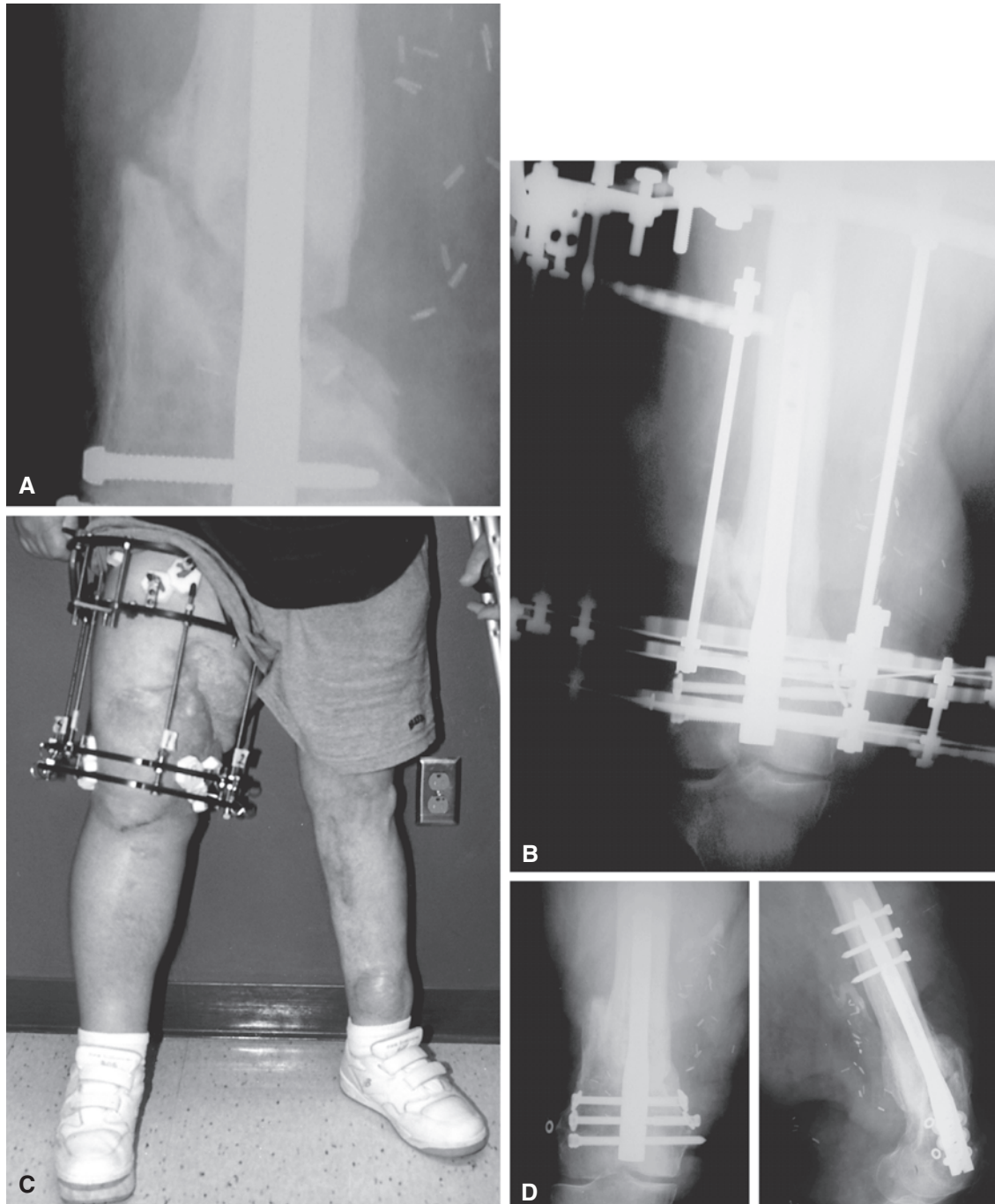
a rhythm of 0.25 mm of distraction performed 4 times per day, although we typically begin distraction at 0.75 mm per day because some patients make bony regenerate more slowly. Following distraction, maturation and hypertrophy of the bony regenerate occur during the consolidation phase. The consolidation phase is generally two to three times as long as the distraction phase, but this varies widely.

Using Ilizarov methods, two different strategies can be employed for infected nonunions and nonunions associated with segmental defects: bifocal compression-distraction (lengthening) or bifocal distraction-compression transport (bone transport). The treatment strategy for these challenging problems depends on many factors (bone, soft tissue, and medical health characteristics). No clear consensus exists. Treatment options include conventional methods (resection, soft tissue coverage, massive cancellous bone grafting, and skeletal stabilization), and Ilizarov methods.

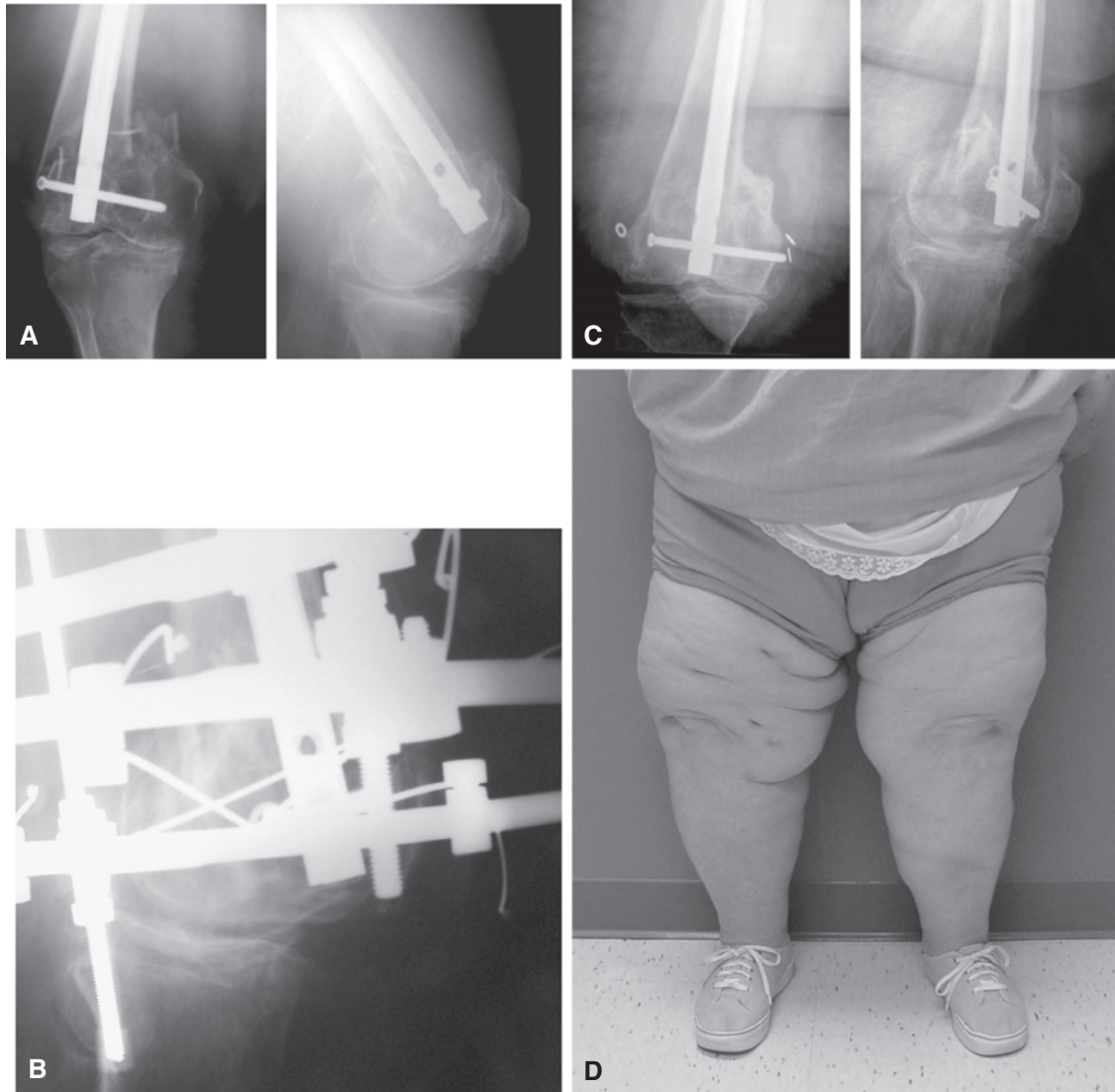
f0840

FIGURE 22-84

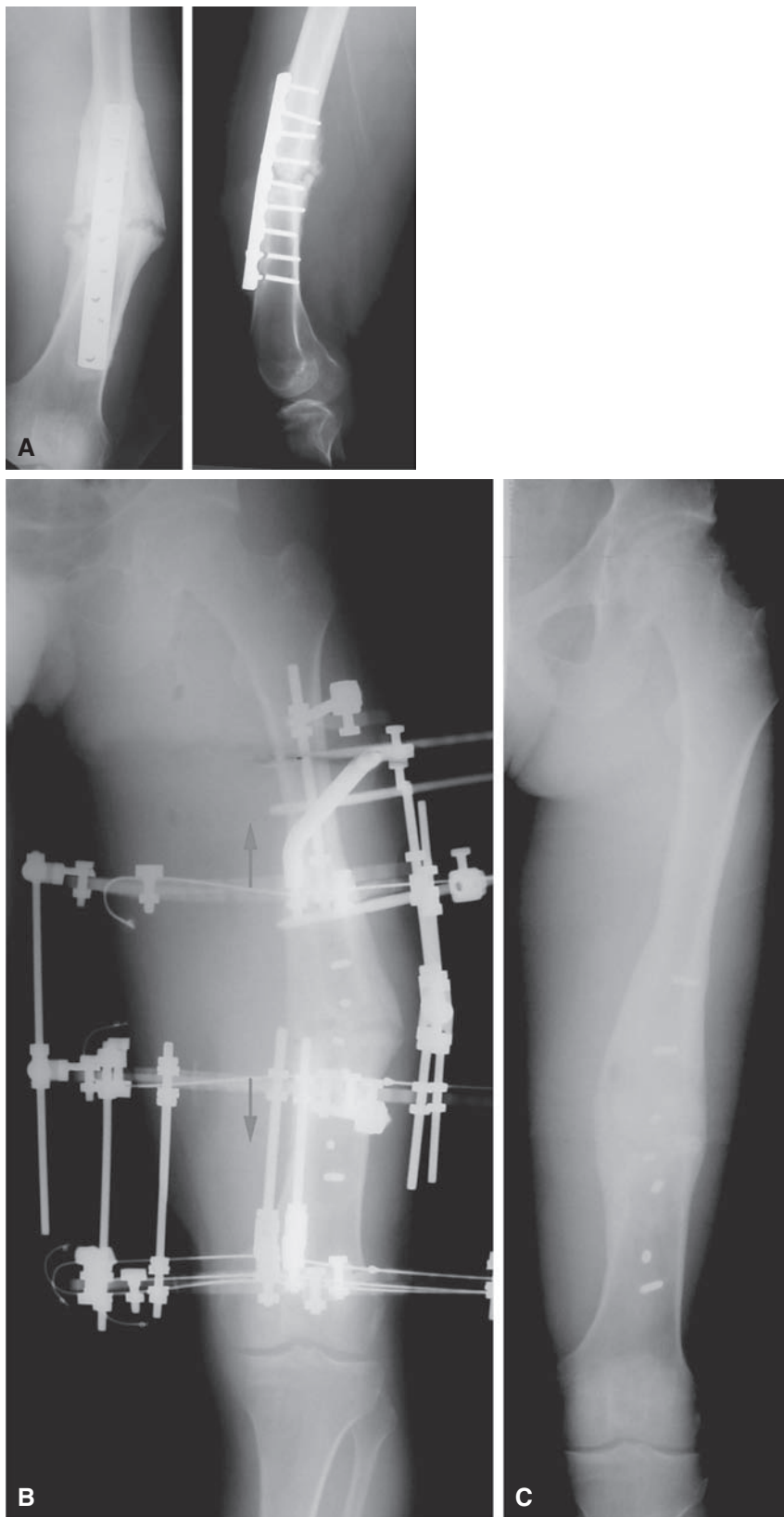
Successful treatment of a resistant femoral nonunion using slow compression over a nail using external fixation (SCONE technique). **A**, Presenting radiograph shows a femoral nonunion. The patient is a 67-year-old man with two failed exchange nailings and two open bone graft procedures. **B**, Radiograph during treatment with slow compression over a nail using external fixation. **C**, Clinical photograph during treatment. **D**, Final radiographs show solid bony union.



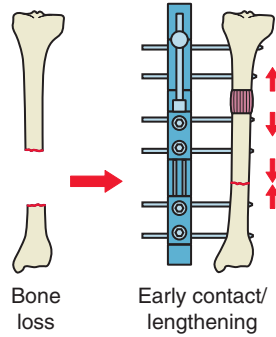
f0850 **FIGURE 22-85** Successful treatment of a distal femoral nonunion in a morbidly obese elderly diabetic woman 10 months after retrograde intramedullary nailing for a fracture. **A**, Presenting radiographs show a distal femoral nonunion. **B**, Radiograph during treatment with slow compression over a nail using external fixation (SCONE technique). **C**, Final radiographs show solid bony union. **D**, Clinical photograph following successful treatment.



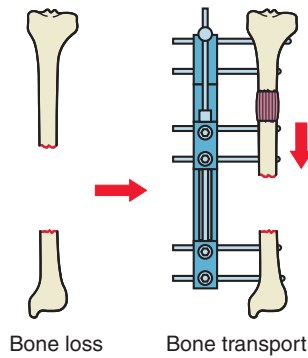
f0860 **FIGURE 22-86** Treatment of a stiff hypertrophic nonunion of the femoral shaft using distraction. **A**, Presenting radiographs. **B**, Radiograph during treatment via distraction using the Ilizarov external fixator. Note that differential distraction also results in deformity correction. **C**, Final radiographic result shows solid bony union and deformity correction.



f0870 **FIGURE 22-87** *Compression-distraction lengthening.*



f0880 **FIGURE 22-88** *Distraction-compression transport (bone transport).*



p2860 A number of studies have compared these various methods. Green¹¹⁶ compared bone grafting and bone transport in the treatment of segmental skeletal defects. For defects of 5 cm or less, he recommended the use of either technique, but he recommended bone transport or free composite tissue transfer for larger defects. In a similar study, Marsh and co-workers¹⁸⁵ compared resection and bone transport to treatment with less extensive débridement, external fixation, bone grafting, and soft tissue coverage and found that the groups were similar in terms of healing rate, healing and treatment time, eradication of infection, final deformity, complications, and total number of operative procedures. The final limb length discrepancy was significantly less in the group treated with bone transport. Cierny and Zorn⁵⁵ compared conventional (massive cancellous bone grafts and tissue transfers) versus Ilizarov methods in the treatment of segmental tibial defects. The Ilizarov group averaged 9 fewer hours in the operating room, 23 fewer days of hospitalization, 5 months less of disability, and a savings of nearly \$30,000 per case. Ring and coauthors²⁶¹ compared autogenous cancellous bone grafting versus Ilizarov treatment for infected tibial nonunions and concluded that the Ilizarov methods may best be utilized for large limb length discrepancy or for very proximal or distal metaphyseal nonunions. Acute shortening with subsequent relengthening has a significantly lower complication rate and requires less time in

the external fixator than does bone transport for tibial defects, although both techniques provide excellent overall results. Mahaluxmivala and colleagues also recommended acute shortening with subsequent relengthening over bone transport because of shorter treatment time and fewer additional treatments (e.g., bone grafting) needed to achieve bony union.¹⁸³

ARTHROPLASTY In certain situations, joint replacement arthroplasty may be the chosen treatment method for a fracture nonunion. The advantages are early return to function with immediate weight-bearing and joint mobilization. The main disadvantage is the excision of native anatomic structures (bone, cartilage, ligaments, etc.). Arthroplasty as a treatment of nonunion is indicated in older patients with severe medical problems; long-standing, resistant periarticular nonunions; periarticular nonunions associated with small osteopenic fragments; nonunions associated with painful post-traumatic or degenerative arthritis; and periprosthetic nonunions that either cannot be readily stabilized by conventional methods or have failed conventional treatment methods (Fig. 20-89).

Arthroplasty as a method of treatment for nonunion has been reported in a variety of anatomic locations including the hip,^{63,182,188} knee,^{10,72,103,288,336} shoulder,^{11,105,126,213} and elbow.^{206,225}

ARTHRODESIS Arthrodesis as a treatment method for nonunion is indicated for patients with previously failed (un-united) arthrodesis procedures (Fig. 22-90); infected periarticular nonunions; unreconstructable periarticular nonunions in locations that are not believed to have good long-term result with arthroplasty (e.g., the ankle); unreconstructable periarticular nonunions in young patients who are not long-term candidates for arthroplasty; infected nonunions in which débridement necessitates removal of important articular structures (see Fig. 22-71); and nonunions associated with unreconstructable joint instability, contracture, or pain that are not amenable to arthroplasty (see Fig. 22-71).

An alloarthrodesis procedure may be performed when a segmental bone defect extends to the epiphyseal region in a patient in whom an alloprosthesis is contraindicated (see Fig. 22-71).

AMPUTATION Lange et al.¹⁷⁵ published indications for amputation in the patient with an acute open fracture of the tibia associated with a vascular injury. Delay in amputation of a severely injured limb may lead to serious systemic complications, including death, so rapid, resolute decision-making in the acute setting is important.

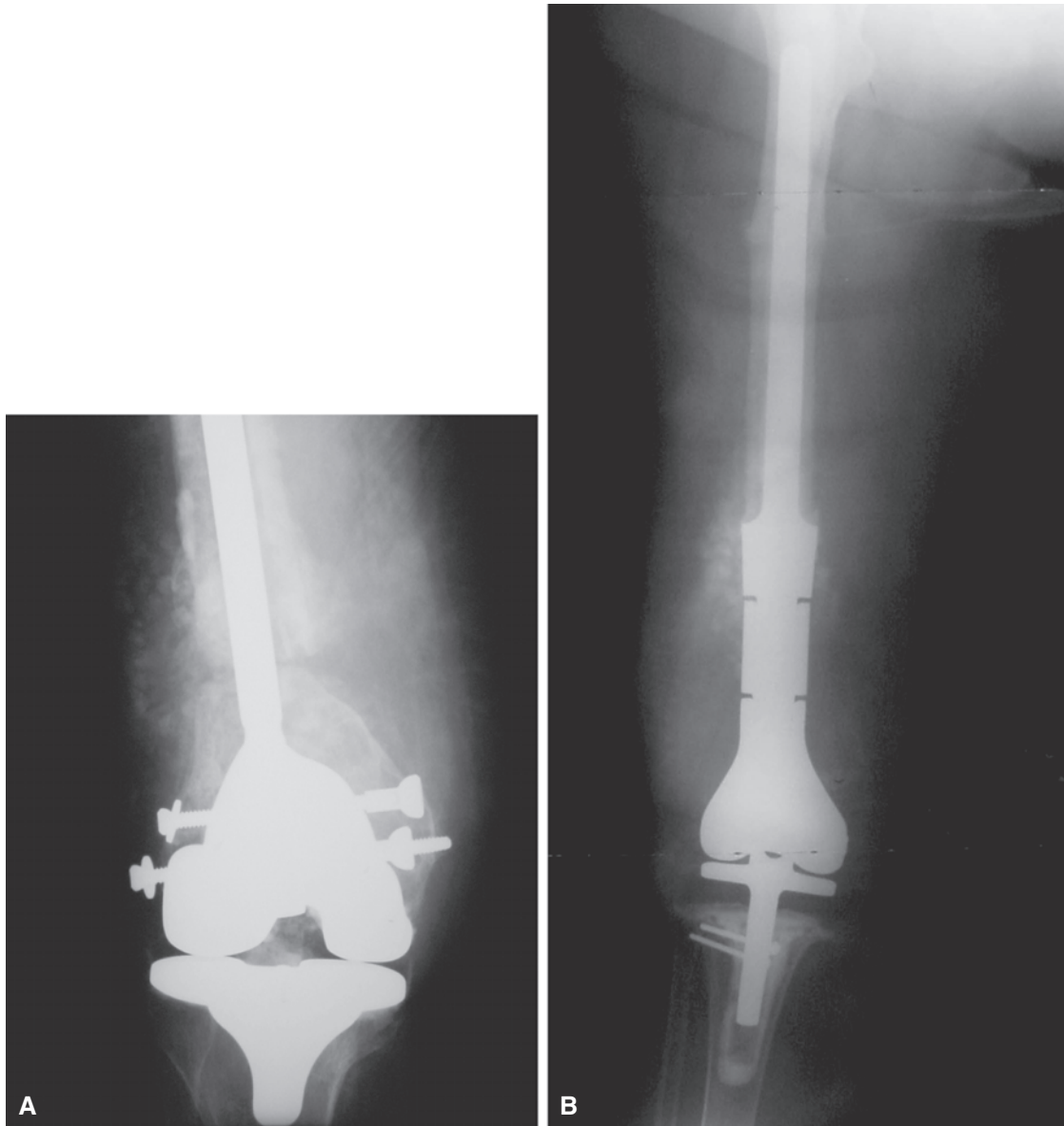
The decision whether to amputate or reconstruct a nonunion is a different matter. The patient is not in extremis and has typically been living with the problem for a long time. In a study of quality of life in 109 patients with post-traumatic sequelae of the long bones, Lerner et al.¹⁷⁹ described the choice determinants in patients undergoing amputation:

1. Patients decided to discontinue medical and surgical treatment. o0130
Au12
2. Amputation was recommended by a doctor. o0140
3. Patients believed that they would never be cured. o0150

f0890

FIGURE 22-89

A, Presenting radiograph of an 82-year-old woman with a distal femoral periprosthetic nonunion. This patient had been wheelchair-bound for 2 years and had three prior failed attempts at nonunion treatment. **B**, Radiograph following joint replacement arthroplasty. The patient has had excellent pain relief and has resumed ambulation without the need for walking aids.



p2930 There are no absolute indications for amputation of a chronic un-united limb. Each case is unique and includes multiple complex issues, and treatment algorithms are usually not helpful.

p2940 Amputation of an un-united limb should be considered in several situations:

u0120 Sepsis arises in a frail, elderly, or medically compromised patient with an infected nonunion, and there is concern about the patient's survival.

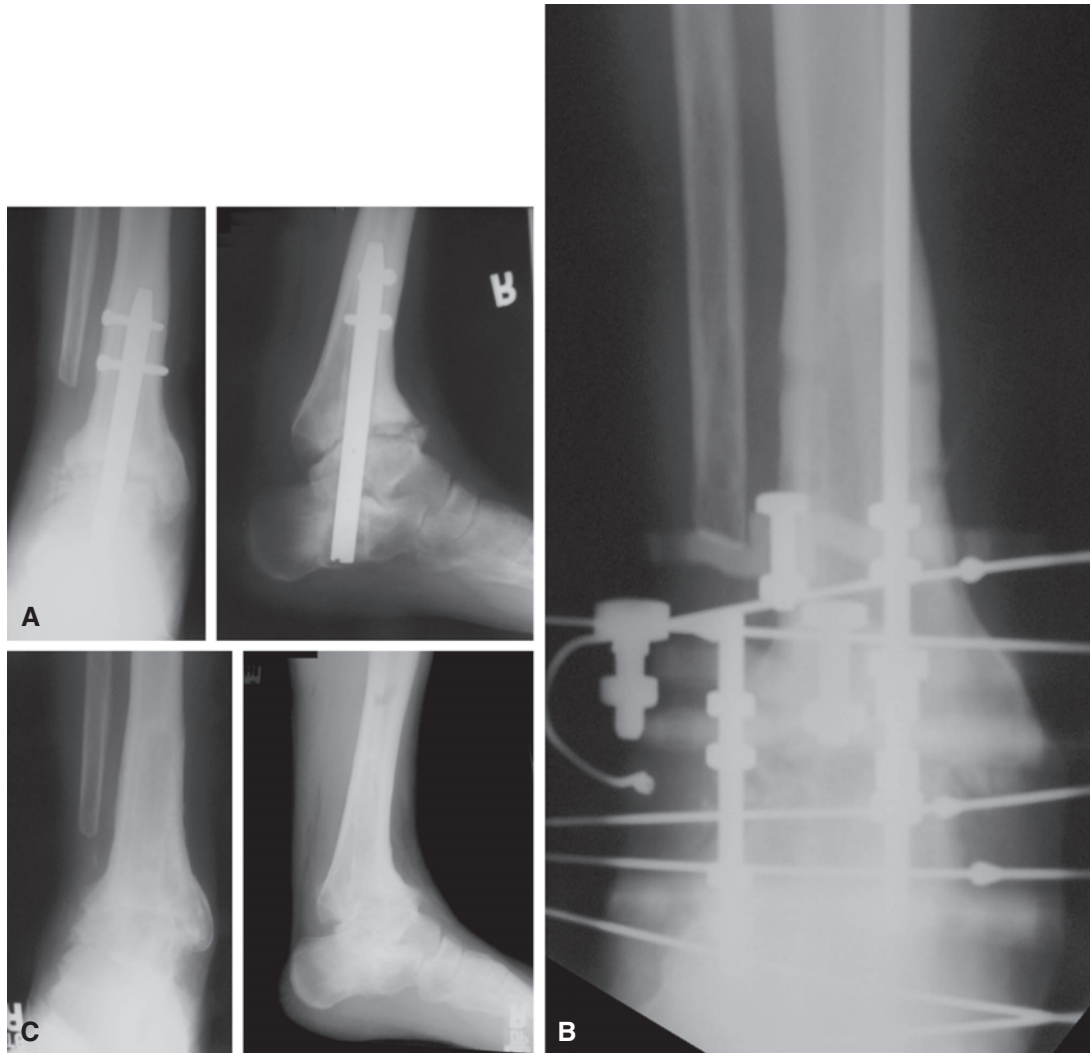u0130 Loss of neurologic function (motor or sensory or both) is unreconstructable and precludes restoration of purposeful limb function.

Chronic osteomyelitis associated with the nonunion is u0140 in an anatomic area that precludes reconstruction (e.g., the calcaneus).

The patient wishes to discontinue medical and surgical u0150 treatment of the nonunion and desires to have an amputation.

All patients considering amputation for a nonunion p2950 should seek a minimum of two opinions from orthopaedic surgeons specializing in nonunion reconstruction techniques. Amputation should not be undertaken because the treating physician has run out of ideas, treatment recommendations, or stamina. The motivated patient who has

f0900 **FIGURE 22-90** **A**, Presenting radiographs of a 25-year-old man who had had a total of 18 prior ankle operations and five failed prior attempts at ankle arthrodesis. **B**, The patient was treated with percutaneous hardware removal and gradual compression using an Ilizarov external fixator. The ankle joint was not operatively approached and no bone grafting was performed. **C**, Final radiographic result following simple gradual compression shows solid fusion of the ankle.



a recalcitrant nonunion but wishes to retain the limb can be referred to a colleague. Once a limb has been cut off, it cannot be reattached.

s1020 **SUMMARY**

p2960 The care of the patient who has a nonunion is always challenging and sometimes troubling. Because of the various nonunion types and the constellation of possible problems related to the bone, soft tissues, prior treatments, patient's health, and other factors, no simple treatment algorithms are possible. The care of these patients requires patience with the ultimate goal of bony union, restoration of function, and limited impairment and disability. An approach

to the evaluation and treatment of these patients has been provided. A few simple axioms bear further emphasis.

The 10 Commandments of Nonunion Treatment

s1030

Thou shalt

p2970

1. Examine thy patient, and carefully consider all available information. o0160
2. Learn about the personality of the nonunion from the prior failed treatments. o0170
3. Not repeat failed prior procedures (those which have not yielded any evidence of healing effort) over and over and over again. o0180

- o0190 4. Base thy treatment plan on the nonunion type and the treatment modifiers, and not upon false prophecies.
- o0200 5. Forsake the use of the same hammer for every single nail (the treatment of nonunions requires surgical expertise in a wide variety of internal and external fixation techniques).
- o0210 6. Honor the soft tissues, and keep them whole.
- o0220 7. Consider minimally invasive techniques (Ilizarov method, bone marrow injection, etc.), where extensive surgical exposures have failed.
- o0230 8. Not take the previous treating physician's name or treatment method or results in vain, particularly in the presence of the patient. Honor thy referring physician, and keep him or her informed of the patient's progress.
- o0240 9. Burn no bridges, and leave thyself the option of a "next treatment plan."
- o0250 10. Covet stability, vascularity, and bone-to-bone contact.

s1040 ACKNOWLEDGMENTS

p2980 The authors thank Joseph J. Gugenheim, M.D., Jeffrey C. London, M.D., Ebrahim Delpassand, M.D., and Michele Clowers for editorial assistance with the manuscript, and Rodney K. Baker for assistance with the figures.

REFERENCES

1. Aaron, R.K.; Ciombor, D.M.; Simon, B.J. Treatment of nonunions with electric and electromagnetic fields. *Clin Orthop Relat Res* 419:21–29, 2004.
2. Abdel-Aa, A.M.; Farouk, O.A.; Elsayed, A.; et al. The use of a locked plate in the treatment of ununited femoral shaft fractures. *J Trauma* 57:832–836, 2004.
3. Abhaykumar, S.; Elliott, D.S. Closed interlocking nailing for fibular nonunion. *Injury* 29:793–797, 1998.
4. Adams, C.I.; Keating, J.F.; Court-Brown, C.M. Cigarette smoking and open tibial fractures. *Injury* 32:61–65, 2001.
5. Agiza, A.R. Treatment of tibial osteomyelitic defects and infected pseudoarthroses by the Huntington fibular transference operation. *J Bone Joint Surg Am* 63:814–849, 1981.
6. Ahlmann, E.; Patzakis, M.; Roidis, N.; et al. Comparison of anterior and posterior iliac crest bone grafts in terms of harvest-site morbidity and functional outcomes. *J Bone Joint Surg Am* 84:716–720, 2002.
7. Alho, A.; Ekeland, A.; Stromsoe, K.; et al. Nonunion of tibial shaft fractures treated with locked intramedullary nailing without bone grafting. *J Trauma* 34:62–67, 1993.
8. Allen, H.L.; Wase, A.; Bear, W.T. Indomethacin and aspirin: Effect of nonsteroidal anti-inflammatory agents on the rate of fracture repair in the rat. *Acta Orthop Scand* 51:595–600, 1980.
9. Altman, R.D.; Latta, L.L.; Keer, R.; et al. Effect of nonsteroidal anti-inflammatory drugs on fracture healing: A laboratory study in rats. *J Orthop Trauma* 9:392–400, 1995.
10. Anderson, S.P.; Matthews, L.S.; Kaufer, H. Treatment of juxta-articular nonunion fractures at the knee with long-stem total knee arthroplasty. *Clin Orthop Relat Res* 260:104–109, 1990.
11. Antuña, S.A.; Sperling, J.W.; Sanchez-Sotelo, J.; et al. Shoulder arthroplasty for proximal humeral nonunions. *J Shoulder Elbow Surg* 11:114–121, 2002.
12. Aronson, J. Temporal and spatial increases in blood flow during distraction osteogenesis. *Clin Orthop Relat Res* 301:124–131, 1994.
13. Aronson, J.; Good, B.; Stewart, C.; et al. Preliminary studies of mineralization during distraction osteogenesis. *Clin Orthop Relat Res* 250:43–49, 1990.
14. Aronson, J.; Harrison, B.; Boyd, C.M.; et al. Mechanical induction of osteogenesis: Preliminary studies. *Ann Clin Lab Sci* 18:195–203, 1988.
15. Atkins, R.M.; Madhavan, P.; Sudhakar, J.; et al. Ipsilateral vascularised fibular transport for massive defects of the tibia. *J Bone Joint Surg Br* 81:1035–1040, 1999.
16. Ballmer, F.T.; Ballmer, P.M.; Baumgaertel, F.; et al. Pauwels osteotomy for nonunions of the femoral neck. *Orthop Clin North Am* 21:759–767, 1990.
17. Banaszkiwicz, P.A.; Sabboubeh, A.; McLeod, I.; et al. Femoral exchange nailing for aseptic non-union: Not the end to all problems. *Injury* 34:349–356, 2003.
18. Banic, A.; Hertel, R. Double vascularized fibulas for reconstruction of large tibial defects. *J Reconstr Microsurg* 9:421–428, 1993.
19. Barquet, A.; Mayora, G.; Fregeiro, J.; et al. The treatment of subtrochanteric nonunions with the long gamma nail: Twenty-six patients with a minimum 2-year follow-up. *J Orthop Trauma* 18:346–353, 2004.
20. Bassett, C.A.L. Current concepts of bone formation. *J Bone Joint Surg Am* 44:1217–1244, 1962.
21. Bassett, C.A.L.; Pilla, A.A.; Pawluk, R.J. A non-operative salvage of surgically resistant pseudoarthroses and nonunions by pulsing electromagnetic fields. *Clin Orthop Relat Res* 124:128–143, 1977.
22. Beardmore, A.A.; Brooks, D.E.; Wenke, J.C.; et al. Effectiveness of local antibiotic delivery with an osteoinductive and osteoconductive bone-graft substitute. *J Bone Joint Surg Am* 87:107–112, 2005.
23. Bellabarba, C.; Ricci, W.M.; Bolhofner, B.R. Results of indirect reduction and plating of femoral shaft nonunions after intramedullary nailing. *J Orthop Trauma* 15:254–263, 2001.
24. Beredjiklian, P.K.; Hotchkiss, R.N.; Athanasian, E.A.; et al. Recalcitrant nonunion of the distal humerus: Treatment with free vascularized bone grafting. *Clin Orthop Relat Res* 435:134–139, 2005.
25. Bhan, S.; Mehara, A.K. Percutaneous bone grafting for nonunion and delayed union of fractures of the tibial shaft. *Int Orthop* 17:310–312, 1993.
26. Bhattacharyya, T.; Bouchard, K.A.; Phadke, A.; et al. The accuracy of computed tomography for the diagnosis of tibial nonunion. *J Bone Joint Surg Am* 88:692–697, 2006.

27. Blachut, P.A.; Meek, R.N.; O'Brien, P.J. External fixation and delayed intramedullary nailing of open fractures of the tibial shaft: A sequential protocol. *J Bone Joint Surg Am* 72:729-735, 1990.
28. Boehme, D.; Curtis, R.J., Jr.; DeHaan, J.T.; et al. The treatment of nonunion fractures of the midshaft of the clavicle with an intramedullary Hagie pin and autogenous bone graft. *Instr Course Lect* 42:283-290, 1993.
29. Bondurant, F.J.; Cotler, H.B.; Buckle, R.; et al. The medical and economic impact of severely injured lower extremities. *J Trauma* 28:1270-1273, 1988.
30. Borrelli, J., Jr.; Prickett, W.D.; Ricci, W.M. Treatment of nonunions and osseous defects with bone graft and calcium sulfate. *Clin Orthop Relat Res* 411:245-254, 2003.
31. Bradbury, N.; Hutchinson, J.; Hahn, D.; et al. Clavicular nonunion: 31/32 healed after plate fixation and bone grafting. *Acta Orthop Scand* 67:367-370, 1996.
32. Brighton, C.T.; Esterhai, J.L., Jr.; Katz, M.; et al. Synovial pseudoarthrosis: A clinical, roentgenographic-scintigraphic, and pathologic study. *J Trauma* 27:463-470, 1987.
33. Brinker, M.R. Principles of Fractures. In Brinker, M.R., ed. *Review of Orthopaedic Trauma*. Philadelphia, W.B. Saunders, 2001.
34. Brinker, M.R.; Bailey, D.E. Fracture healing in tibia fractures with an associated vascular injury. *J Trauma* 42:11-19, 1997.
35. Brinker, M.; Cook, S.; Dunlap, J.; et al. Early changes in nutrient artery blood flow following tibial nailing with and without reaming: A preliminary study. *J Orthop Trauma* 13:129-133, 1999.
36. Brinker, M.R.; O'Connor, D.P. Ilizarov compression over a nail for aseptic femoral nonunions that have failed exchange nailing: A report of five cases. *J Orthop Trauma* 17:668-676, 2003.
37. Brownlow, H.C.; Reed, A.; Simpson, A.H. The vascularity of atrophic non-unions. *Injury* 33:145-150, 2002.
38. Burd, T.A.; Hughes, M.S.; Anglen, J.O. Heterotopic ossification prophylaxis with indomethacin increases the risk of long-bone nonunion. *J Bone Joint Surg Br* 85:700-705, 2003.
39. Butcher, C.K.; Marsh, D.R. Nonsteroidal anti-inflammatory drugs delay tibial fracture union [abstract]. *Injury* 27:375, 1996.
40. Cameron, H.U.; Welsh, R.P.; Jung, Y.B.; et al. Repair of nonunion of tibial osteotomy. *Clin Orthop Relat Res* 287:167-169, 1993.
41. Campanacci, M.; Zanoli, S. Double tibiofibular synostosis (fibula pro tibia) for non-union and delayed union of the tibia. *J Bone Joint Surg Am* 48:44-56, 1966.
42. Cantu, R.V.; Koval, K.J. The use of locking plates in fracture care. *J Am Acad Orthop Surg* 14:183-190, 2006.
43. Carpenter, C.A.; Jupiter, J.B. Blade plate reconstruction of metaphyseal nonunion of the tibia. *Clin Orthop Relat Res* 332:23-28, 1996.
44. Catagni, M.A.; Guerreschi, F.; Holman, J.A.; et al. Distraction osteogenesis in the treatment of stiff hypertrophic nonunions using the Ilizarov apparatus. *Clin Orthop Relat Res* 301:159-163, 1994.
45. Chacha, P.B.; Ahmed, M.; Daruwalla, J.S. Vascular pedicle graft of the ipsilateral fibula for non-union of the tibia with a large defect: An experimental and clinical study. *J Bone Joint Surg Br* 63:244-253, 1981.
46. Chapman, M.W. Closed intramedullary bone grafting for diaphyseal defects of the femur. *Instr Course Lect* 32:317-324, 1983.
47. Charlton, W.P.; Kharazzi, D.; Alpert, S.; et al. Unstable nonunion of the scapula: A case report. *J Shoulder Elbow Surg* 12:517-519, 2003.
48. Charnley, G.J.; Ward, A.J. Reconstruction femoral nailing for nonunion of subtrochanteric fracture: A revision technique following dynamic condylar screw failure. *Int Orthop* 20:55-57, 1996.
49. Charnley, J. *Compression Arthrodesis*. Edinburgh and London, E. and S. Livingstone, 1953.
50. Chatziyiannakis, A.A.; Verettas, D.A.; Raptis, V.K.; et al. Nonunion of tibial fractures treated with external fixation: Contributing factors studied in 71 fractures. *Acta Orthop Scand Suppl* 275:77-79, 1997.
51. Chen, C.Y.; Ueng, S.W.; Shih, C.H. Staged management of infected humeral nonunion. *J Trauma* 43:793-798, 1997.
52. Chin, K.R.; Nagarkatti, D.G.; Miranda, M.A.; et al. Salvage of distal tibia metaphyseal nonunions with the 90-degree cannulated blade plate. *Clin Orthop Relat Res* 409:241-249, 2003.
53. Chmell, M.J.; McAndrew, M.P.; Thomas, R.; et al. Structural allografts for reconstruction of lower extremity open fractures with 10 centimeters or more of acute segmental defects. *J Orthop Trauma* 9:222-226, 1995.
54. Christensen, N.O. Kuntscher intramedullary reaming and nail fixation for non-union of fracture of the femur and the tibia. *J Bone Joint Surg Br* 55:312-318, 1973.
55. Cierny, G.III, Zorn, K.E. Segmental tibial defects: Comparing conventional and Ilizarov methodologies. *Clin Orthop Relat Res* 301:118-123, 1994.
56. Ciombor, D.M.; Aaron, R.K. The role of electrical stimulation in bone repair. *Foot Ankle Clin* 10:579-593, vii, 2005.
57. Clarke, P.; Mollan, R.A. The criteria for amputation in severe lower limb injury. *Injury* 25:139-143, 1994.
58. Cobb, T.K.; Gabrielsen, T.A.; Campbell, D.C.II, et al. Cigarette smoking and nonunion after ankle arthrodesis. *Foot Ankle Int* 15:64-67, 1994.
59. Cobos, J.A.; Lindsey, R.W.; Gugala, Z. The cylindrical titanium mesh cage for treatment of a long bone segmental defect: Description of a new technique and report of two cases. *J Orthop Trauma* 14:54-59, 2000.
60. Connolly, J.F. Injectable bone marrow preparations to stimulate osteogenic repair. *Clin Orthop Relat Res* 313:8-18, 1995.

61. Connolly, J.F.; Shindell, R. Percutaneous marrow injection for an ununited tibia. *Nebr Med J* 71:105–107, 1986.
62. Court-Brown, C.M.; Keating, J.F.; Christie, J.; et al. Exchange intramedullary nailing: Its use in aseptic tibial nonunion. *J Bone Joint Surg Br* 77:407–411, 1995.
63. Crockarell, J.R., Jr.; Berry, D.J.; Lewallen, D.G. Nonunion after periprosthetic femoral fracture associated with total hip arthroplasty. *J Bone Joint Surg Am* 81:1073–1079, 1999.
64. Crow, S.A.; Chen, L.; Lee, J.H.; et al. Vascularized bone grafting from the base of the second metacarpal for persistent distal radius nonunion: A case report. *J Orthop Trauma* 19:483–486, 2005.
65. Daftari, T.K.; Whitesides, T.E., Jr.; Heller, J.G.; et al. Nicotine on the revascularization of bone graft: An experimental study in rabbits. *Spine* 19:904–911, 1994.
66. Dalal, S.; Stanley, D. Locked intramedullary nailing in the treatment of olecranon nonunion: A new method of treatment. *J Shoulder Elbow Surg* 13:366–368, 2004.
67. Danckwardt-Lilliestrom, G. Reaming of the medullary cavity and its effect on diaphyseal bone: A fluorochromic, microangiographic and histologic study on the rabbit tibia and dog femur. *Acta Orthop Scand Suppl* 128:1–153, 1969.
68. Danis, R. *Theorie et Pratique de l'Osteosynthese*. Paris, Masson, 1949.
69. Danziger, M.B.; Healy, W.L. Operative treatment of olecranon nonunion. *J Orthop Trauma* 6:290–293, 1992.
70. Davey, P.A.; Simonis, R.B. Modification of the Nicoll bone-grafting technique for nonunion of the radius and/or ulna. *J Bone Joint Surg Br* 84:30–33, 2002.
71. Davids, P.H.; Luitse, J.S.; Strating, R.P.; et al. Operative treatment for delayed union and nonunion of midshaft clavicular fractures: AO reconstruction plate fixation and early mobilization. *J Trauma* 40:985–986, 1996.
72. Davila, J.; Malkani, A.; Paise, J.M. Supracondylar distal femoral nonunions treated with a megaprosthesis in elderly patients: A report of two cases. *J Orthop Trauma* 15:574–578, 2001.
73. Day, S.M.; DeHeer, D.H. Reversal of the detrimental effects of chronic protein malnutrition on long bone fracture healing. *J Orthop Trauma* 15:47–53, 2001.
74. Delloye, C.; Delefortrie, G.; Coutelier, L.; et al. Bone regenerate formation in cortical bone during distraction lengthening: An experimental study. *Clin Orthop Relat Res* 250:34–42, 1990.
75. Delloye, C.; Suratwala, S.J.; Cornu, O.; et al. Treatment of allograft nonunions with recombinant human bone morphogenetic proteins (rhBMP). *Acta Orthop Belg* 70:591–597, 2004.
76. de Vernejoul, M.C.; Bielakoff, J.; Herve, M.; et al. Evidence for defective osteoblastic function: A role for alcohol and tobacco consumption in osteoporosis in middle-aged men. *Clin Orthop Relat Res* 179:107–115, 1983.
77. Dimitriou, R.; Dahabreh, Z.; Katsoulis, E.; et al. Application of recombinant BMP-7 on persistent upper and lower limb non-unions. *Injury* 36(Suppl 4):S51–S59, 2005.
78. Dodds, R.A.; Catterall, A.; Bitensky, L.; et al. Abnormalities in fracture healing induced by vitamin B6 deficiency in rats. *Bone* 7:489–495, 1986.
79. Dworkin, S.F.; Von Korff, M.; LeResche, L. Multiple pains and psychiatric disturbance: An epidemiologic investigation. *Arch Gen Psychiatry* 47:239–244, 1990.
80. Ebraheim, N.A.; Mekhail, A.O.; Darwich, M. Open reduction and internal fixation with bone grafting of clavicular nonunion. *J Trauma* 42:701–704, 1997.
81. Eckardt, H.; Christensen, K.S.; Lind, M.; et al. Recombinant human bone morphogenetic protein 2 enhances bone healing in an experimental model of fractures at risk of non-union. *Injury* 36:489–494, 2005.
82. Eckardt, H.; Ding, M.; Lind, M.; et al. Recombinant human vascular endothelial growth factor enhances bone healing in an experimental nonunion model. *J Bone Joint Surg Br* 87:1434–1438, 2005.
83. Eggers, G.W.N. Internal contact splint. *J Bone Joint Surg Am* 31:40–52, 1949.
84. Eglseder, W.A., Jr.; Elliott, M.J. Nonunions of the distal radius. *Am J Orthop* 31:259–262, 2002.
85. Egol, K.A.; Kubiak, E.N.; Fulkerson, E.; et al. Biomechanics of locked plates and screws. *J Orthop Trauma* 18:488–493, 2004. [Au13]
86. Einhorn, T.A. Clinical applications of recombinant human BMPs: Early experience and future development. *J Bone Joint Surg Am* 85(Suppl 3):82–88, 2003.
87. Einhorn, T.A. Enhancement of fracture healing. *Instr Course Lect* 45:401–416, 1996.
88. Einhorn, T.A.; Bonnarens, F.; Burstein, A.H. The contributions of dietary protein and mineral to the healing of experimental fractures: A biomechanical study. *J Bone Joint Surg Am* 68:1389–1395, 1986.
89. Einhorn, T.A.; Gundberg, C.M.; Devlin, V.J.; et al. Fracture healing and osteocalcin metabolism in vitamin K deficiency. *Clin Orthop Relat Res* 237:219–225, 1988.
90. Einhorn, T.A.; Levine, B.; Michel, P. Nutrition and bone. *Orthop Clin North Am* 21:43–50, 1990.
91. Emami, A.; Mjoberg, B.; Larsson, S. Infected tibial nonunion: Good results after open cancellous bone grafting in 37 cases. *Acta Orthop Scand* 66:447–451, 1995.
92. Engesaeter, L.B.; Sudmann, B.; Sudmann, E. Fracture healing in rats inhibited by locally administered indomethacin. *Acta Orthop Scand* 63:330–333, 1992.
93. Esterhai, J.L., Jr.; Brighton, C.T.; Heppenstall, R.B. Nonunion of the humerus: Clinical, roentgenographic, scintigraphic, and response characteristics to

- treatment with constant direct current stimulation of osteogenesis. *Clin Orthop Relat Res* 211:228–234, 1986.
94. Esterhai, J.L., Jr., Brighton, C.T.; Heppenstall, R. B.; et al. Detection of synovial pseudarthrosis by ^{99m}Tc scintigraphy: Application to treatment of traumatic nonunion with constant direct current. *Clin Orthop Relat Res* 161:15–23, 1981.
 95. Esterhai, J.L., Jr., Sennett, B.; Gelb, H.; et al. Treatment of chronic osteomyelitis complicating nonunion and segmental defects of the tibia with open cancellous bone graft, posterolateral bone graft, and soft-tissue transfer. *J Trauma* 30:49–54, 1990.
 96. Fang, M.; Frost, P.; Iida-Klein, A.; et al. Effects of nicotine on cellular function in UMR 106-01 osteoblast-like cells. *Bone* 12:283–286, 1991.
 97. Feldman, D.S.; Shin, S.S.; Madan, S.; et al. Correction of tibial malunion and nonunion with six-axis analysis deformity correction using the Taylor Spatial Frame. *J Orthop Trauma* 17:549–554, 2003.
 98. Fernandez, D.L.; Ring, D.; Jupiter, J.B. Surgical management of delayed union and nonunion of distal radius fractures. *J Hand Surg [Am]* 26:201–209, 2001.
 99. Ferraz, I.C.; Papadimitriou, N.G.; Sotereanos, D.G. Scapular body nonunion: A case report. *J Shoulder Elbow Surg* 11:98–100, 2002.
 100. Finkemeier, C.G.; Chapman, M.W. Treatment of femoral diaphyseal nonunions. *Clin Orthop Relat Res* 398:223–234, 2002.
 101. Flinkkilä, T.; Ristiniemi, J.; Hämäläinen, M. Nonunion after intramedullary nailing of humeral shaft fractures. *J Trauma* 50:540–544, 2001.
 102. Foulk, D.A.; Szabo, R.M. Diaphyseal humerus fractures: Natural history and occurrence of nonunion. *Orthopedics* 18:333–335, 1995.
 103. Freedman, E.L.; Hak, D.J.; Johnson, E.E.; et al. Total knee replacement including a modular distal femoral component in elderly patients with acute fracture or nonunion. *J Orthop Trauma* 9:231–237, 1995.
 104. Frey, C.; Halikus, N.M.; Vu-Rose, T.; et al. A review of ankle arthrodesis: Predisposing factors to nonunion. *Foot Ankle Int* 15:581–584, 1994.
 105. Frich, L.H.; Sojbjerg, J.O.; Sneppen, O. Shoulder arthroplasty in complex acute and chronic proximal humeral fractures. *Orthopedics* 14:949–954, 1991.
 106. Friedlaender, G.E.; Perry, C.R.; Cole, J.D.; et al. Osteogenic protein-1 (bone morphogenetic protein-7) in the treatment of tibial nonunions. *J Bone Joint Surg Am* 83(Suppl 1):S151–S158, 2001.
 107. Galatz, L.M.; Williams, G.R., Jr.; Fenlin, J.M., Jr.; et al. Outcome of open reduction and internal fixation of surgical neck nonunions of the humerus. *J Orthop Trauma* 18:63–67, 2004.
 108. Gebauer, D.; Mayr, E.; Orthner, E.; et al. Low-intensity pulsed ultrasound: Effects on nonunions. *Ultrasound Med Biol* 31:1391–1402, 2005.
 109. Gerber, A.; Marti, R.; Jupiter, J. Surgical management of diaphyseal humeral nonunion after intramedullary nailing: Wave-plate fixation and autologous bone grafting without nail removal. *J Shoulder Elbow Surg* 12:309–313, 2003.
 110. Giannoudis, P.V.; MacDonald, D.A.; Matthews, S.J.; et al. Nonunion of the femoral diaphysis: The influence of reaming and non-steroidal anti-inflammatory drugs. *J Bone Joint Surg Br* 82:655–658, 2000.
 111. Goldman, B. Use and abuse of opioid analgesics in chronic pain. *Can Fam Physician* 39:571–576, 1993.
 112. Gonzalez del Pino, J.; Bartolome del Valle, E.; Grana, G.L.; et al. Free vascularized fibular grafts have a high union rate in atrophic nonunions. *Clin Orthop Relat Res* 419:38–45, 2004.
 113. Goulet, J.A.; Templeman, D. Delayed union and nonunion of tibial shaft fractures. *Instr Course Lect* 46:281–291, 1997.
 114. Graves, M.L.; Ryan, J.E.; Mast, J.W. Supracondylar femur nonunion associated with previous vascular repair: Importance of vascular exam in preoperative planning of nonunion repair. *J Orthop Trauma* 19:574–577, 2005.
 115. Green, S.A. The Ilizarov method. In Browner, B.D.; Levine, A.M.; Jupiter, J.B., eds. *Skeletal Trauma: Fractures, Dislocations, Ligamentous Injuries*, 2nd ed. Philadelphia, W.B. Saunders, 1998, pp. 661–701.
 116. Green, S.A. Skeletal defects: A comparison of bone grafting and bone transport for segmental skeletal defects. *Clin Orthop Relat Res* 301:111–117, 1994.
 117. Guarniero, R.; de Barros Filho, T.E.; Tannuri, U.; et al. Study of fracture healing in protein malnutrition. *Rev Paul Med* 110:63–68, 1992.
 118. Guerkov, H.H.; Lohmann, C.H.; Liu, Y.; et al. Pulsed electromagnetic fields increase growth factor release by nonunion cells. *Clin Orthop Relat Res* 384:265–279, 2001.
 119. Gustilo, R.B.; Nelson, G.E.; Hamel, A.; et al. The effect of intramedullary nailing on the blood supply of the diaphysis of long bones in mature dogs. *J Bone Joint Surg Am* 46:1362–1363, 1964.
 120. Gyl'nazarova, S.V.; Shtin, V.P. Reparative bone tissue regeneration in treating pseudarthroses with simultaneous lengthening in the area of the pathological focus (an experimental study). *Ortop Travmatol Protez* 4:10–15, 1983.
 121. Haidukewych, G.J. Innovations in locking plate technology. *J Am Acad Orthop Surg* 12:205–212, 2004.
 122. Hak, D.J.; Lee, S.S.; Goulet, J.A. Success of exchange reamed intramedullary nailing for femoral shaft nonunion or delayed union. *J Orthop Trauma* 14:178–182, 2000.
 123. Han, C.S.; Wood, M.B.; Bishop, A.T.; et al. Vascularized bone transfer. *J Bone Joint Surg Am* 74:1441–1449, 1992.
 124. Harley, B.J.; Beaupre, L.A.; Jones, C.A.; et al. The effect of time to definitive treatment on the rate of

Au14

- nonunion and infection in open fractures. *J Orthop Trauma* 16:484–490, 2002.
125. Haverstock, B.D.; Mandracchia, V.J. Cigarette smoking and bone healing: Implications in foot and ankle surgery. *J Foot Ankle Surg* 37:69–74, 1998.
 126. Healy, W.L.; Jupiter, J.B.; Kristiansen, T.K.; et al. Nonunion of the proximal humerus: A review of 25 cases. *J Orthop Trauma* 4:424–431, 1990.
 127. Helfet, D.L.; Jupiter, J.B.; Gasser, S. Indirect reduction and tension-band plating of tibial non-union with deformity. *J Bone Joint Surg Am* 74:1286–1297, 1992.
 128. Helfet, D.L.; Kloen, P.; Anand, N.; et al. Open reduction and internal fixation of delayed unions and nonunions of fractures of the distal part of the humerus. *J Bone Joint Surg Am* 85:33–40, 2003.
 129. Hernandez, R.J.; Tachdjian, M.O.; Poznanski, A.K.; et al. CT determination of femoral torsion. *Am J Roentgenol* 137:97–101, 1981.
 130. Hernigou, P.; Poignard, A.; Beaujean, F.; et al. Percutaneous autologous bone-marrow grafting for nonunions: Influence of the number and concentration of progenitor cells. *J Bone Joint Surg Am* 87:1430–1437, 2005.
 131. Hernigou, P.; Poignard, A.; Manicom, O.; et al. The use of percutaneous autologous bone marrow transplantation in nonunion and avascular necrosis of bone. *J Bone Joint Surg Br* 87:896–902, 2005.
 132. Herve, C.; Gaillard, M.; Andrivet, P.; et al. Treatment in serious lower limb injuries: Amputation versus preservation. *Injury* 18:21–23, 1987.
 133. Herzenberg, J.E.; Smith, J.D.; Paley, D. Correcting tibial deformities with Ilizarov's apparatus. *Clin Orthop Relat Res* 302:36–41, 1994.
 134. Hogevoid, H.E.; Groggaard, B.; Reikeras, O. Effects of short-term treatment with corticosteroids and indomethacin on bone healing: A mechanical study of osteotomies in rats. *Acta Orthop Scand* 63:607–611, 1992.
 135. Horstmann, H.; Mahboubi, S. The use of computed tomography scan in unstable hip reconstruction. *J Comput Tomogr* 11:364–369, 1987.
 136. Huddleston, P.M.; Steckelberg, J.M.; Hanssen, A.D.; et al. Ciprofloxacin inhibition of experimental fracture healing. *J Bone Joint Surg Am* 82:161–173, 2000.
 137. Huntington, T.W. Case of bone transference: Use of a segment of fibula to supply a defect in the tibia. *Ann Surg* 41:249–251, 1905.
 138. Huo, M.H.; Troiano, N.W.; Pelker, R.R.; et al. The influence of ibuprofen on fracture repair: Biomechanical, biochemical, histologic, and histomorphometric parameters in rats. *J Orthop Res* 9:383–390, 1991.
 139. Ikeda, K.; Tomita, K.; Hashimoto, F.; et al. Long-term follow-up of vascularized bone grafts for the reconstruction of tibial nonunion: Evaluation with computed tomographic scanning. *J Trauma* 32:693–697, 1992.
 140. Ilizarov, G.A. Clinical application of the tension-stress effect for limb lengthening. *Clin Orthop Relat Res* 250:8–26, 1990.
 141. Ilizarov, G.A. *Transosseous Osteosynthesis: Theoretical and Clinical Aspects of the Regeneration and Growth of Tissue*. Berlin, Springer-Verlag, 1992.
 142. Ilizarov, G.A.; Devyatov, A.A.; Kamerin, V.K. Plastic reconstruction of longitudinal bone defects by means of compression and subsequent distraction. *Acta Chir Plast* 22:32–41, 1980.
 143. Ilizarov, G.A.; Kaplunov, A.G.; Degtiarev, V.E.; et al. Treatment of pseudarthroses and ununited fractures, complicated by purulent infection, by the method of compression-distraction osteosynthesis. *Ortop Travmatol Protez* 33:10–14, 1972.
 144. Ilizarov, G.A.; Kaplunov, A.G.; Grachova, V.I.; et al. *Close Compression-Distraction Osteosynthesis of the Tibial Pseudoarthroses with Ilizarov Method (Metodicheskoe Posobie)*. Kurgan, USSR, Kniiekt Institute, 1971.
 145. Inan, M.; Karaoglu, S.; Cilli, F.; et al. Treatment of femoral nonunions by using cyclic compression and distraction. *Clin Orthop Relat Res* 436:222–228, 2005.
 146. Indrekvam, K.; Lekven, J.; Engesaeter, L.B.; et al. Effects of intramedullary reaming and nailing on blood flow in rat femora. *Acta Orthop Scand* 63:61–65, 1992.
 147. Jain, A.K.; Sinha, S. Infected nonunion of the long bones. *Clin Orthop Relat Res* 431:57–65, 2005.
 148. Johnson, E.E.; Simpson, L.A.; Helfet, D.L. Delayed intramedullary nailing after failed external fixation of the tibia. *Clin Orthop Relat Res* 253:251–257, 1990.
 149. Jones, N.F.; Swartz, W.M.; Mears, D.C.; et al. The “double barrel” free vascularized fibular bone graft. *Plast Reconstr Surg* 81:378–385, 1988.
 150. Judet, R. *La Decortication: Actualities de Chirurgie Orthopedique*. Paris, Masson, 1965.
 151. Judet, R.; Judet, J.; Roy-Camille, R. La vascularisation des pseudoarthroses des os longs d'après une étude clinique et expérimentale. *Rev Chir Orthop* 44:5, 1958.
 152. Jupiter, J.B.; Ring, D.; Rosen, H. The complications and difficulties of management of nonunion in the severely obese. *J Orthop Trauma* 9:363–370, 1995.
 153. Kabak, S.; Halici, M.; Tuncel, M.; et al. Treatment of midclavicular nonunion: Comparison of dynamic compression plating and low-contact dynamic compression plating techniques. *J Shoulder Elbow Surg* 13:396–403, 2004.
 154. Kassab, M.; Samaha, C.; Saillant, G. Ipsilateral fibular transposition in tibial nonunion using Huntington procedure: A 12-year follow-up study. *Injury* 34:770–775, 2003.
 155. Katon, W. The impact of major depression on chronic medical illness. *Gen Hosp Psychiatry* 18:215–219, 1996.
 156. Katon, W.; Sullivan, M.D. Depression and chronic medical illness. *J Clin Psychiatry* 51:3–11, 1990.

157. Keller, J.; Bungler, C.; Andereassen, T.T.; et al. Bone repair inhibited by indomethacin. *Acta Orthop Scand* 58:379–383, 1987.
158. Kempf, I.; Grosse, A.; Rigaut, P. The treatment of noninfected pseudarthrosis of the femur and tibia with locked intramedullary nailing. *Clin Orthop Relat Res* 212:142–154, 1986.
159. Kettunen, J.; Makela, E.A.; Turunen, V.; et al. Percutaneous bone grafting in the treatment of the delayed union and non-union of tibial fractures. *Injury* 33:239–245, 2002.
160. Key, J. Positive pressure in arthrodesis for tuberculosis of the knee joint. *South Med J* 25:909, 1932.
161. Khan, I.M. Fracture healing: Role of NSAIDs [abstract]. *Am J Orthop* 26:413, 1997.
162. Kim, S.J.; Yang, K.H.; Moon, S.H.; et al. Endoscopic bone graft for delayed union and nonunion. *Arthroscopy* 15:324–329, 1999.
163. Klassen, J.F.; Trousdale, R.T. Treatment of delayed and nonunion of the patella. *J Orthop Trauma* 11:188–194, 1997.
164. Klemm, K.W. Treatment of infected pseudarthrosis of the femur and tibia with an interlocking nail. *Clin Orthop Relat Res* 212:174–181, 1986.
165. Kloen, P. Bilateral clavicle non-unions treated with anteroinferior locking compression plating (LCP): A case report. *Acta Orthop Belg* 70:609–611, 2004.
166. Kocaoğlu, M.; Eralp, L.; Sen, C.; et al. Management of stiff hypertrophic nonunions by distraction osteogenesis: A report of 16 cases. *J Orthop Trauma* 17:543–548, 2003.
167. Koval, K.J.; Seligson, D.; Rosen, H.; et al. Distal femoral nonunion: Treatment with a retrograde inserted locked intramedullary nail. *J Orthop Trauma* 9:285–291, 1995.
168. Krettek, C.; Miclau, T.; Schandelmaier, P.; et al. The mechanical effect of blocking screws (Poller screws) in stabilizing tibia fractures with short proximal or distal fragments after insertion of small-diameter intramedullary nails. *J Orthop Trauma* 13:550–553, 1999.
169. Krettek, C.; Stephan, C.; Schandelmaier, P.; et al. The use of Poller screws as blocking screws in stabilizing tibial fractures treated with small diameter intramedullary nails. *J Bone Joint Surg Br* 81:963–968, 1999.
170. Krishnan, K.R.; France, R.D. Chronic pain and depression. *South Med J* 80:558–561, 1987.
171. Kyrö, A.; Usenius, J.P.; Aarnio, M.; et al. Are smokers a risk group for delayed healing of tibial shaft fractures? *Ann Chir Gynaecol* 82:254–262, 1993.
172. Lambotte, A. *L'Intervention Operatoire Dans les Fractures*. Paris, A. Maloine, 1907.
173. Lambotte, A. *Le Traitement des Fractures*. Paris, Masson, 1907.
174. Lammens, J.; Bauduin, G.; Driesen, R.; et al. Treatment of nonunion of the humerus using the Ilizarov external fixator. *Clin Orthop Relat Res* 353:223–230, 1998.
175. Lange, R.H. Limb reconstruction versus amputation decision making in massive lower extremity trauma. *Clin Orthop Relat Res* 243:92–99, 1989.
176. Lavini, F.; Renzi Brivio, L.; Pizzoli, A.; et al. Treatment of non-union of the humerus using the Orthofix external fixator. *Injury* 32(Suppl 4):SD35–SD40, 2001.
177. Lawlis, G.F.; McCoy, C.E. Psychological evaluation: Patients with chronic pain. *Orthop Clin North Am* 14:527–538, 1983.
178. LeCroy, C.M.; Rizzo, M.; Gunneson, E.E.; et al. Free vascularized fibular bone grafting in the management of femoral neck nonunion in patients younger than fifty years. *J Orthop Trauma* 16:464–472, 2002.
179. Lerner, R.K.; Esterhai, J.L., Jr.; Polomono, R.C.; et al. Psychosocial, functional, and quality of life assessment of patients with posttraumatic fracture nonunion, chronic refractory osteomyelitis, and lower extremity amputation. *Arch Phys Med Rehabil* 72:122–126, 1991.
180. Lerner, R.K.; Esterhai, J.L., Jr.; Polomano, R.C.; et al. Quality of life assessment of patients with posttraumatic fracture nonunion, chronic refractory osteomyelitis, and lower-extremity amputation. *Clin Orthop Relat Res* 295:28–36, 1993.
181. Lindholm, T.S.; Tornkvist, H. Inhibitory effect on bone formation and calcification exerted by the anti-inflammatory drug ibuprofen: An experimental study on adult rat with fracture. *Scand J Rheumatol* 10:38–42, 1981.
182. Mabry, T.M.; Prpa, B.; Haidukewych, G.J.; et al. Long-term results of total hip arthroplasty for femoral neck fracture nonunion. *J Bone Joint Surg Am* 86:2263–2267, 2004.
183. Mahaluxmivala, J.; Nadarajah, R.; Allen, P.W.; et al. Ilizarov external fixator: Acute shortening and lengthening versus bone transport in the management of tibial non-unions. *Injury* 36:662–668, 2005.
184. Mahboubi, S.; Horstmann, H. Femoral torsion: CT measurement. *Radiology* 160:843–844, 1986.
185. Marsh, J.L.; Prokuski, L.; Biermann, J.S. Chronic infected tibial nonunions with bone loss: Conventional techniques versus bone transport. *Clin Orthop Relat Res* 301:139–146, 1994.
186. Marti, R.K.; Verheyen, C.C.; Besselaar, P.P. Humeral shaft nonunion: Evaluation of uniform surgical repair in fifty-one patients. *J Orthop Trauma* 16:108–115, 2002.
187. Martinez, A.A.; Herrera, A.; Cuenca, J. Marchetti nailing of humeral shaft delayed unions. *Injury* 35:257–263, 2004.
188. Mathews, V.; Cabanela, M.E. Femoral neck non-union treatment. *Clin Orthop Relat Res* 419:57–64, 2004.
189. Maurer, D.J.; Merkow, R.L.; Gustilo, R.B. Infection after intramedullary nailing of severe open tibial fractures initially treated with external fixation. *J Bone Joint Surg Am* 71:835–838, 1989.

190. May, J.W., Jr.; Jupiter, J.B.; Weiland, A.J.; et al. Clinical classification of post-traumatic tibial osteomyelitis. *J Bone Joint Surg Am* 71:1422–1428, 1989.
191. Mayo, K.A.; Benirschke, S.K. Treatment of tibial malunions and nonunions with reamed intramedullary nails. *Orthop Clin North Am* 21:715–724, 1990.
192. McGraw, J.M.; Lim, E.V.A. Treatment of open tibial-shaft fractures: External fixation and secondary intramedullary nailing. *J Bone Joint Surg Am* 70:900–911, 1988.
193. McKee, M.; Jupiter, J.; Toh, C.L.; et al. Reconstruction after malunion and nonunion of intra-articular fractures of the distal humerus: Methods and results in 13 adults. *J Bone Joint Surg Br* 76:614–621, 1994.
194. McKee, M.D.; Miranda, M.A.; Riemer, B.L.; et al. Management of humeral nonunion after the failure of locking intramedullary nails. *J Orthop Trauma* 10:492–499, 1996.
195. McKee, M.D.; Wild, L.M.; Schemitsch, E.H.; et al. The use of an antibiotic-impregnated, osteoconductive, bioabsorbable bone substitute in the treatment of infected long bone defects: Early results of a prospective trial. *J Orthop Trauma* 16:622–627, 2002.
196. McLaren, A.C.; Blokker, C.P. Locked intramedullary fixation for metaphyseal malunion and nonunion. *Clin Orthop Relat Res* 265:253–260, 1991.
197. McMaster, P.E.; Hohl, M. Tibiofibular crosspeg grafting: A salvage procedure for complicated ununited tibial fractures. *J Bone Joint Surg Am* 57:720–721, 1975.
198. Megas, P.; Panagiotopoulos, E.; Skriviliotakis, S.; et al. Intramedullary nailing in the treatment of aseptic tibial nonunion. *Injury* 32:233–239, 2001.
199. Michael, D.; Fazal, M.A.; Cohen, B. Nonunion of a fracture of the body of the scapula: Case report and literature review. *J Shoulder Elbow Surg* 10:385–386, 2001.
200. Middleton, S.B.; Foley, S.J.; Foy, M.A. Partial excision of the clavicle for nonunion in National Hunt Jockeys. *J Bone Joint Surg Br* 77:778–780, 1995.
201. Milch, H. Synostosis operation for persistent nonunion of the tibia: A case report. *J Bone Joint Surg Am* 21:409–413, 1939.
202. Milch, H. Tibiofibular synostosis for non-union of the tibia. *Surgery* 27:770–779, 1950.
203. Moed, B.R.; Watson, J.T. Intramedullary nailing of aseptic tibial nonunions without the use of the fracture table. *J Orthop Trauma* 9:128–134, 1995.
204. More, R.C.; Kody, M.H.; Kabo, J.M.; et al. The effects of two nonsteroidal anti-inflammatory drugs on limb swelling, joint stiffness, and bone torsional strength following fracture in a rabbit model. *Clin Orthop Relat Res* 247:306–312, 1989.
205. Moroni, A.; Caja, V.L.; Maltarello, M.C.; et al. Biomechanical, scanning electron microscopy, and microhardness analyses of bone-pin interface in hydroxyapatite coated versus uncoated pins. *J Orthop Trauma* 11:154–161, 1997.
206. Morrey, B.F.; Adams, R.A. Semiconstrained elbow replacement for distal humeral nonunion. *J Bone Joint Surg Br* 77:67–72, 1995.
207. Müller, J.; Schenk, R.; Willenegger, H. Experimentelle untersuchungen über die entstehung reaktiver pseudoarthrosen am hunderadius. *Helv Chir Acta* 35:301–308, 1968.
208. Müller, M.E. Treatment of nonunions by compression. *Clin Orthop Relat Res* 43:83–92, 1965.
209. Müller, M.E.; Allgöwer, M.; Schneider, R. *Manual of Internal Fixation: Techniques Recommended by the AO Group*. Berlin, Springer-Verlag, 1979.
210. Müller, M.E.; Allgöwer, M.; Willenegger, H. *Technique of Internal Fixation of Fractures*. New York, Springer-Verlag, 1965.
211. Murray, J.H.; Fitch, R.D. Distraction histogenesis: Principles and indications. *J Am Acad Orthop Surg* 4:317–327, 1996.
212. Muschler, G.F.; Boehm, C.; Easley, K. Aspiration to obtain osteoblast progenitor cells from human bone marrow: The influence of aspiration volume. *J Bone Joint Surg Am* 79:1699–1709, 1997.
213. Nayak, N.K.; Schickendantz, M.S.; Regan, W.D.; et al. Operative treatment of nonunion of surgical neck fractures of the humerus. *Clin Orthop Relat Res* 313:200–205, 1995.
214. Nelson, F.R.; Brighton, C.T.; Ryaby, J.; et al. Use of physical forces in bone healing. *J Am Acad Orthop Surg* 11:344–354, 2003.
215. Nolte, P.A.; van der Krans, A.; Patka, P.; et al. Low-intensity pulsed ultrasound in the treatment of nonunions. *J Trauma* 51:693–702, 2001.
216. Oh, I.; Nahigian, S.H.; Rascher, J.J.; et al. Closed intramedullary nailing for ununited femoral shaft fractures. *Clin Orthop Relat Res* 106:206–215, 1975.
217. Olerud, S. The effects of intramedullary reaming. In Browner, B.D.; Edwards, C.C., eds. *The Science and Practice of Intramedullary Nailing*. Philadelphia, Lea & Febiger, 1987, pp. 61–66.
218. Olsen, B.S.; Vaesel, M.T.; Sojbjerg, J.O. Treatment of midshaft clavicular nonunion with plate fixation and autologous bone grafting. *J Shoulder Elbow Surg* 4:337–344, 1995.
219. Paley, D. *Principles of Deformity Correction*. Berlin, Springer-Verlag, 2002.
220. Paley, D. Treatment of tibial nonunion and bone loss with the Ilizarov technique. *Instr Course Lect* 39:185–197, 1990.
221. Paley, D.; Chaudray, M.; Pirone, A.M.; et al. Treatment of malunions and mal-nonunions of the femur and tibia by detailed preoperative planning and the Ilizarov techniques. *Orthop Clin North Am* 21:667–691, 1990.
222. Paley, D.; Tetsworth, K. Mechanical axis deviation of the lower limbs: Preoperative planning of multiapical frontal plane angular and bowing deformities of the femur and tibia. *Clin Orthop Relat Res* 280:65–71, 1992.

223. Paley, D.; Tetsworth, K. Mechanical axis deviation of the lower limbs: Preoperative planning of uniapical angular deformities of the tibia or femur. *Clin Orthop Relat Res* 280:48–64, 1992.
224. Paley, D.; Young, M.C.; Wiley, A.M.; et al. Percutaneous bone marrow grafting of fractures and bony defects: An experimental study in rabbits. *Clin Orthop Relat Res* 208:300–312, 1986.
225. Papagelopoulos, P.J.; Morrey, B.F. Treatment of nonunion of olecranon fractures. *J Bone Joint Surg Br* 76:627–635, 1994.
226. Papineau, L.J.; Alfageme, A.; Dalcourt, J.P.; et al. Osteomyelite chronique: Excision et greffe de spongieux à l'air libre après mises à plat extensives. *Int Orthop* 3:165–176, 1979.
227. Paramasivan, O.N.; Younge, D.A.; Pant, R. Treatment of nonunion around the olecranon fossa of the humerus by intramedullary locked nailing. *J Bone Joint Surg Br* 82:332–335, 2000.
228. Parvizi, J.; Vegari, D. Pulsed low-intensity ultrasound for fracture healing. *Foot Ankle Clin* 10:595–608, vii, 2005.
229. Patel, C.V.; Adenwalla, H.S. Treatment of fractured clavicle by immediate partial subperiosteal resection. *J Postgrad Med* 18:32–34, 1972.
230. Patel, V.R.; Menon, D.K.; Pool, R.D.; et al. Nonunion of the humerus after failure of surgical treatment: Management using the Ilizarov circular fixator. *J Bone Joint Surg Br* 82:977–983, 2000.
231. Paterson, D.C.; Lewis, G.N.; Cass, C.A. Treatment of delayed union and nonunion with an implanted direct current stimulator. *Clin Orthop Relat Res* 148:117–128, 1980.
232. Patzakis, M.J.; Scilaris, T.A.; Chon, J.; et al. Results of bone grafting for infected tibial nonunion. *Clin Orthop Relat Res* 315:192–198, 1995.
233. Patzakis, M.J.; Zalavras, C.G. Chronic posttraumatic osteomyelitis and infected nonunion of the tibia: Current management concepts. *J Am Acad Orthop Surg* 13:417–427, 2005.
234. Pauwels, F. Grundriss liner biomechanik der fracturheilung. In *Verh Dtsch Orthop Ges*, 34 Kongress, 1940, pp. 62–108.
235. Pauwels, F. Schenkelhalsbruch ein mechanisches Problem: Grundlagen des Heilungsvorganges, Prognose und kausale Therapie. Stuttgart, Germany, Ferdinand Enke Verlag, 1935.
236. Perlman, M.H.; Thordarson, D.B. Ankle fusion in a high risk population: An assessment of nonunion risk factors. *Foot Ankle Int* 20:491–496, 1999.
237. Perren, S.M.; Cordey, J. The concepts of interfragmentary strains. In Uthoff, H.K., ed. *Current Concepts of Internal Fixation of Fractures*. New York, Springer-Verlag, 1980.
238. Pers, M.; Medgyesi, S. Pedicle muscle flaps and their applications in the surgery repair. *Br J Plast Surg* 26:313–321, 1977.
239. Phemister, D.B. Treatment of ununited fractures by onlay bone grafts without screw or tie fixation and without breaking down of the fibrous union. *J Bone Joint Surg Am* 29:946–960, 1947.
240. Phieffer, L.S.; Goulet, J.A. Delayed unions of the tibia. *J Bone Joint Surg Am* 88:206–216, 2006.
241. Phillips, J.H.; Rahn, B.A. Fixation effects on membranous and endochondral onlay bone-graft resorption. *Plast Reconstr Surg* 82:872–877, 1988.
242. Pollak, D.; Floman, Y.; Simkin, A.; et al. The effect of protein malnutrition and nutritional support on the mechanical properties of fracture healing in the injured rat. *J Parenter Enteral Nutr* 10:564–567, 1986.
243. Polyzois, D.; Papachristou, G.; Kotsiopoulos, K.; et al. Treatment of tibial and femoral bone loss by distraction osteogenesis: Experience in 28 infected and 14 clean cases. *Acta Orthop Scand Suppl* 275:84–88, 1997.
244. Porter, S.E.; Hanley, E.N., Jr. The musculoskeletal effects of smoking. *J Am Acad Orthop Surg* 9:9–17, 2001.
245. Praemer, A.; Furner, S.; Rice, D.P. *Musculoskeletal Conditions in the United States*. Park Ridge, IL, American Academy of Orthopaedic Surgeons, 1992, pp. 83–124.
246. Pugh, D.M.; McKee, M.D. Advances in the management of humeral nonunion. *J Am Acad Orthop Surg* 11:48–59, 2003.
247. Raikin, S.M.; Landsman, J.C.; Alexander, V.A.; et al. Effect of nicotine on the rate and strength of long bone fracture healing. *Clin Orthop Relat Res* 353:231–237, 1998.
248. Ramp, W.; Lenz, L.; Galvin, R. Nicotine inhibits collagen synthesis and alkaline phosphatase activity, but stimulates DNA synthesis in osteoblast-like cells. *Exp Biol Med* 197:36–43, 1991.
249. Reed, A.A.; Joyner, C.J.; Brownlow, H.C.; et al. Human atrophic fracture non-unions are not avascular. *J Orthop Res* 20:593–599, 2002.
250. Reed, L.K.; Mormino, M.A. Functional outcome after blade plate reconstruction of distal tibia metaphyseal nonunions: A study of 11 cases. *J Orthop Trauma* 18:81–86, 2004.
251. Reichert, I.L.H.; McCarthy, I.D.; Hughes, S.P.F. The acute vascular response to intramedullary reaming: Microsphere estimation of blood flow in the intact ovine tibia. *J Bone Joint Surg Br* 77:490–493, 1995.
252. Rhinelander, F.W. The normal microcirculation of diaphyseal cortex and its response to fracture. *J Bone Joint Surg Am* 50:784–800, 1968.
253. Ricci, W.M.; Loftus, T.; Cox, C.; et al. Locked plates combined with minimally invasive insertion technique for the treatment of periprosthetic supracondylar femur fractures above a total knee arthroplasty. *J Orthop Trauma* 20:190–196, 2006.
254. Richards, M.; Huijbregtse, B.A.; Caplan, A.I.; et al. Marrow-derived progenitor cell injections enhance new bone formation during distraction. *J Orthop Res* 17:900–908, 1999.

Au17

255. Richmond, J.; Colleran, K.; Borens, O.; et al. Nonunions of the distal tibia treated by reamed intramedullary nailing. *J Orthop Trauma* 18:603–610, 2004.
256. Riebel, G.D.; Boden, S.D.; Whitesides, T.E.; et al. The effect of nicotine on incorporation of cancellous bone graft in an animal model. *Spine* 20:2198–2202, 1995.
257. Riemer, B.L.; Butterfield, S.L. Comparison of reamed and nonreamed solid core nailing of the tibial diaphysis after external fixation: A preliminary report. *J Orthop Trauma* 7:279–285, 1993.
258. Rijnberg, W.J.; van Linge, B. Central grafting for persistent nonunion of the tibia: A lateral approach to the tibia, creating a central compartment. *J Bone Joint Surg Br* 75:926–931, 1993.
259. Ring, D.; Allende, C.; Jafarnia, K.; et al. Ununited diaphyseal forearm fractures with segmental defects: Plate fixation and autogenous cancellous bone-grafting. *J Bone Joint Surg Am* 86:2440–2445, 2004.
260. Ring, D.; Gulotta, L.; Jupiter, J.B. Unstable nonunions of the distal part of the humerus. *J Bone Joint Surg Am* 85:1040–1046, 2003.
261. Ring, D.; Jupiter, J.B.; Gan, B.S.; et al. Infected nonunion of the tibia. *Clin Orthop Relat Res* 369:302–311, 1999.
262. Ring, D.; Jupiter, J.B.; Gulotta, L. Atrophic nonunions of the proximal ulna. *Clin Orthop Relat Res* 409:268–274, 2003.
263. Ring, D.; Kloen, P.; Kadzielski, J.; et al. Locking compression plates for osteoporotic nonunions of the diaphyseal humerus. *Clin Orthop Relat Res* 425:50–54, 2004.
264. Ring, D.; Psychoyios, V.N.; Chin, K.R.; et al. Nonunion of nonoperatively treated fractures of the radial head. *Clin Orthop Relat Res* 398:235–238, 2002.
265. Ro, J.; Sudmann, E.; Marton, P.F. Effect of indomethacin on fracture healing in rats. *Acta Orthop Scand* 47:588–599, 1976.
266. Rompe, J.D.; Rosendahl, T.; Schollner, C.; et al. High-energy extracorporeal shock wave treatment of nonunions. *Clin Orthop Relat Res* 387:102–111, 2001.
267. Rosen, H. Fracture healing and pseudarthrosis. In Taveras, J.M., ed. *Radiology: Diagnosis-Imaging-Intervention*. Philadelphia, J.B. Lippincott, 1986.
268. Rosen, H. Internal fixation of nonunions after previously unsuccessful electromagnetic stimulation. In Siegel, P.G., ed. *Techniques in Orthopedics: Topics in Orthopedic Trauma*. Baltimore, MD, University Park Press, 1984.
269. Rosen, H. (Late) reconstructive procedures about the ankle joint. In Jahss, M.H., ed. *Disorders of the Foot and Ankle: Medical and Surgical Management*. Philadelphia, W.B. Saunders, 1991.
270. Rosen, H. The management of nonunions and malunions in long bone fractures in the elderly. In Zuckerman, J.D., ed. *Comprehensive Care of Orthopedic Injuries in the Elderly*. Baltimore, MD, Urban and Schwarzenberg, 1990.
271. Rosen, H. Nonunion and malunion. In Browner, B.D.; Levine, A.M.; Jupiter, J.B., eds. *Skeletal Trauma: Fractures, Dislocations, Ligamentous Injuries*, 2nd ed. Philadelphia, W.B. Saunders, 1998, pp. 501–541.
272. Rosen, H. Operative treatment of nonunions of long bone fractures. *J Contin Educ Orthop* 7:13–39, 1979.
273. Rosen, H. Treatment of nonunions: General principles. In Chapman, M.W.; Madison, M., eds. *Operative Orthopaedics*. Philadelphia, J.B. Lippincott, 1988.
274. Rosen, H. The treatment of nonunions and pseudarthroses of the humeral shaft. *Orthop Clin North Am* 21:725–742, 1990.
275. Rosen, H.; Stempler, E.S. A simplified method of closed suction irrigation for treating orthopedic infections. *Orthopaedic Digest* 5:21, 1978.
276. Rosenberg, G.A.; Patterson, B.M. Limb salvage versus amputation for severe open fractures of the tibia. *Orthopedics* 21:343–349, 1998.
277. Rosson, J.W.; Simonis, R.B. Locked nailing for nonunion of the tibia. *J Bone Joint Surg Br* 74:358–361, 1992.
278. Rubin, C.; Bolander, M.; Ryaby, J.P.; et al. The use of low-intensity ultrasound to accelerate the healing of fractures. *J Bone Joint Surg Am* 83:259–270, 2001.
279. Safoury, Y. Use of a reversed-flow vascularized pedicle fibular graft for treatment of nonunion of the tibia. *J Reconstr Microsurg* 15:23–28, 1999.
280. Saleh, M.; Royston, S. Management of nonunion of fractures by distraction with correction of angulation and shortening. *J Bone Joint Surg Br* 78:105–109, 1996.
281. Salibian, A.H.; Anzel, S.H.; Salyer, W.A. Transfer of vascularized grafts of iliac bone to the extremities. *J Bone Joint Surg Am* 69:1319–1327, 1987.
282. Sammarco, V.J.; Chang, L. Modern issues in bone graft substitutes and advances in bone tissue technology. *Foot Ankle Clin* 7:19–41, 2002.
283. Sanders, R.A.; Sackett, J.R. Open reduction and internal fixation of delayed union and nonunion of the distal humerus. *J Orthop Trauma* 4:254–259, 1990.
284. Sarathy, M.P.; Madhavan, P.; Ravichandran, K.M. Nonunion of intertrochanteric fractures of the femur: Treatment by modified medial displacement and valgus osteotomy. *J Bone Joint Surg Br* 77:90–92, 1995.
285. Sarmiento, A.; Burkhalter, W.E.; Latta, L.L. Functional bracing in the treatment of delayed union and nonunion of the tibia. *Int Orthop* 27:26–29, 2003.
286. Savage, S.R. Opioid use in the management of chronic pain. *Med Clin North Am* 83:761–786, 1999.
287. Sawaizumi, T.; Nanno, M.; Nanbu, A.; et al. Vascularised bone graft from the base of the second metacarpal for refractory nonunion of the scaphoid. *J Bone Joint Surg Br* 86:1007–1012, 2004.

288. Sawant, M.R.; Bendall, S.P.; Kavanagh, T.G.; et al. Nonunion of tibial stress fractures in patients with deformed arthritic knees: Treatment using modular total knee arthroplasty. *J Bone Joint Surg Br* 81:663–666, 1999.
289. Schaden, W.; Fischer, A.; Sailler, A. Extracorporeal shock wave therapy of nonunion or delayed osseous union. *Clin Orthop Relat Res* 387:90–94, 2001.
290. Schenk, R.K. Histology of fracture repair and nonunion. *Bulletin of the Swiss Association for Study of Internal Fixation*. Bern, Switzerland, Swiss Association for Study of Internal Fixation, 1978.
291. Schenk, R.; Willenegger, H. Zur Histologie der primären Knochenheilung: Modifikationen und grenzen der Spalthheilung in Abhängigkeit von der Defektgrösse. *Unfallheilkunde* 81:219–227, 1977.
292. Schleberger, R.; Sengem, T. Non-invasive treatment of long-bone pseudarthrosis by shock waves (ESWL). *Arch Orthop Trauma Surg* 111:224–227, 1992.
293. Schmitz, M.A.; Finnegan, M.; Natarajan, R.; et al. Effect of smoking on tibial shaft fracture healing. *Clin Orthop Relat Res* 365:184–200, 1999.
294. Schwartzman, V.; Choi, S.H.; Schwartzman, R. Tibial nonunions: Treatment tactics with the Ilizarov method. *Orthop Clin North Am* 21:639–653, 1990.
295. Seitz, W.H., Jr.; Froimson, A.I.; Leb, R.B. Autogenous bone marrow and allograft replacement of bone defects in the hand and upper extremities. *J Orthop Trauma* 6:36–42, 1992.
296. Shahcheraghi, G.H.; Bayatpoor, A. Infected tibial nonunion. *Can J Surg* 37:209–213, 1994.
297. Shapiro, M.S.; Endrizzi, D.P.; Cannon, R.M.; et al. Treatment of tibial defects and nonunions using ipsilateral vascularized fibular transposition. *Clin Orthop Relat Res* 296:207–212, 1993.
298. Silcox, D.H.III; Daftari, T.; Boden, S.D.; et al. The effect of nicotine on spinal fusion. *Spine* 20:1549–1553, 1995.
299. Simonis, R.B.; Nunez, V.A.; Khaleel, A. Use of the Coventry infant hip screw in the treatment of nonunion of fractures of the distal humerus. *J Bone Joint Surg Br* 85:74–77, 2003.
300. Simonis, R.B.; Parnell, E.J.; Ray, P.S.; et al. Electrical treatment of tibial non-union: A prospective, randomised, double-blind trial. *Injury* 34:357–362, 2003.
301. Sitter, T.; Wilson, J.; Browner, B. The effect of reamed versus unreamed nailing on intramedullary blood supply and cortical viability [abstract]. *J Orthop Trauma* 4:232, 1990.
302. Sledge, S.L.; Johnson, K.D.; Henley, M.B.; et al. Intramedullary nailing with reaming to treat nonunion of the tibia. *J Bone Joint Surg Am* 71:1004–1019, 1989.
303. Smith, T.K. Prevention of complications in orthopedic surgery secondary to nutritional depletion. *Clin Orthop Relat Res* 222:91–97, 1987.
304. Song, H.R.; Cho, S.H.; Koo, K.H.; et al. Tibial bone defects treated by internal bone transport using the Ilizarov method. *Int Orthop* 22:293–297, 1998.
305. Sudmann, E.; Dregelid, E.; Bessesen, A.; et al. Inhibition of fracture healing by indomethacin in rats. *Eur J Clin Invest* 9:333–339, 1979.
306. Swartz, W.M.; Mears, D.C. Management of difficult lower extremity fractures and nonunions. *Clin Plast Surg* 13:633–644, 1986.
307. Taylor, J.C. Delayed union and nonunion of fractures. In Crenshaw, A.H., ed. *Campbell's Operative Orthopaedics*, 8th ed. St. Louis, MO, Mosby, 1992, pp. 1287–1345.
308. Templeman, D.; Thomas, M.; Varecka, T.; et al. Exchange reamed intramedullary nailing for delayed union and nonunion of the tibia. *Clin Orthop Relat Res* 315:169–175, 1995.
309. Tennant, F.S., Jr.; Rawson, R.A. Outpatient treatment of prescription opioid dependence: Comparison of two methods. *Arch Intern Med* 142:1845–1847, 1982.
310. te Velde, E.A.; van der Werken, C. Plate osteosynthesis for pseudarthrosis of the humeral shaft. *Injury* 32:621–624, 2001.
311. Tiedeman, J.J.; Connolly, J.F.; Strates, B.S.; et al. Treatment of nonunion by percutaneous injection of bone marrow and demineralized bone matrix: An experimental study in dogs. *Clin Orthop Relat Res* 268:294–302, 1991.
312. Tien, Y.C.; Chen, J.C.; Fu, Y.C.; et al. Supracondylar dome osteotomy for cubitus valgus deformity associated with a lateral condylar nonunion in children. *J Bone Joint Surg Am* 87:1456–1463, 2005.
313. Tuli, S.M. Tibialization of the fibula: A viable option to salvage limbs with extensive scarring and gap nonunions of the tibia. *Clin Orthop Relat Res* 431:80–84, 2005.
314. Ueng, S.W.; Chao, E.K.; Lee, S.S.; et al. Augmentative plate fixation for the management of femoral nonunion after intramedullary nailing. *J Trauma* 43:640–644, 1997.
315. Ueng, S.W.; Lee, M.Y.; Li, A.F.; et al. Effect of intermittent cigarette smoke inhalation on tibial lengthening: Experimental study on rabbits. *J Trauma* 42:231–238, 1997.
316. Ueng, S.W.; Lee, S.S.; Lin, S.S.; et al. Hyperbaric oxygen therapy mitigates the adverse effect of cigarette smoking on the bone healing of tibial lengthening: An experimental study on rabbits. *J Trauma* 47:752–759, 1999.
317. Ueng, S.W.; Shih, C.H. Augmentative plate fixation for the management of femoral nonunion with broken interlocking nail. *J Trauma* 45:747–752, 1998.
318. Ueng, S.W.; Wei, F.C.; Shih, C.H. Management of femoral diaphyseal infected nonunion with antibiotic beads local therapy, external skeletal fixation, and staged bone grafting. *J Trauma* 46:97–103, 1999.
319. Valchanou, V.D.; Michailov, P. High energy shock waves in the treatment of delay and nonunion of fractures. *Int Orthop* 15:181–184, 1991.

320. Van Houwelingen, A.P.; McKee, M.D. Treatment of osteopenic humeral shaft nonunion with compression plating, humeral cortical allograft struts, and bone grafting. *J Orthop Trauma* 19:36-42, 2005.
321. Walsh, E.F.; DiGiovanni, C. Fibular nonunion after closed rotational ankle fracture. *Foot Ankle Int* 25:488-495, 2004.
322. Wang, C.J.; Chen, H.S.; Chen, C.E.; et al. Treatment of nonunions of long bone fractures with shock waves. *Clin Orthop Relat Res* 387:95-101, 2001.
323. Wang, J.W.; Weng, L.H. Treatment of distal femoral nonunion with internal fixation, cortical allograft struts, and autogenous bone-grafting. *J Bone Joint Surg Am* 85:436-440, 2003.
324. Ward, W.G.; Goldner, R.D.; Nunley, J.A. Reconstruction of tibial bone defects in tibial nonunion. *Microsurgery* 11:63-73, 1990.
325. Warren, S.B.; Brooker, A.F., Jr. Intramedullary nailing of tibial nonunions. *Clin Orthop Relat Res* 285:236-243, 1992.
326. Webb, L.X.; Winquist, R.A.; Hansen, S.T. Intramedullary nailing and reaming for delayed union or nonunion of the femoral shaft: A report of 105 consecutive cases. *Clin Orthop Relat Res* 212:133-141, 1986.
327. Weber, B.G. Lengthening osteotomy of the fibula to correct a widened mortice of the ankle after fracture. *Int Orthop* 4:289-293, 1981.
328. Weber, B.G.; Brunner, C. The treatment of nonunions without electrical stimulation. *Clin Orthop Relat Res* 161:24-32, 1981.
329. Weber, B.G.; Cech, O. Pseudarthrosis. Bern, Switzerland, Hans Huber, 1976.
330. Weiland, A.J. Current concepts review: Vascularized free bone transplants. *J Bone Joint Surg Am* 63:166-169, 1981.
331. Weiland, A.J.; Daniel, R.K. Microvascular anastomoses for bone grafts in the treatment of massive defects in bone. *J Bone Joint Surg Am* 61:98-104, 1979.
332. Weiland, A.J.; Moore, J.R.; Daniel, R.K. Vascularized bone autografts: Experience with 41 cases. *Clin Orthop Relat Res* 174:87-95, 1983.
333. Weinberg, H.; Roth, V.G.; Robin, G.C.; et al. Early fibular bypass procedures (tibiofibular synostosis) for massive bone loss in war injuries. *J Trauma* 19:177-181, 1979.
334. Wenzl, M.E.; Porte, T.; Fuchs, S.; et al. Delayed and non-union of the humeral diaphysis: Compression plate or internal plate fixator? *Injury* 35:55-60, 2004.
335. Weresh, M.J.; Hakanson, R.; Stover, M.D.; et al. Failure of exchange reamed intramedullary nails for ununited femoral shaft fractures. *J Orthop Trauma* 14:335-338, 2000.
336. Wilkes, R.A.; Thomas, W.G.; Ruddle, A. Fracture and nonunion of the proximal tibia below an osteoarthritic knee: Treatment by long-stemmed total knee replacement. *J Trauma* 36:356-357, 1994.
337. Wing, K.J.; Fisher, C.G.; O'Connell, J.X.; et al. Stopping nicotine exposure before surgery: The effect on spinal fusion in a rabbit model. *Spine* 25:30-34, 2000.
338. Wiss, D.A.; Stetson, W.B. Nonunion of the tibia treated with a reamed intramedullary nail. *J Orthop Trauma* 8:189-194, 1994.
339. Wolff, A.M.; Krackow, K.A. The treatment of nonunion of proximal tibial osteotomy with internal fixation. *Clin Orthop Relat Res* 250:207-215, 1990.
340. Wood, M.B.; Cooney, W.P.III Vascularized bone segment transfers for management of chronic osteomyelitis. *Orthop Clin North Am* 15:461-472, 1984.
341. Wu, C.C. The effect of dynamization on slowing the healing of femur shaft fractures after interlocking nailing. *J Trauma* 43:263-267, 1997.
342. Wu, C.C. Humeral shaft nonunion treated by a Seidel interlocking nail with a supplementary staple. *Clin Orthop Relat Res* 326:203-208, 1996.
343. Wu, C.C.; Shih, C.H. Distal femoral nonunion treated with interlocking nailing. *J Trauma* 31:1659-1662, 1991.
344. Wu, C.C.; Shih, C.H. Treatment of 84 cases of femoral nonunion. *Acta Orthop Scand* 63:57-60, 1992.
345. Wu, C.C.; Shih, C.H. Treatment for nonunion of the shaft of the humerus: Comparison of plates and Seidel interlocking nails. *Can J Surg* 35:661-665, 1992.
346. Wu, C.C.; Shih, C.H.; Chen, W.J. Nonunion and shortening after femoral fracture treated with one-stage lengthening using locked nailing technique: Good results in 48/51 patients. *Acta Orthop Scand* 70:33-36, 1999.
347. Wu, C.C.; Shih, C.H.; Chen, W.J.; et al. High success rate with exchange nailing to treat a tibial shaft aseptic nonunion. *J Orthop Trauma* 13:33-38, 1999.
348. Wu, C.C.; Shih, C.H.; Chen, W.J.; et al. Treatment of clavicular aseptic nonunion: Comparison of plating and intramedullary nailing techniques. *J Trauma* 45:512-516, 1998.
349. Yajima, H.; Tamai, S.; Mizumoto, S.; et al. Vascularized fibular grafts in the treatment of osteomyelitis and infected nonunion. *Clin Orthop Relat Res* 293:256-264, 1993.

Author Query Form

Book: Skeletal Trauma, 4/E Chapter No:10022
--

Query Refs.	Details Required	Author's response
AU1	OK as edited?	
AU2	OK as edited? (needs to be parallel to the other two)	
AU3	normal-population angle?	
AU4	the local what?	
AU5	should this read four increments or one increment, respectively?	
AU6	three or two?	
AU7	Note: cc changed to mL throughout	
AU8	I don't think there is a ch called Enhancement of skeletal repair.	
AU1	OK as edited?	
AU2	OK as edited? (needs to be parallel to the other two)	
AU3	normal-population angle?	
AU4	the local what?	
AU5	should this read four increments or one increment, respectively?	
AU6	three or two?	
AU7	Note: cc changed to mL throughout	
AU8	I don't think there is a ch called Enhancement of skeletal repair.	
AU9	OK as edited?	
AU10	Figs 71 and 72 were switched so that they are called out in order. Pls. check.	
AU11	OK to add Fig 83 in here? If not, please insert a callout to Fig 83 somewhere in this paragraph.	
AU12	Ok as edited?	
AU13	Reference not cited in text. Please check.	
AU14	Reference not cited in text. Please check.	
AU15	Reference not cited in text. Please check.	
AU16	Reference not cited in text. Please check.	
AU17	Reference not cited in text. Please check.	
AU18	Reference not cited in text. Please check.	